

**8vo Congreso Argentino de  
Neumonología Pediátrica  
SOCIEDAD ARGENTINA de PEDIATRIA**

**Bronquiectasias No FQ  
Lo que necesito saber en imágenes  
del torax**

**Dr. Hugo Robledo  
Córdoba - Argentina**

# Bronquiectasias No FQ

## Herramientas y Técnicas de diagnóstico

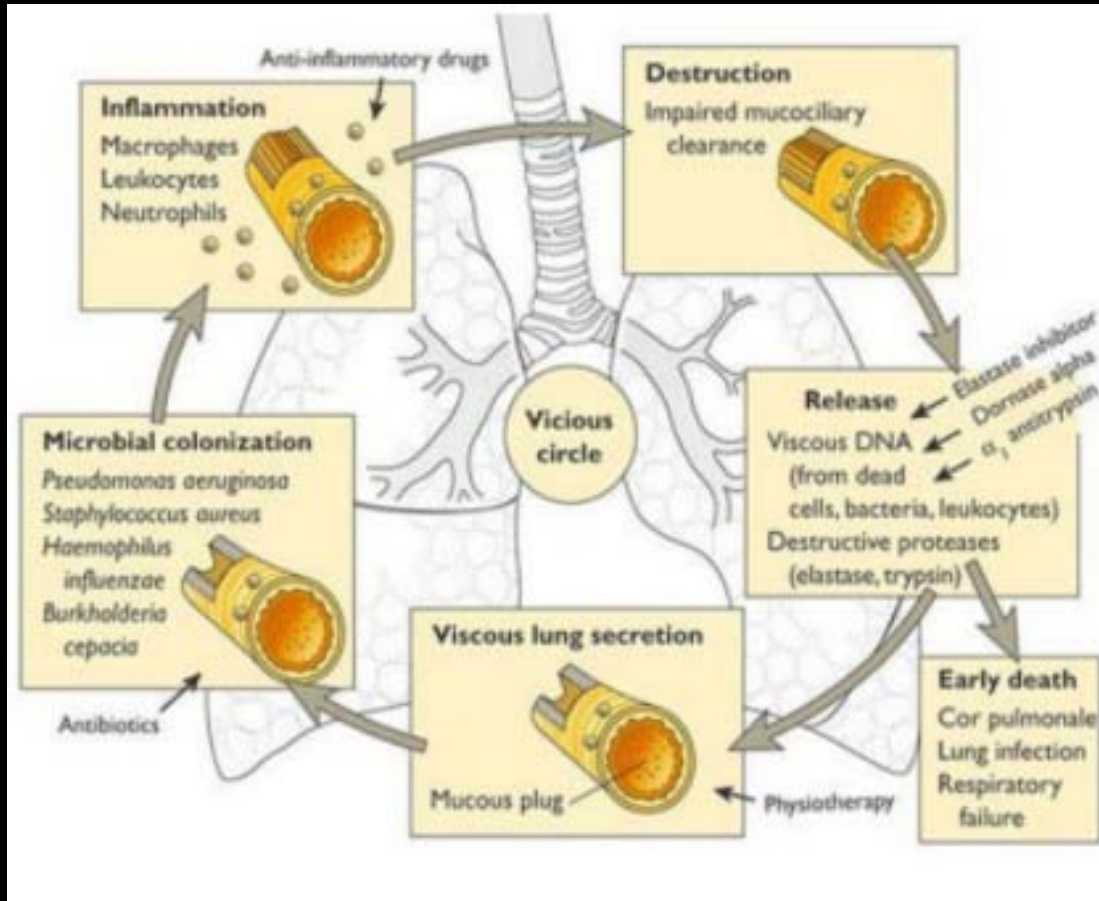
Tips

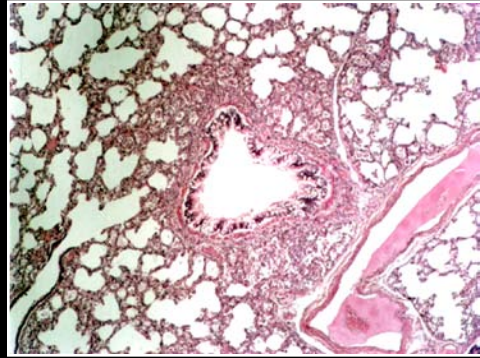
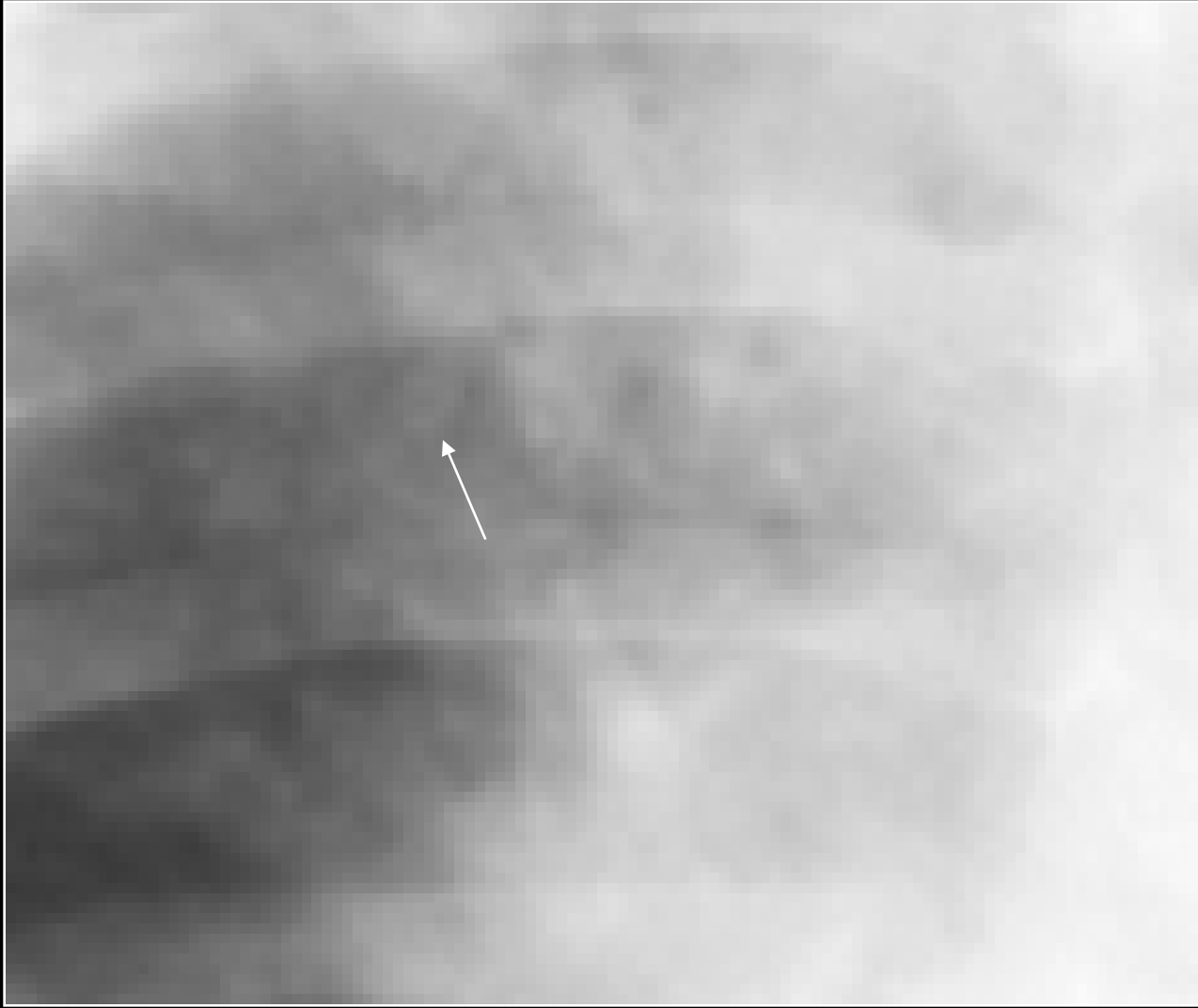


**RX** 1er step menos sensible

**TAC** mas sensible Sirve para clasificación  
distribución aproximación diagnostica

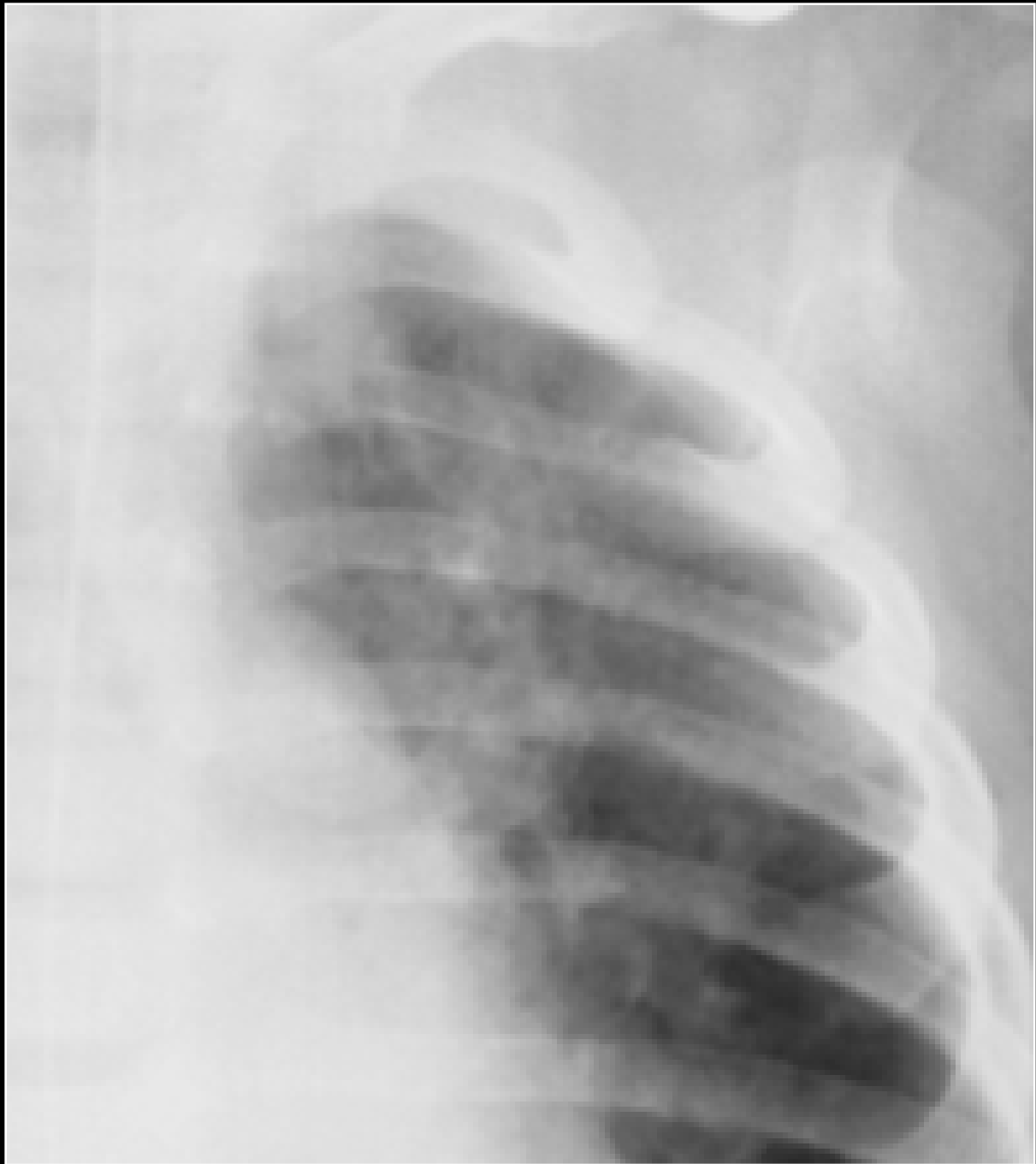Técnica : AR Minip MIP Dinámica MPR  
Volumetría Endoscopia virtual

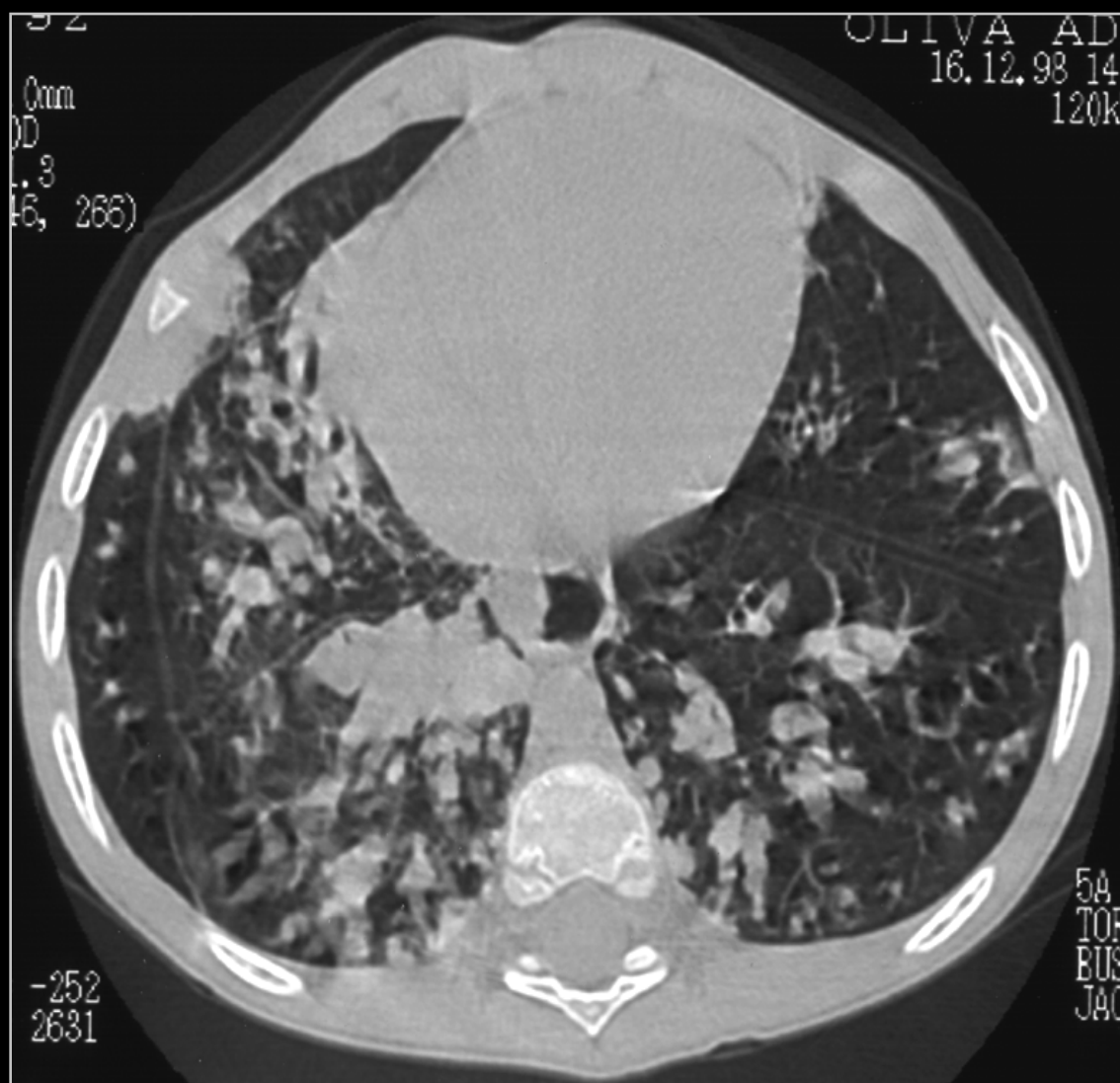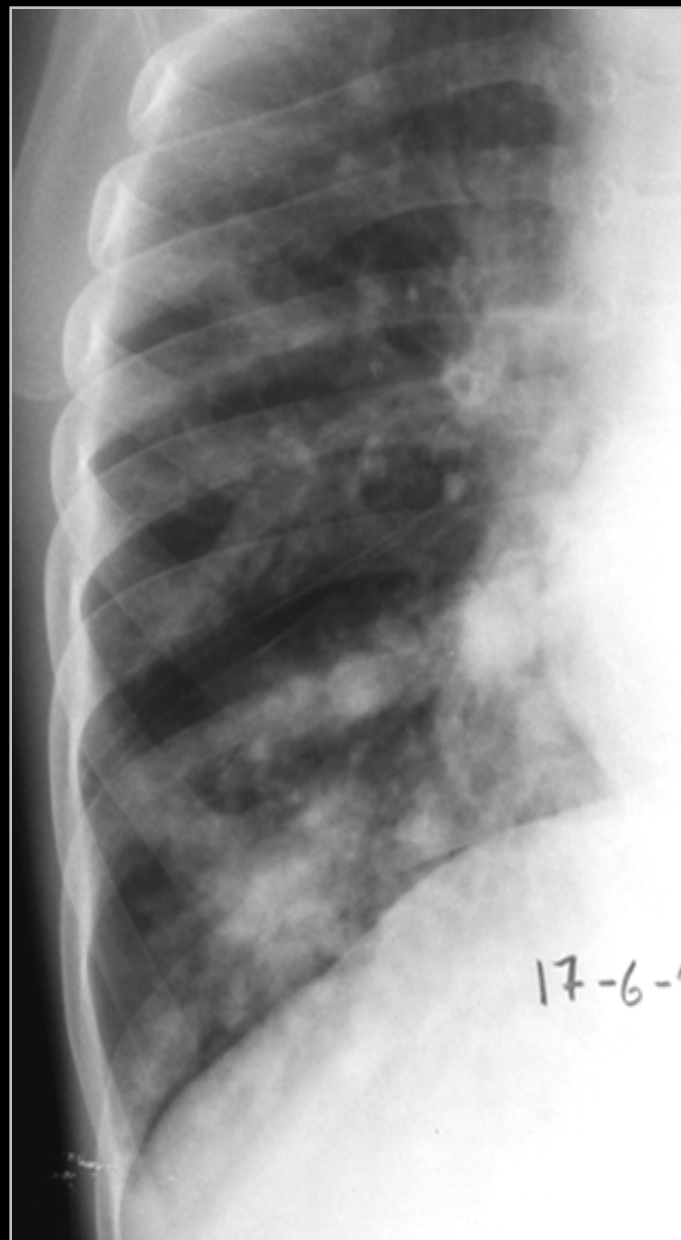# Mecanismo











# Bronquiectasias

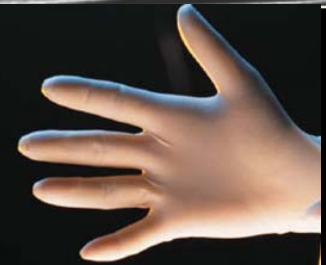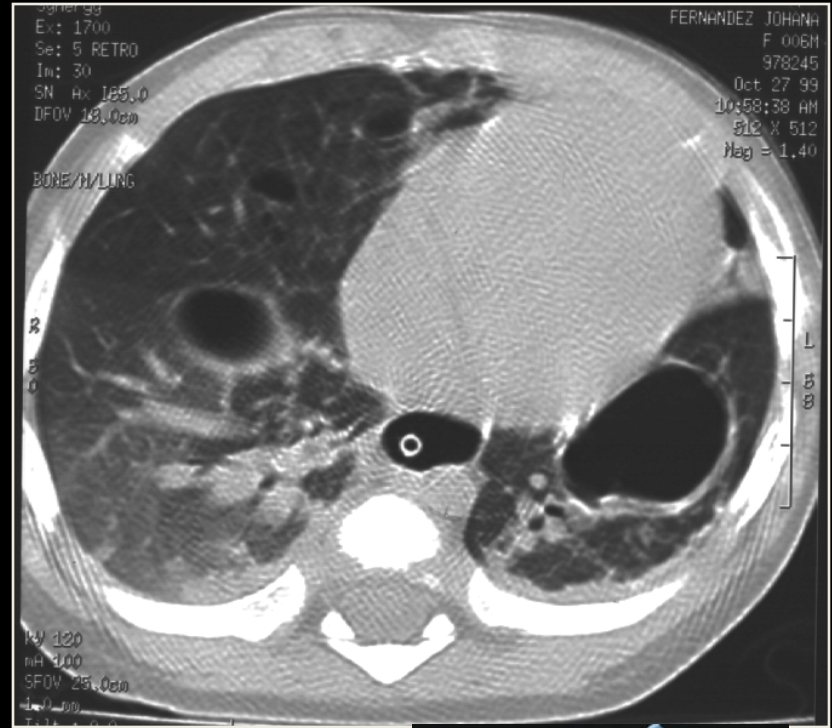
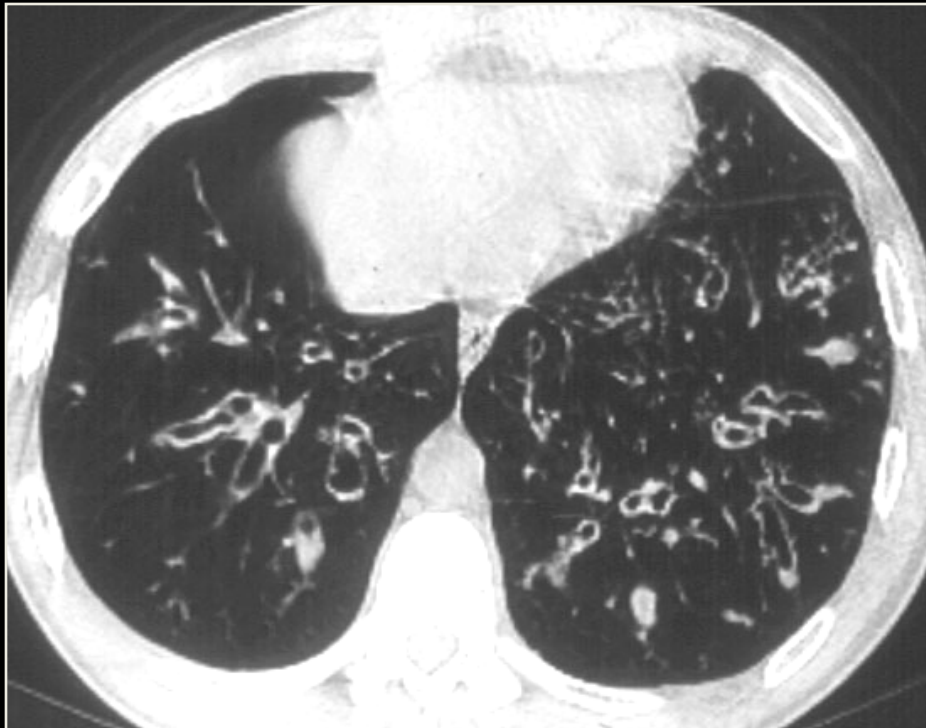
- Engrosamiento de paredes bronquiales
- Falta de reducción de calibre bronquial progresivo hacia la periferia (vía de tren)
- Alteración de la relación normal bronquio - arteria (anillo de sello) del 1:1 a 0.74-1 (The image definition of bronchiectasis in Children Ped Pulmonol 2018;53 6-7)
- Etapas iniciales de afectación bronquial (árbol en brote - patron en mosaico)
- Hallazgos asociados – Clasificación - Distribución

# Bronquiectasias Diferencias Adultos Niños

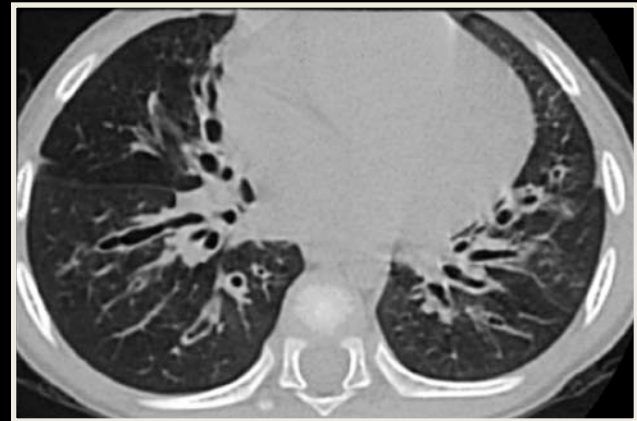
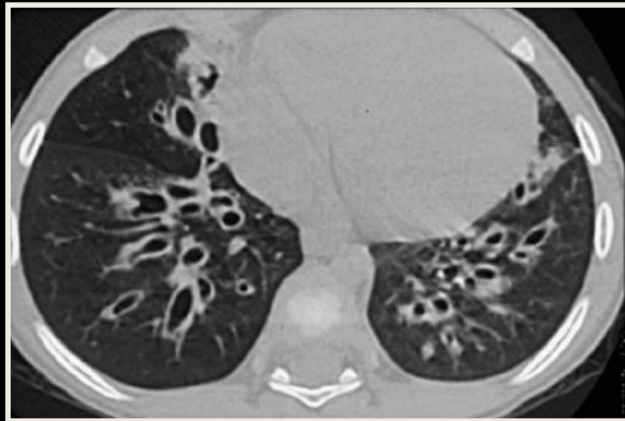
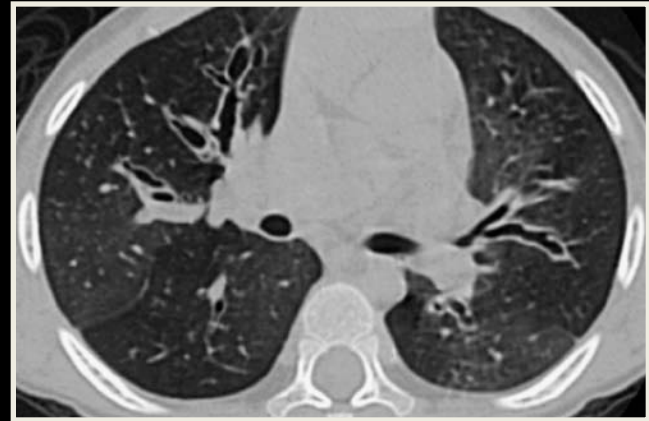
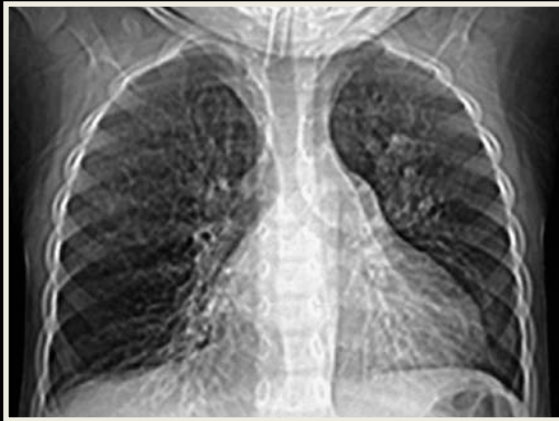- Tamaño de vía aérea
- (Bronchoarterial ratio on HRCT scan of the chest in children need to redefine bronchial dilatation Chest 2011 Jun 139 ; 6 1445-1450)
- Reversibilidad  
(Reversible bronchial dilatation in children: comparison of serial high-resolution computer tomography scans of the lungs. Eur J Radiol 2003 Sep;47(3):215-20.)

# Bronquiectasias

Cilíndricas Varicosas Saculares Tapones Mucosos

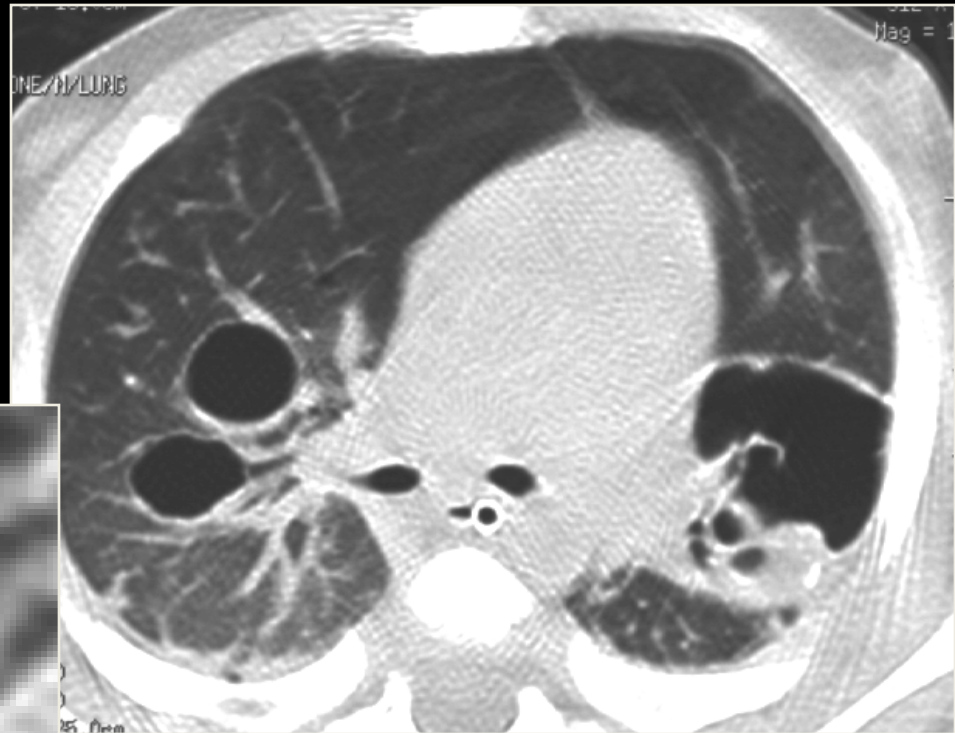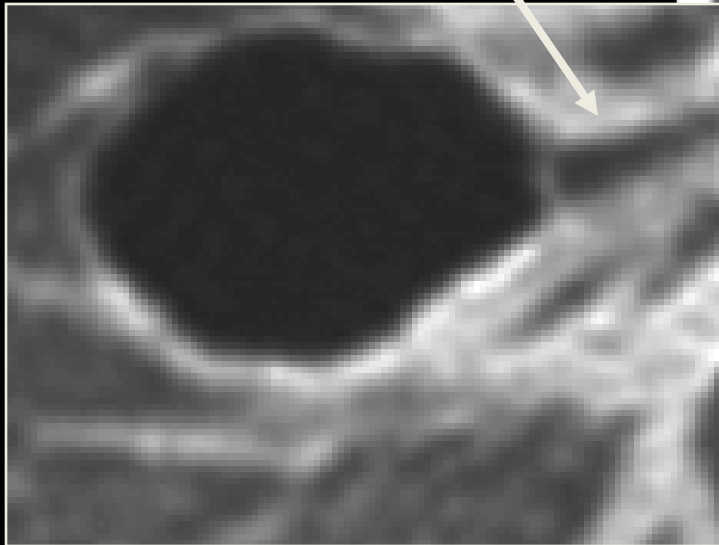



# Bronquiectasias



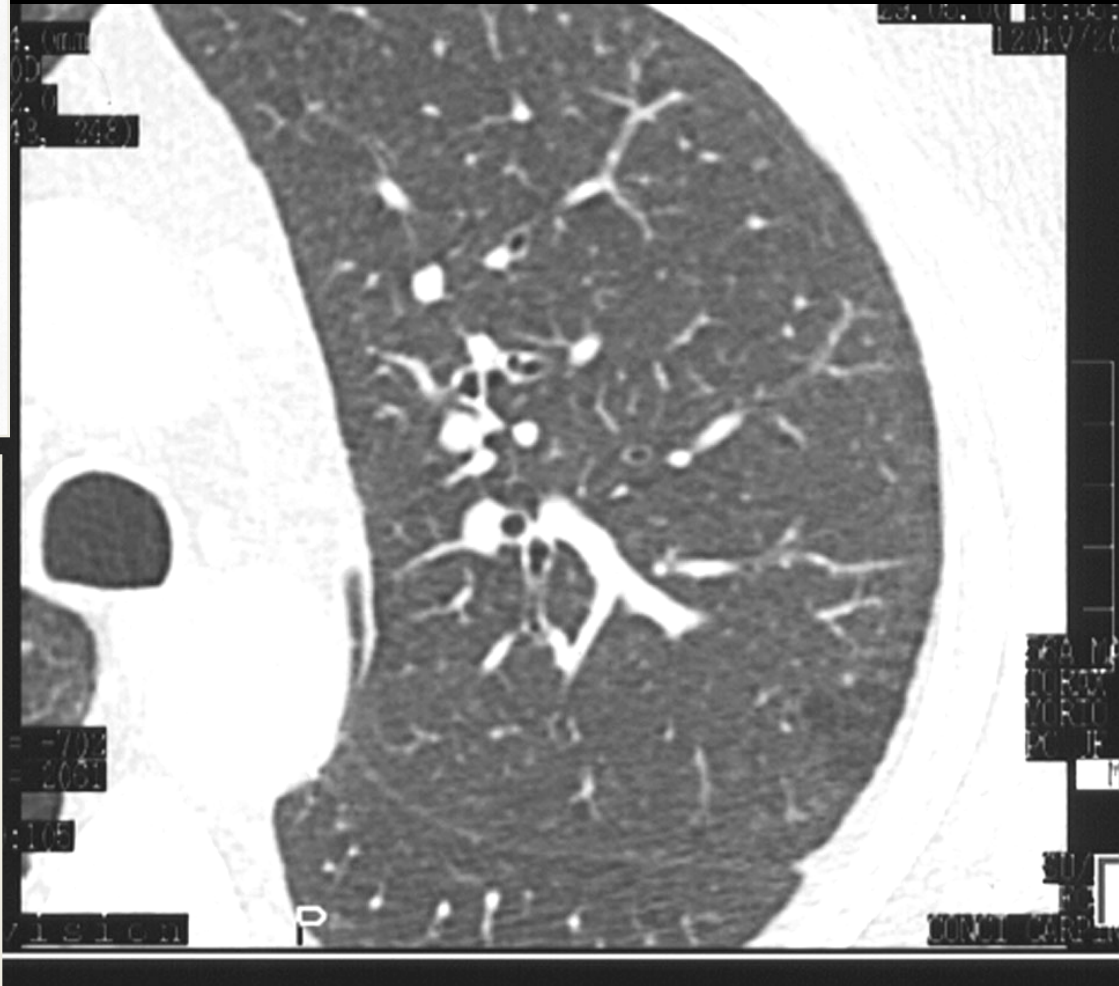
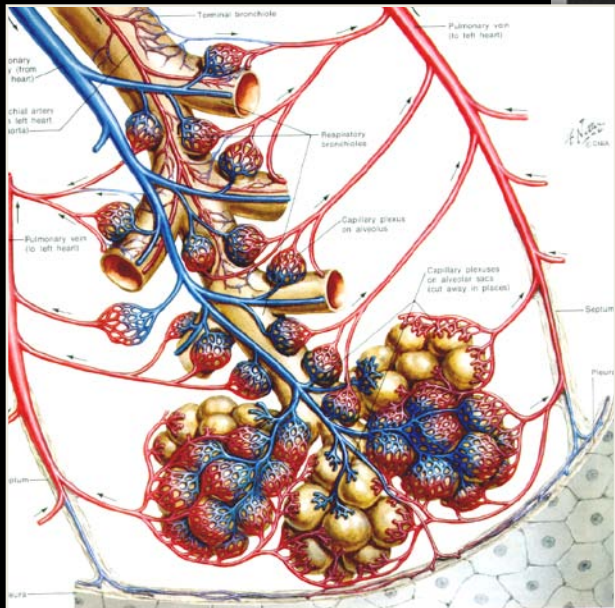
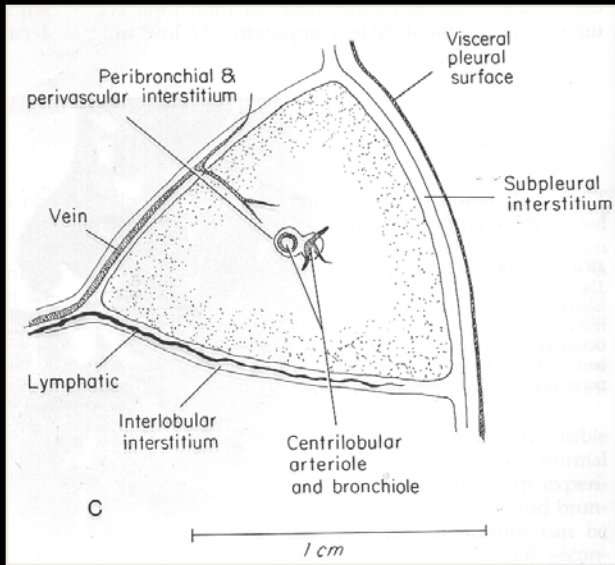
# Bronquiectasias Quísticas

BRONQUIO





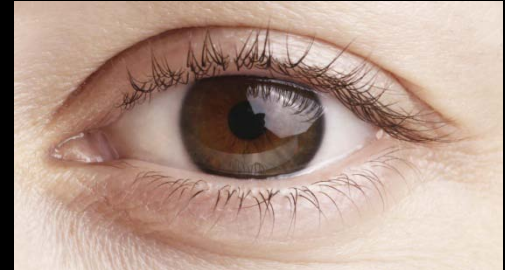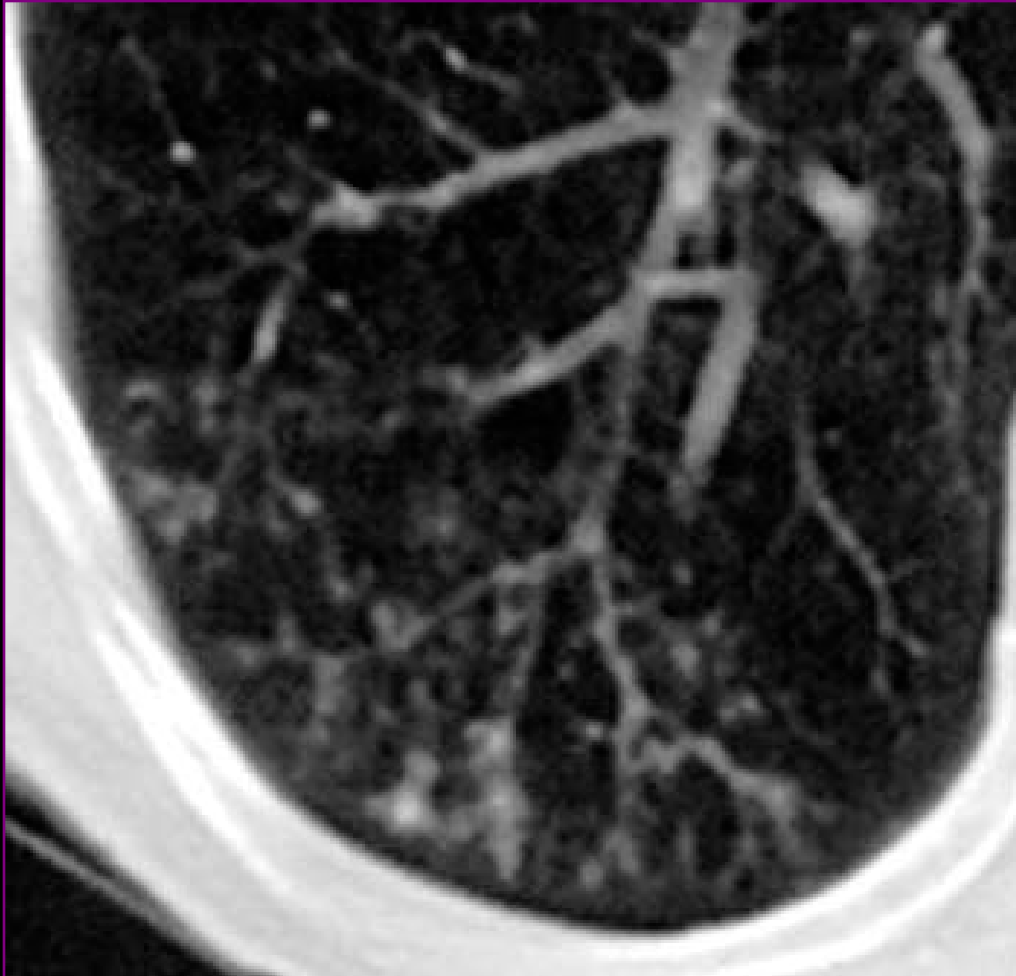
# Lobulillo Pulmonar Secundario

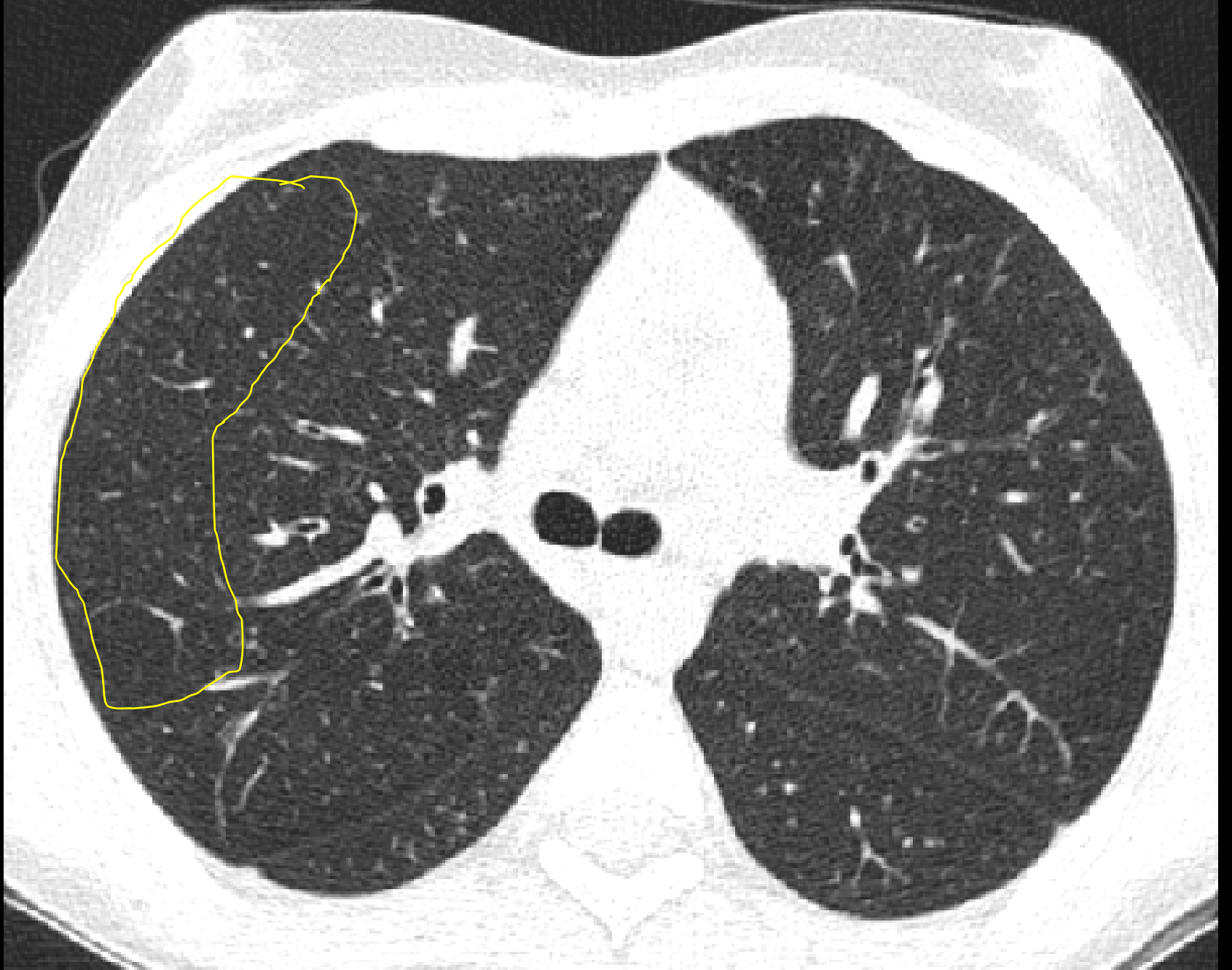


TAC de ALTA RESOLUCIÓN: 1mm Espesor, Filtro, mAs

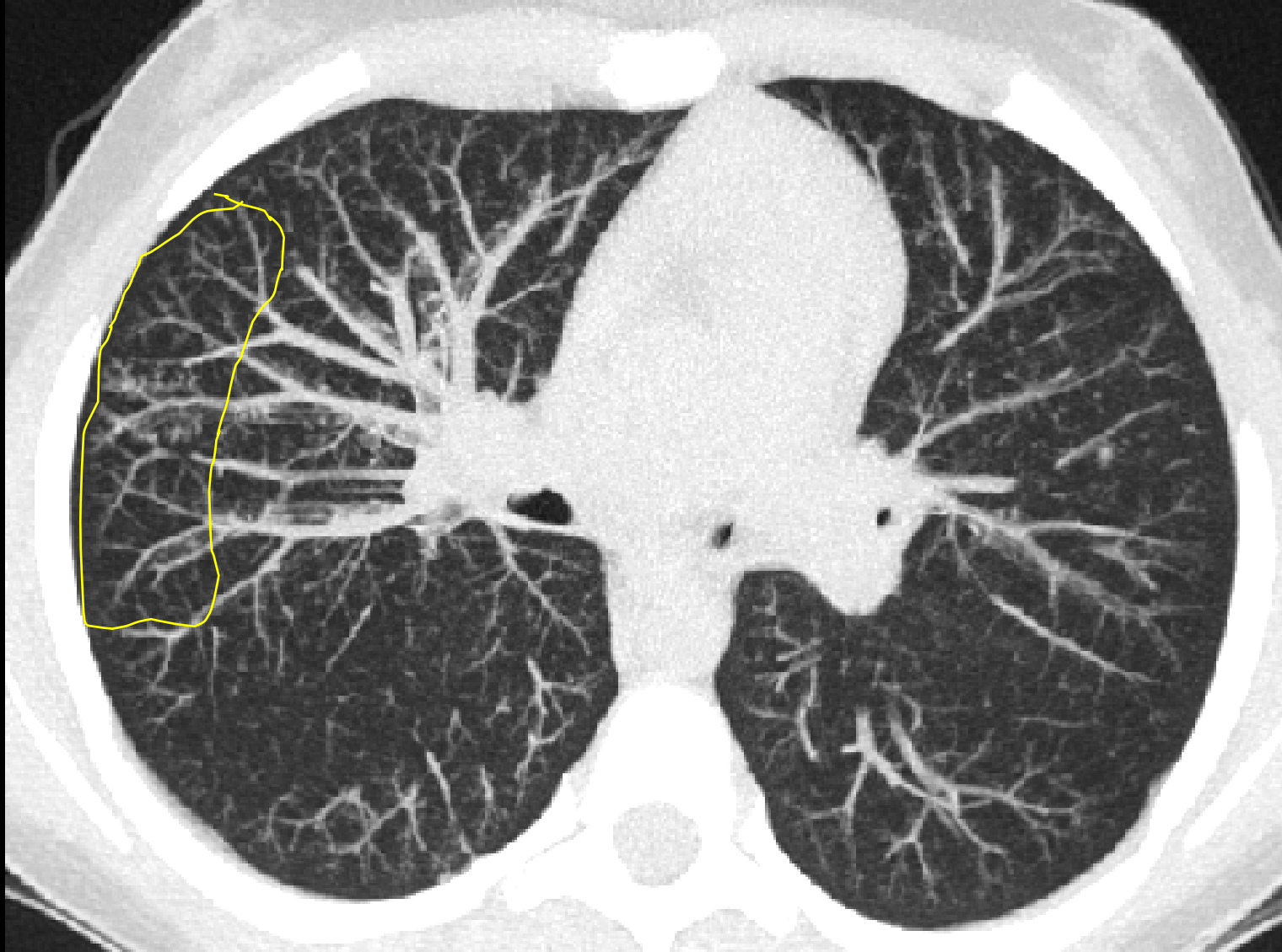


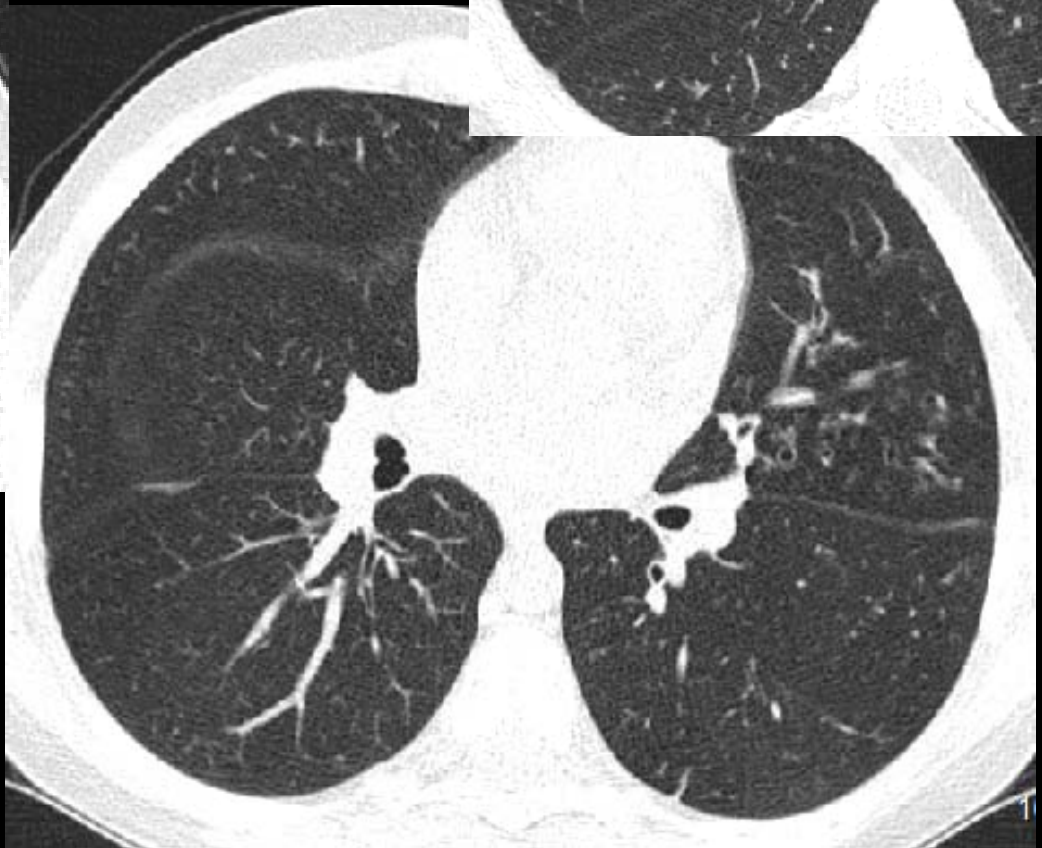
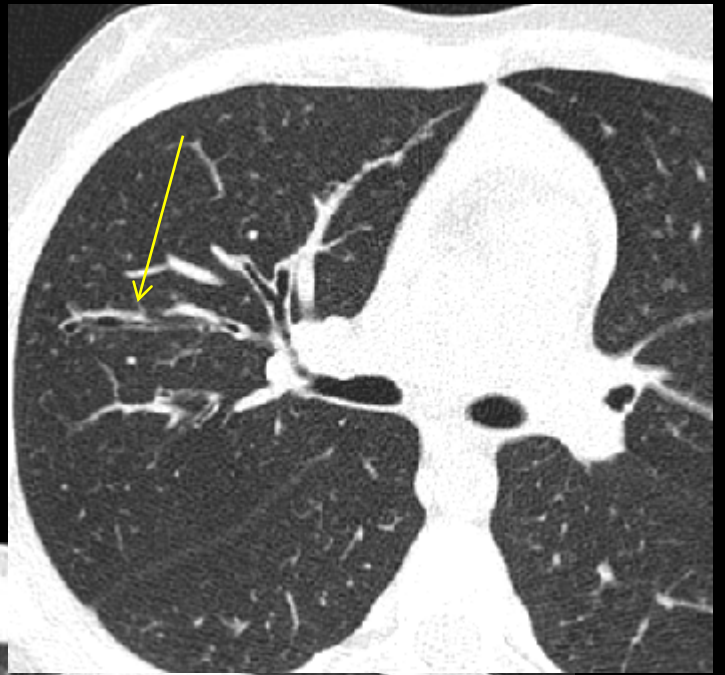
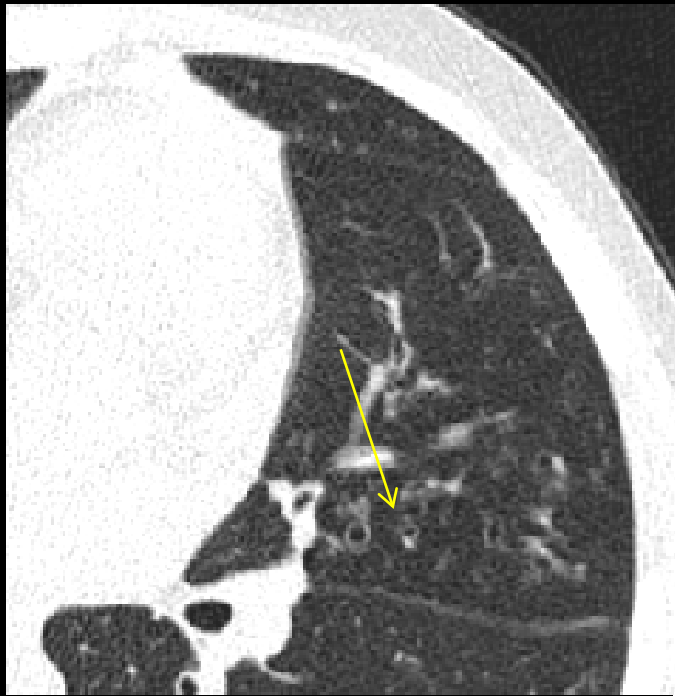# Bronquioloectasia



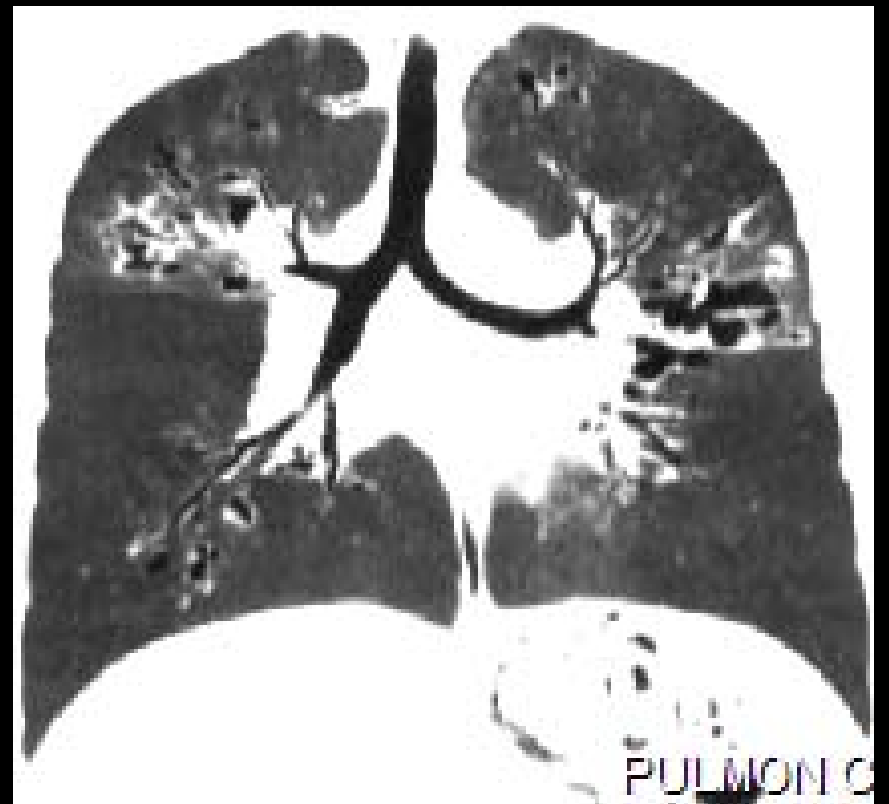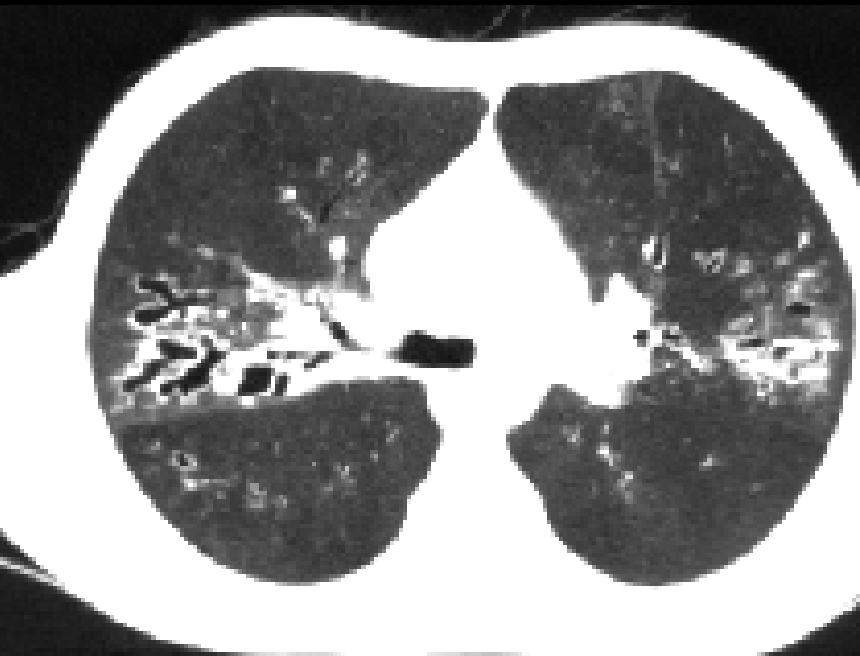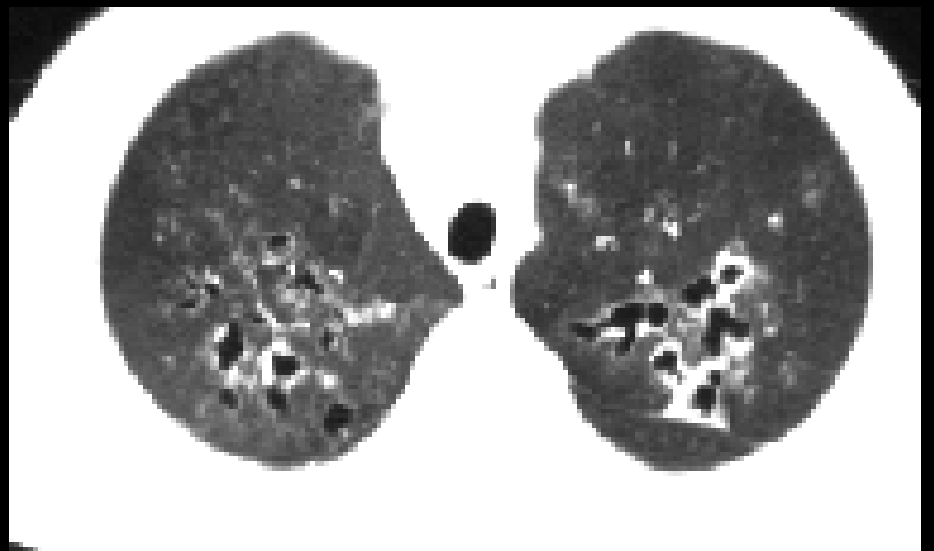


# MIP del paciente arbol en brote

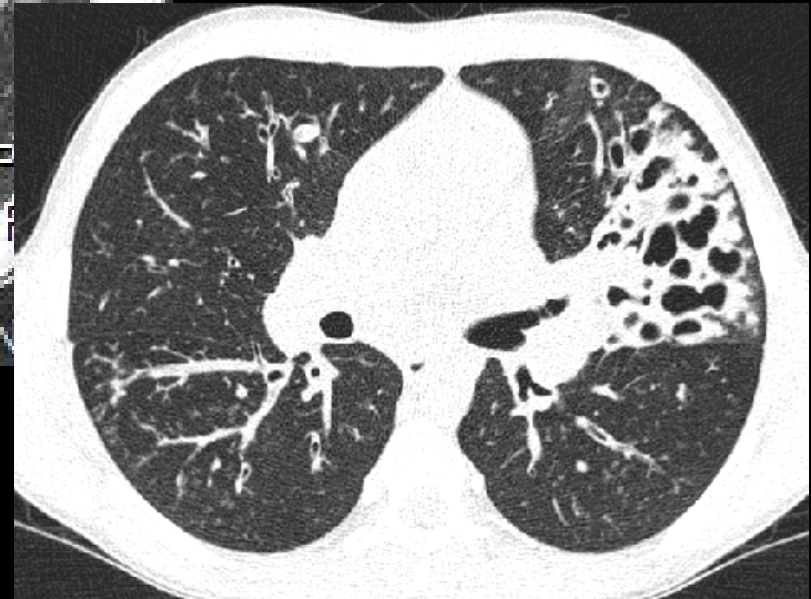
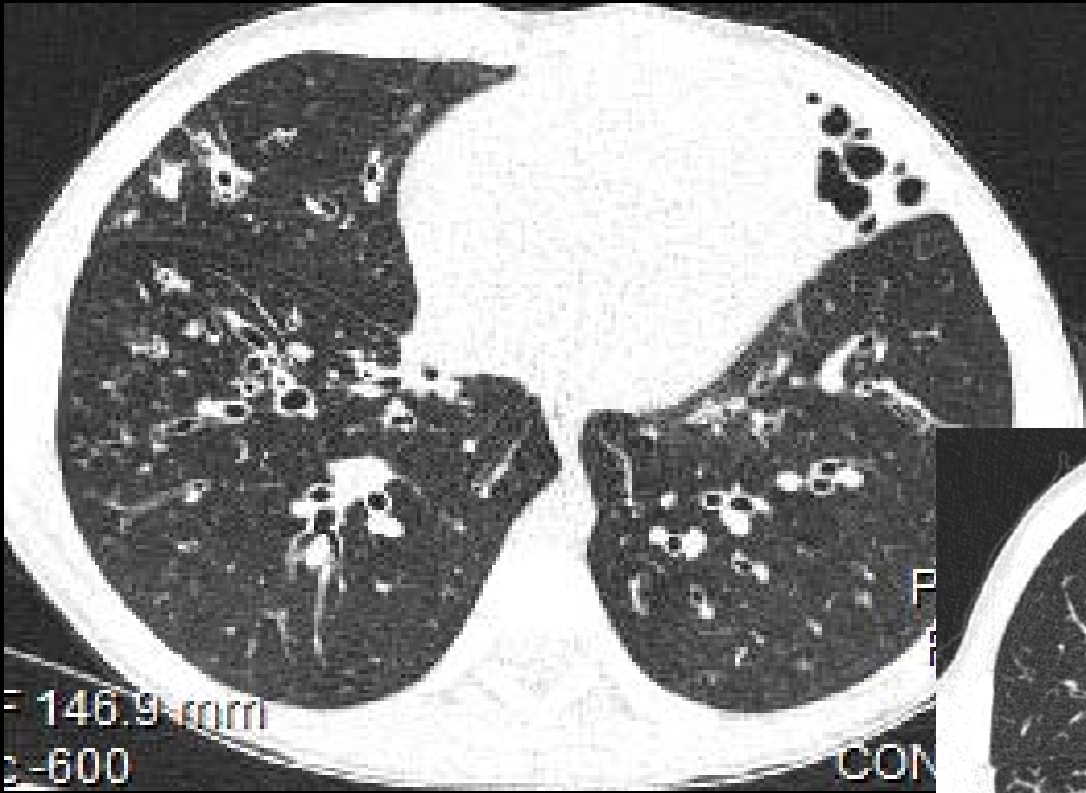
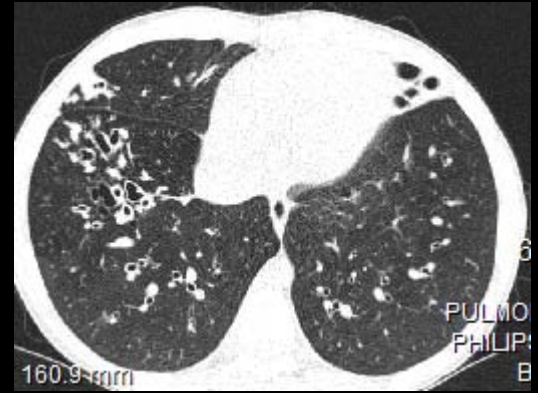


Minip

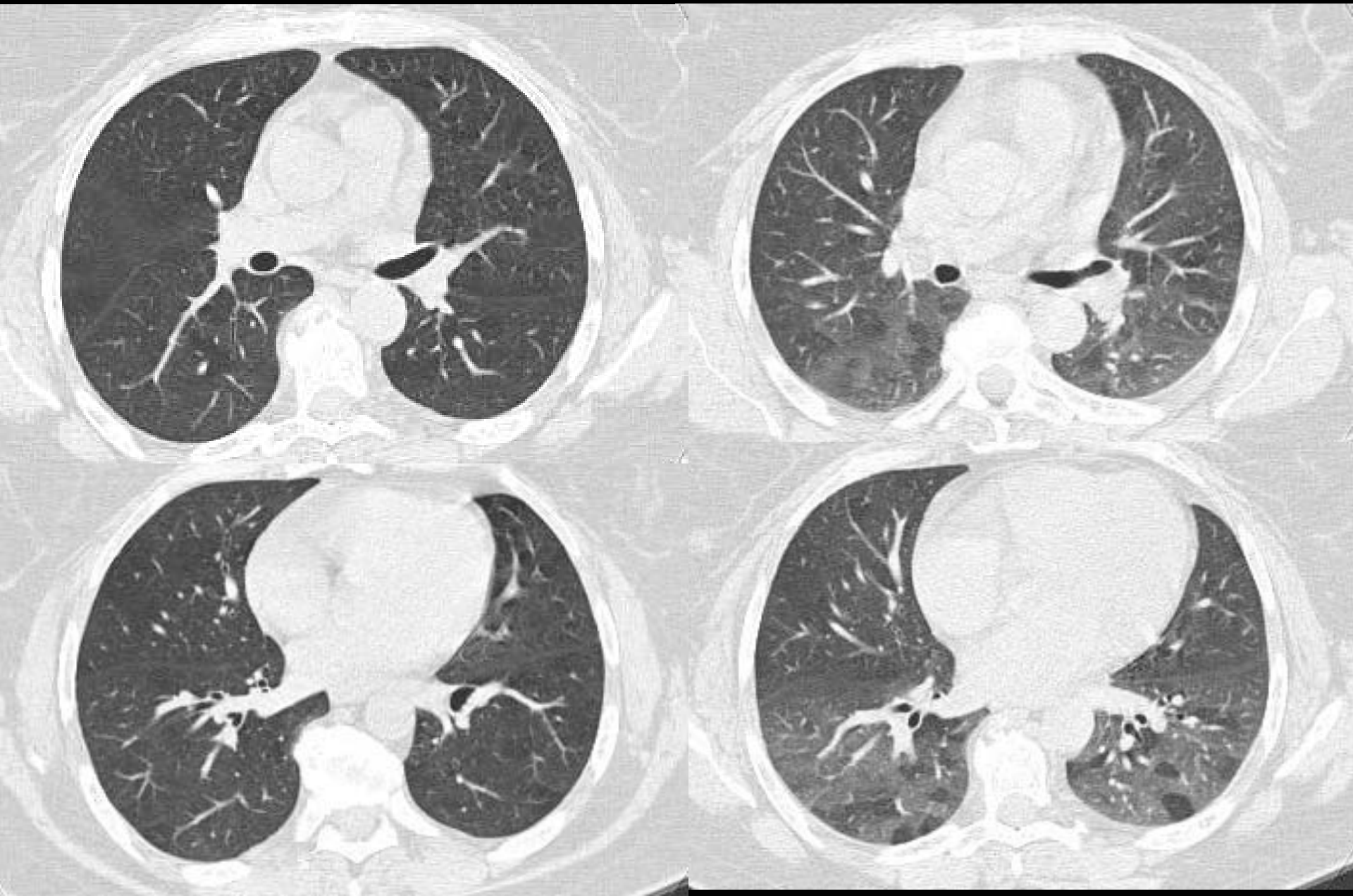


AR

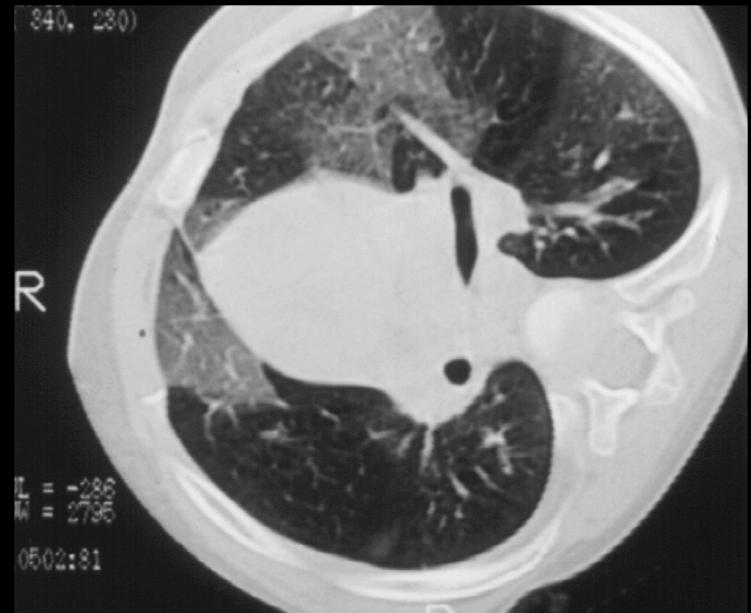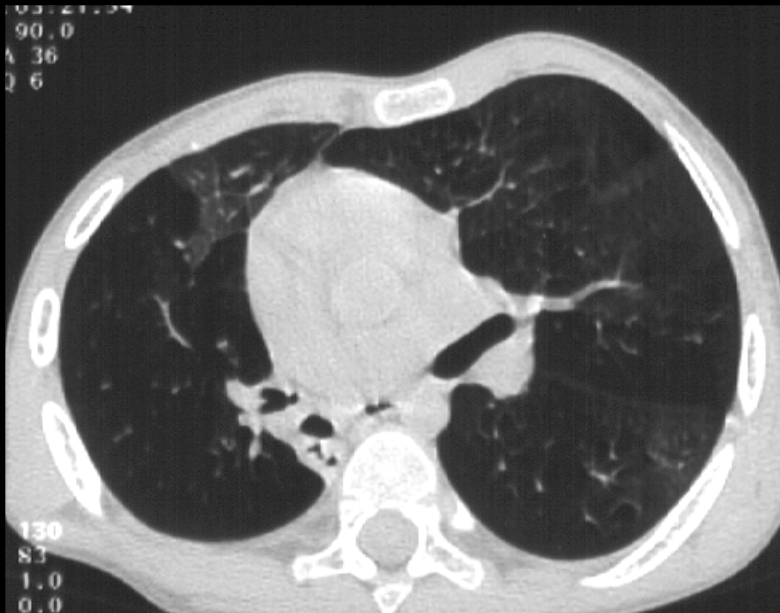

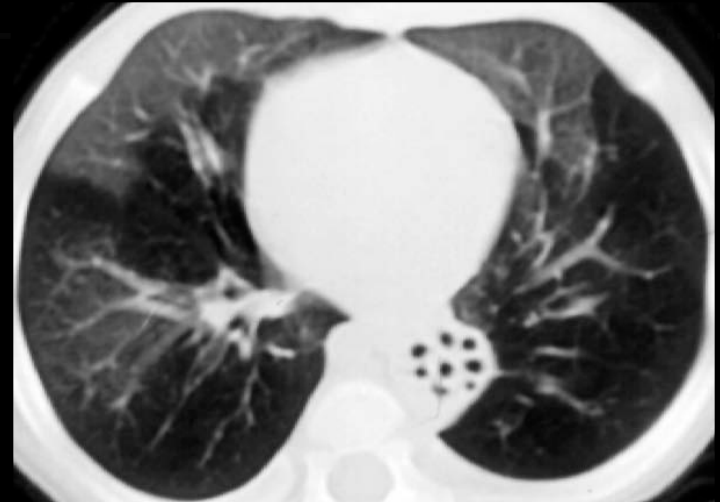
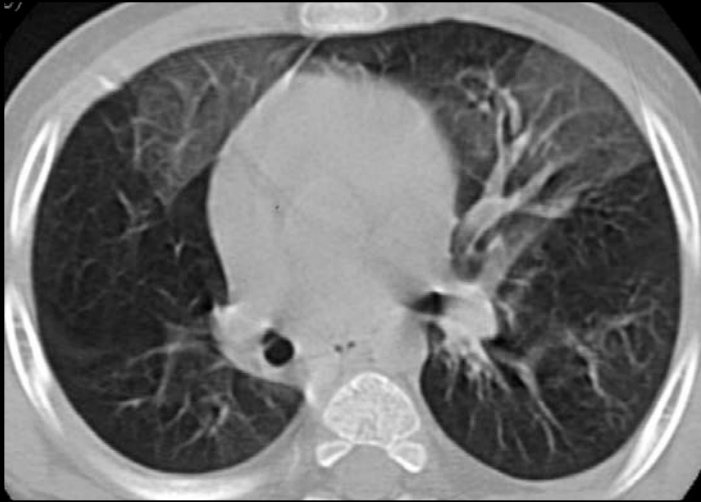

# Atrapamiento Aereo (Inspi - Espi)

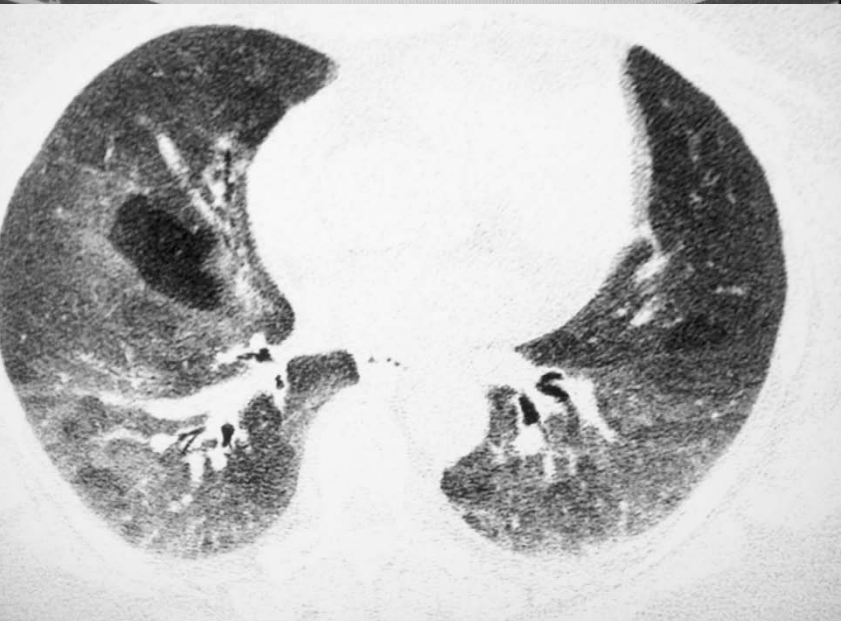
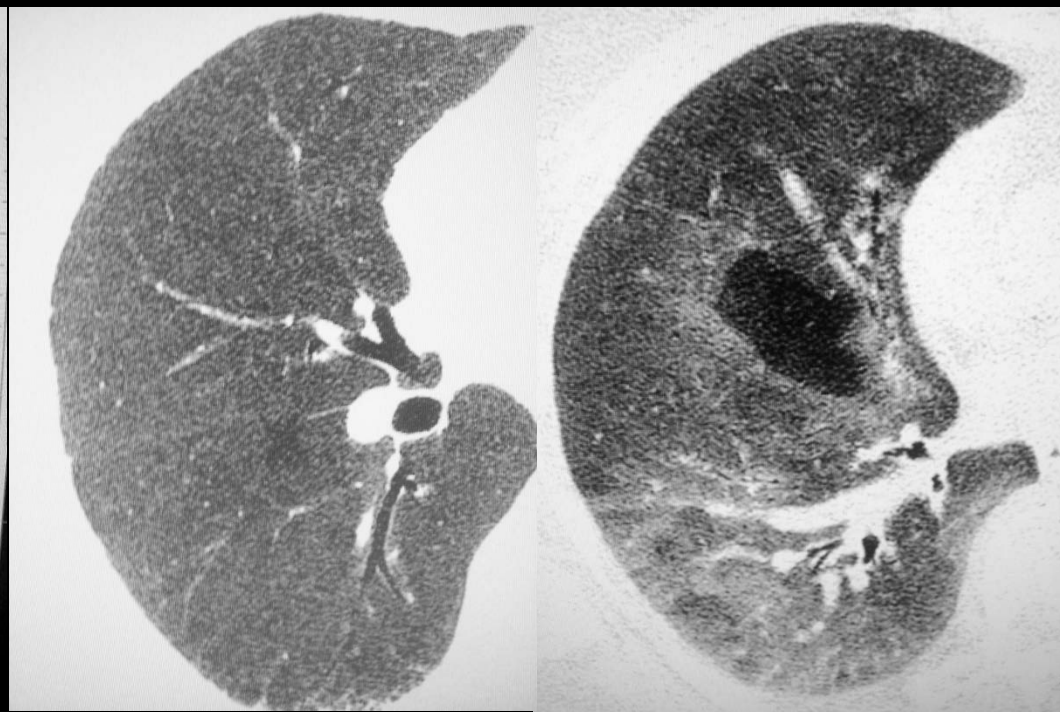
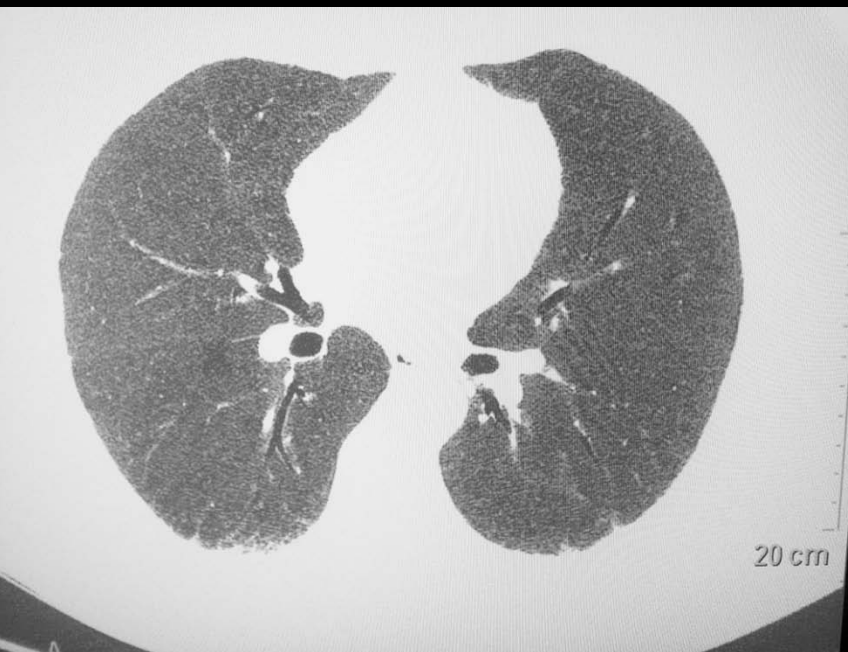


# Atrapamiento Aereo

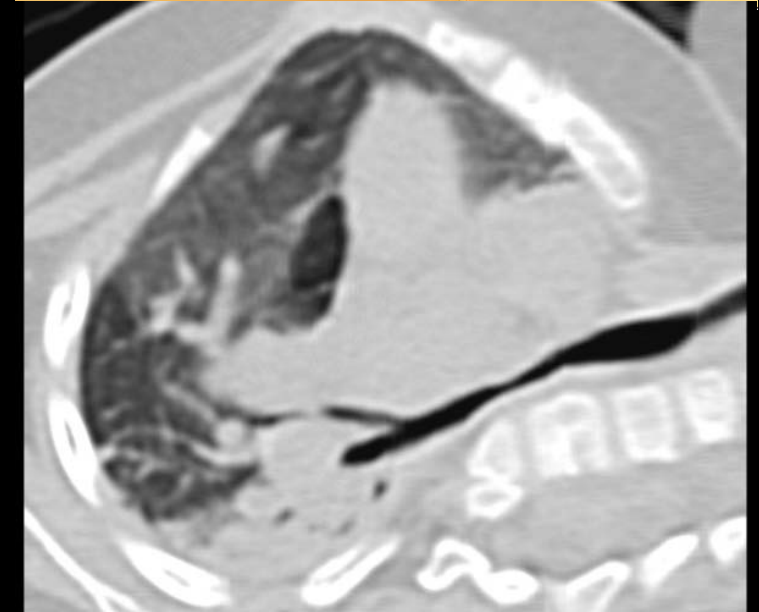
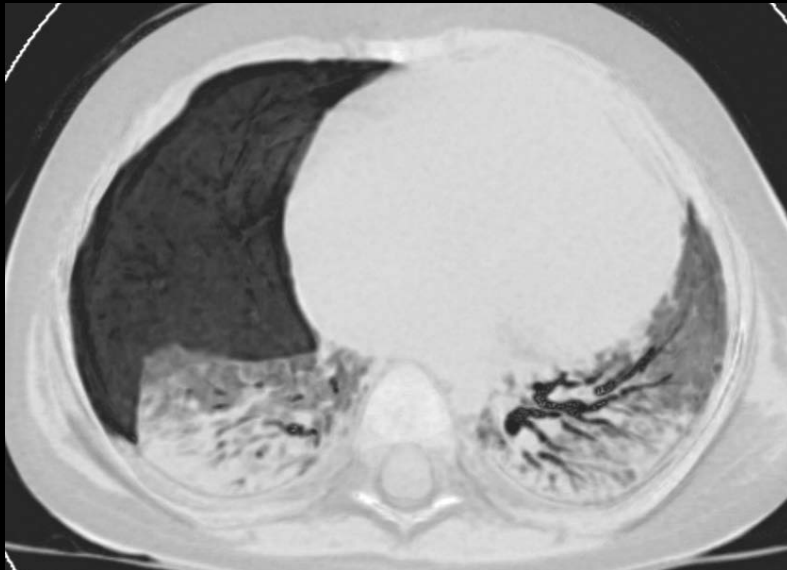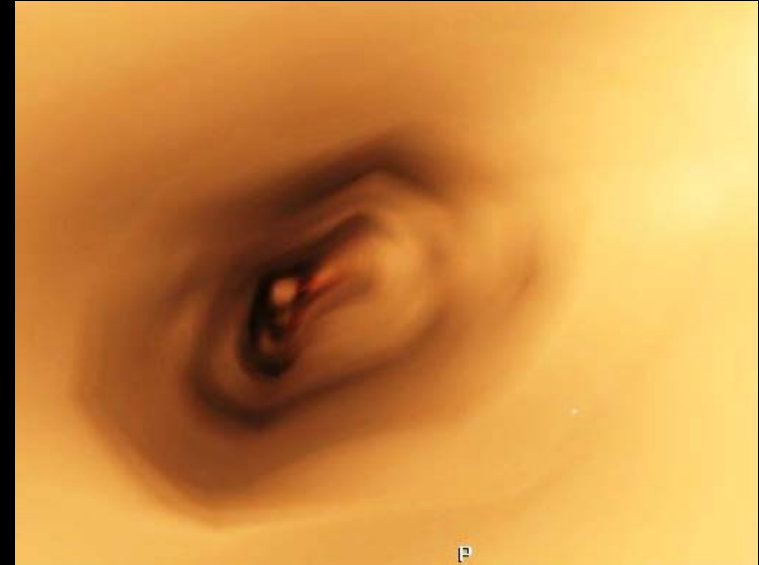
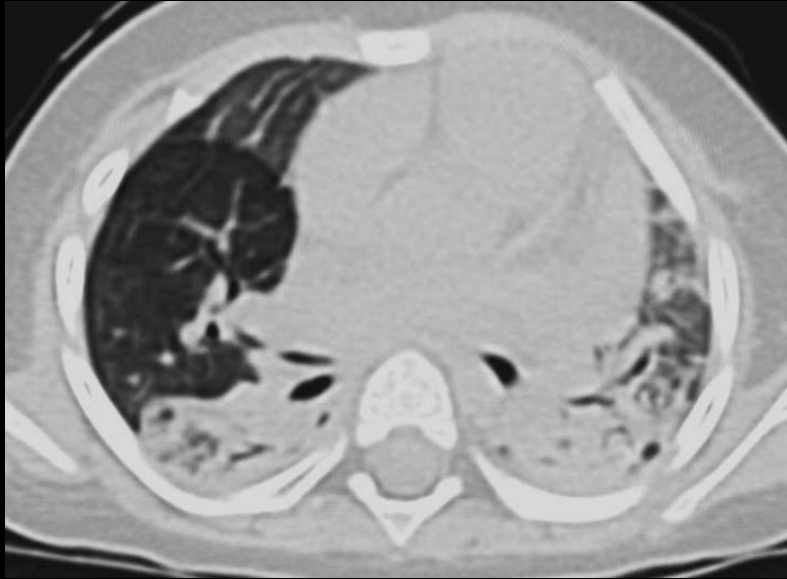




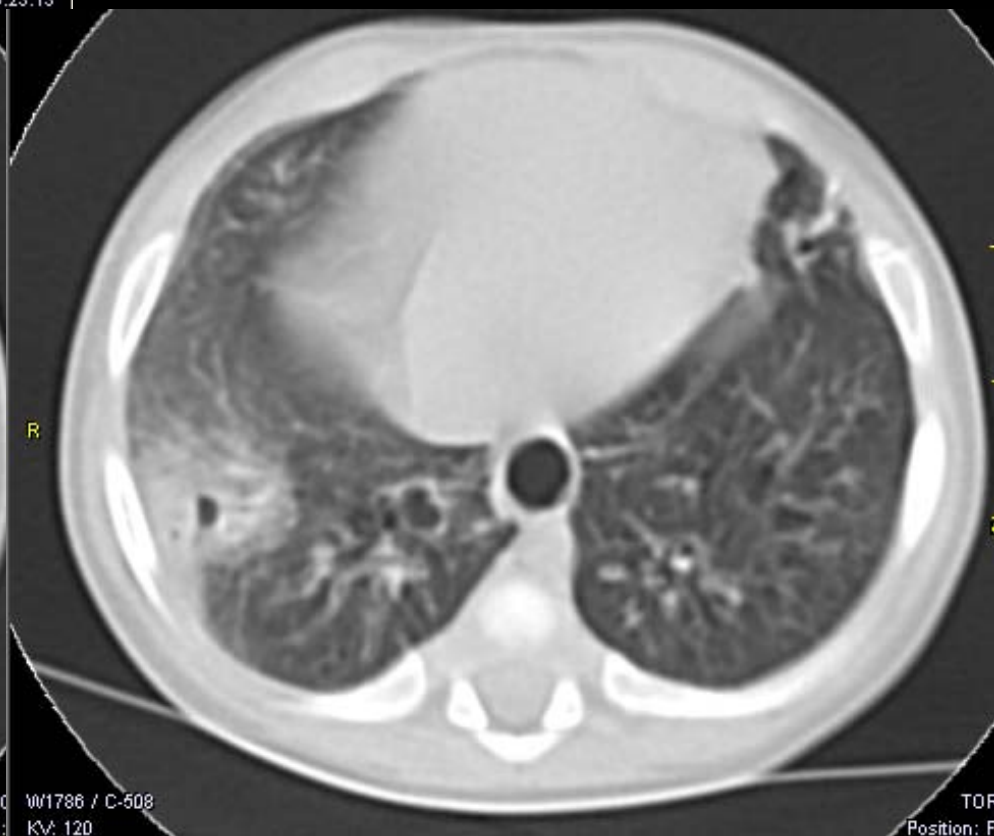
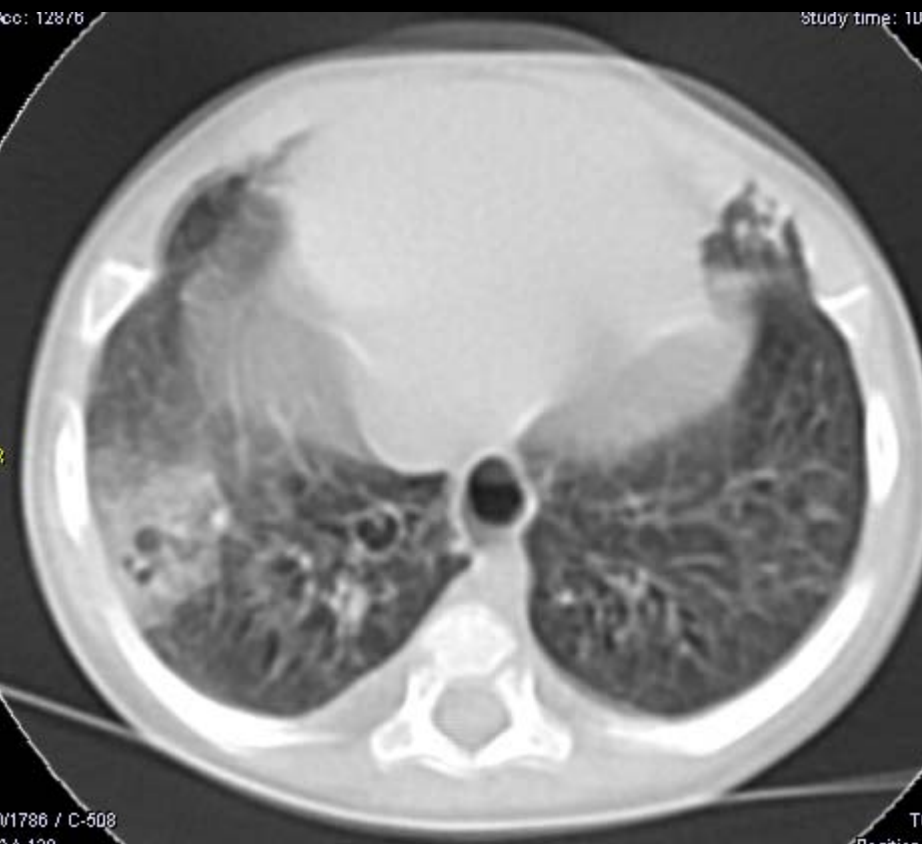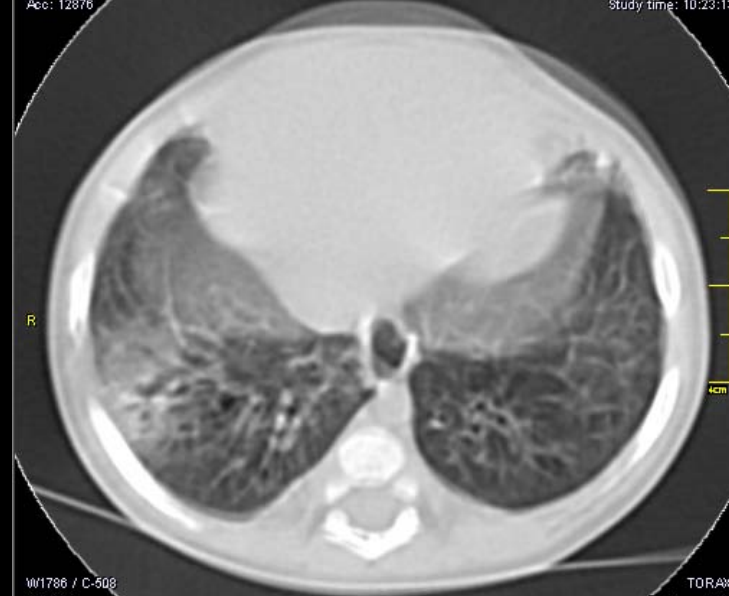# Minip inspiracion - espiracion atrapamiento aereo



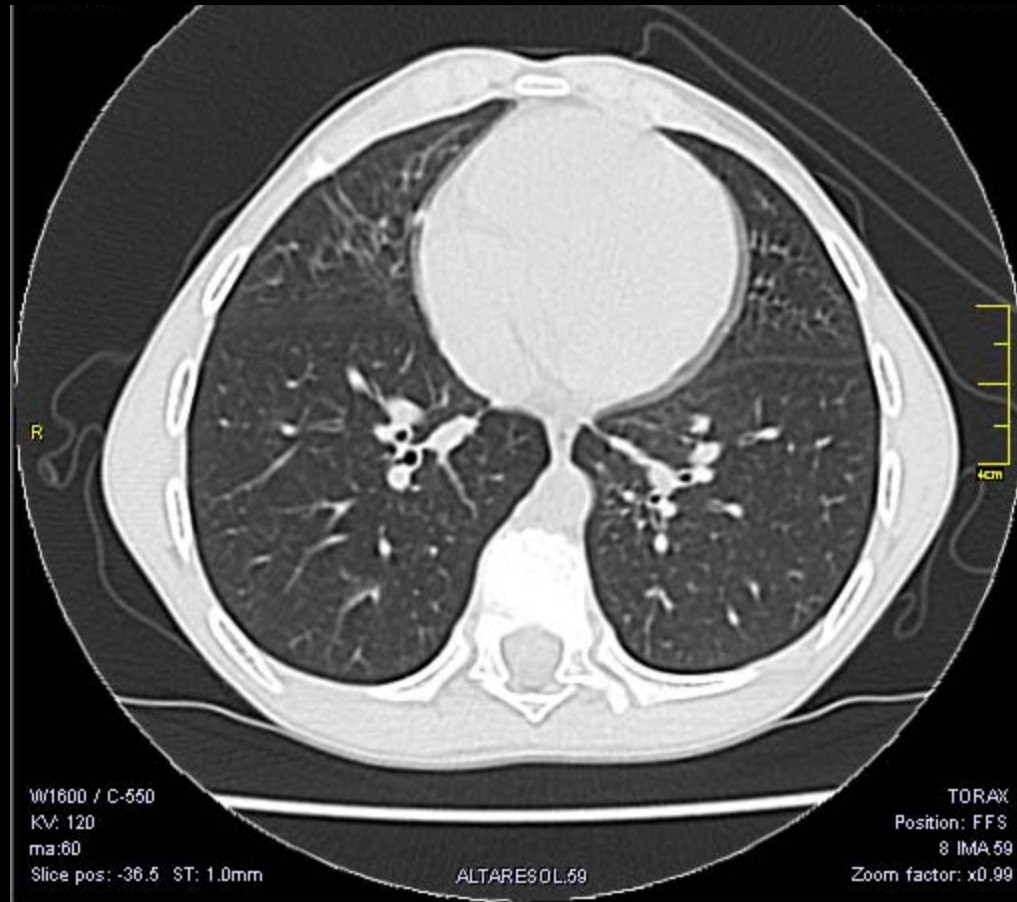
# Obstrucción parcial fenómeno valvular



# Identificando BQ en condiciones adversas lactante mascara



# Artefactos que confunden



# Bronquiectasias No FQ Causas

- **Infección o aspiración** (Aspiración Recurrente, TBC, Mycobacterias atípicas, Swyer James)
- **Congénitas** (Disquinesia ciliar, atresia bronquial, Mounier Khun, Williams Campbell)
- **Enfermedad difusa pulmonar fibrosante** (fibrosis pulmonar, distress, sarcoidosis)
- **Lesión endo o peribronquial** (Tumor, Cuerpo Extraño, estenosis, compresión)
- **Otras** (bronquiolitis obliterante pos TX)

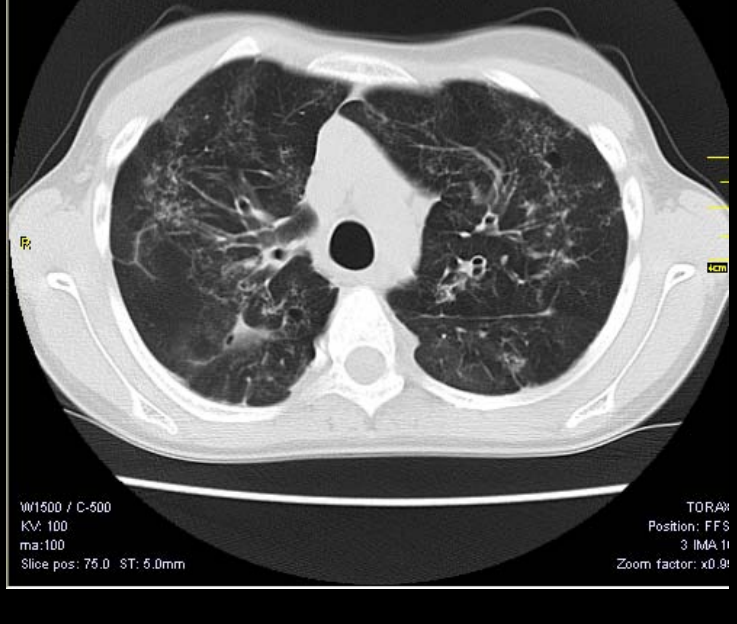
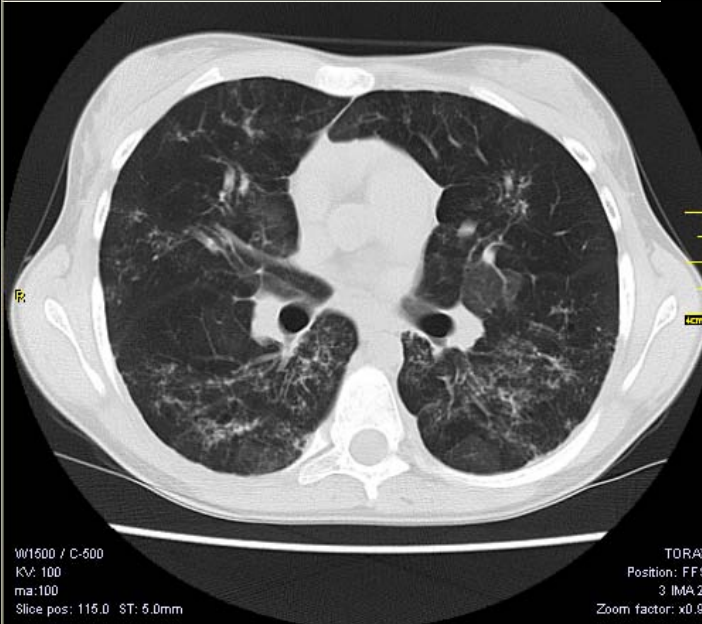
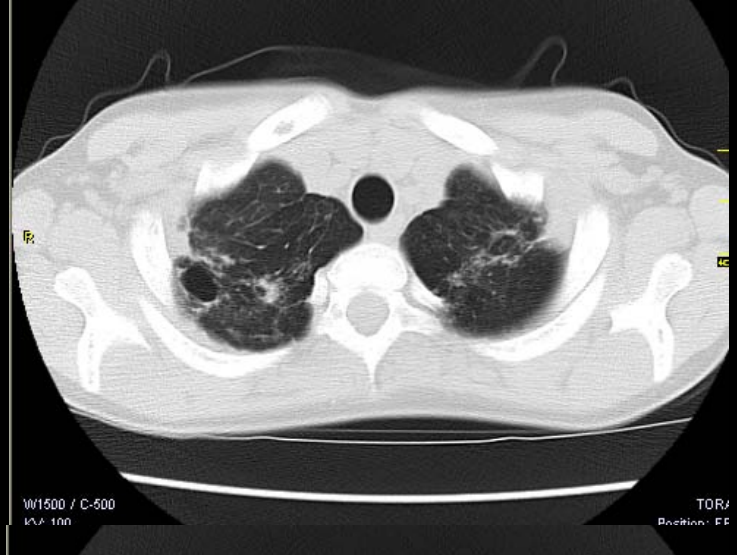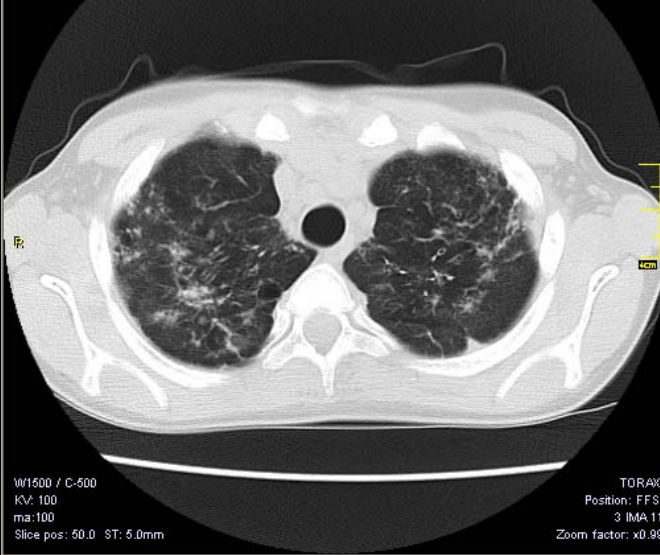# Bronquiectasias No FQ Localizacion

- **Apical** TBC, Sarcoidosis
- **Lóbulo Medio Lingula** Disquinesia ciliar
- **Central** ABPA Mounier Khun
- **Basal** Aspiración Fibrosis
- **Focal** Tu ,Cuerpo Extraño ,  
Atresia o estenosis Bronquial , Swyer James

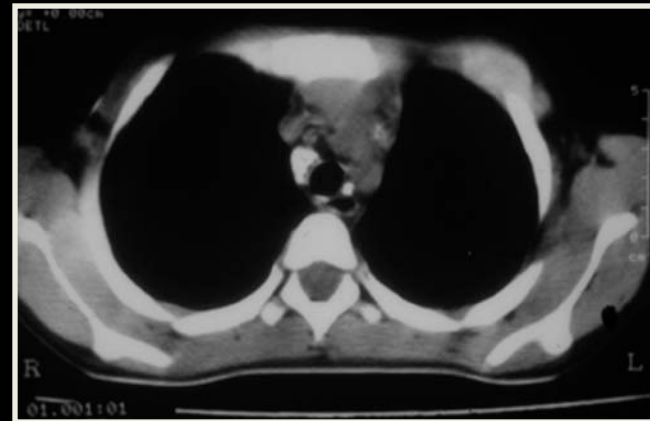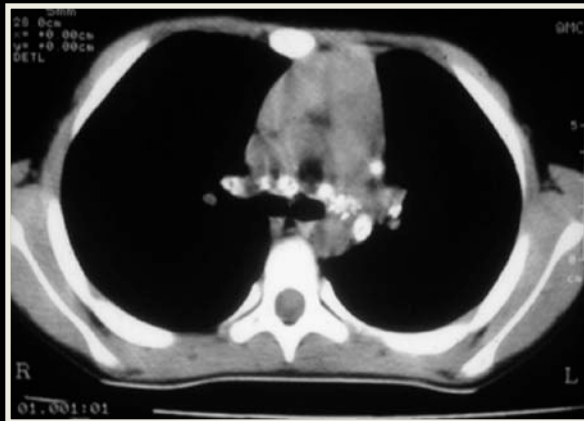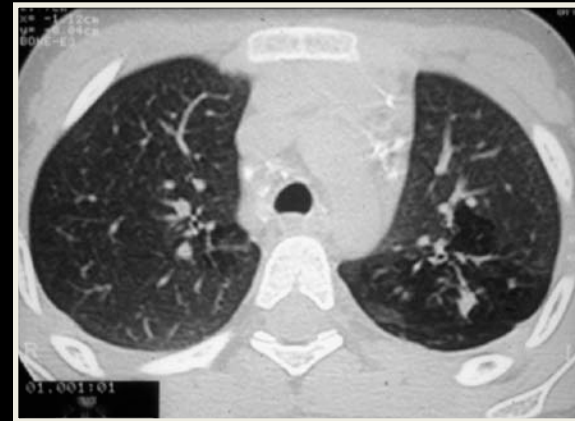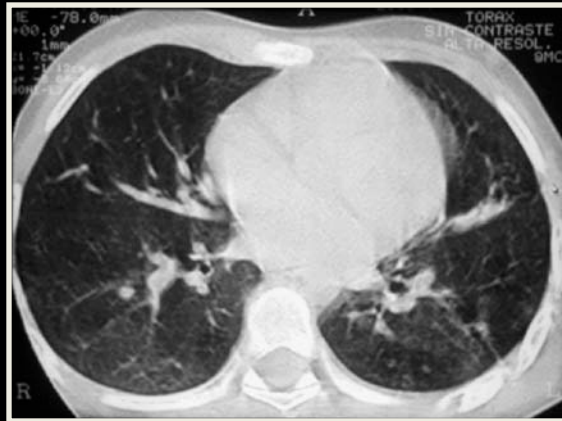(Bronchiectasis: Mechanisms and Imaging Clues of Associated Common and Uncommon Diseases  
RadioGraphics 2015; 35:1011–1030)



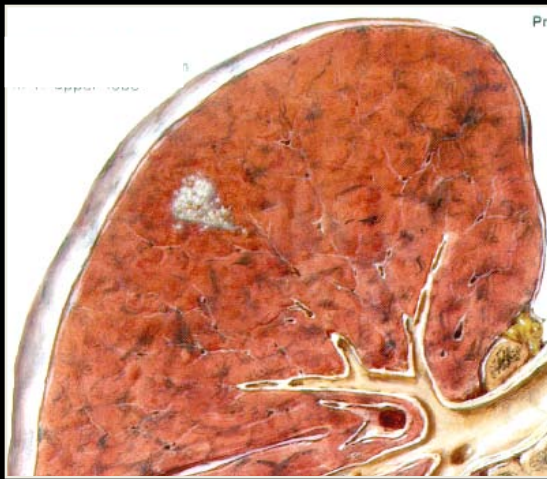
# TBC



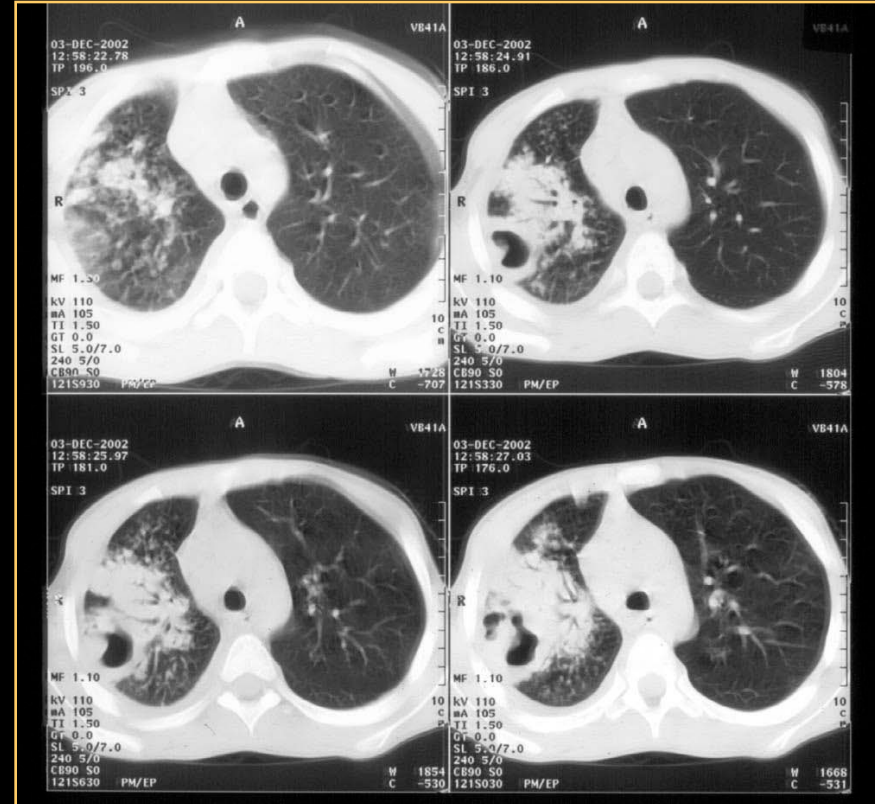
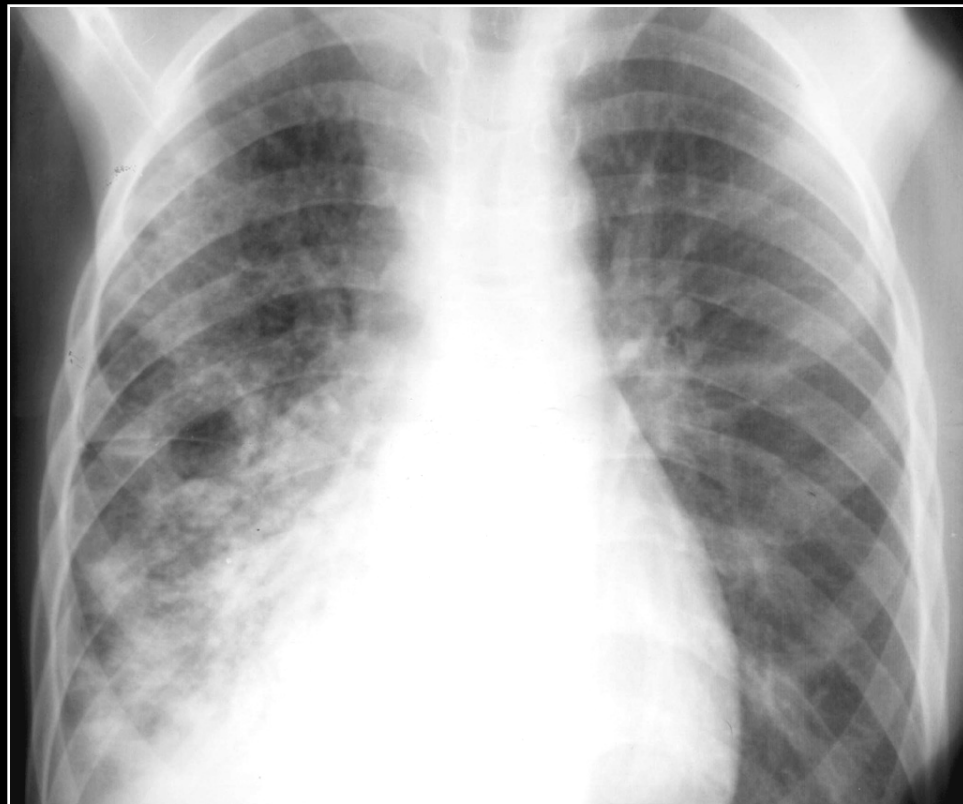
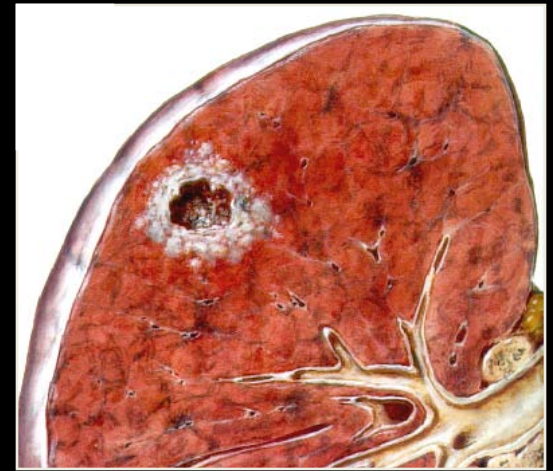# TC en TBC



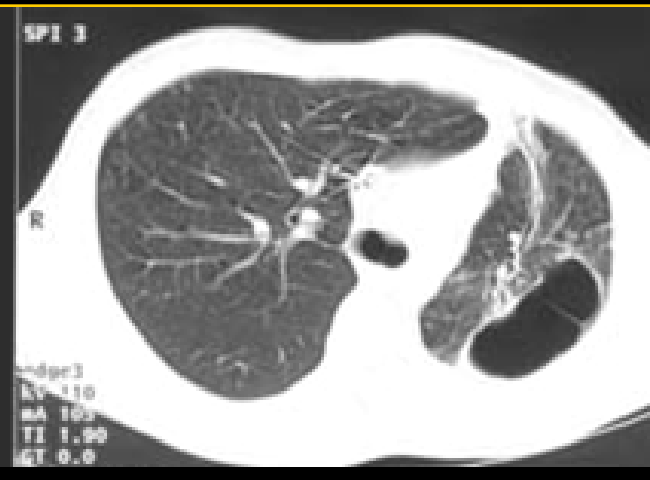
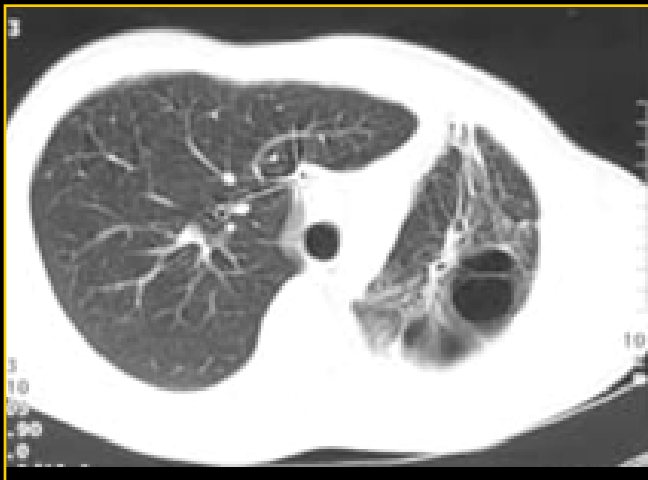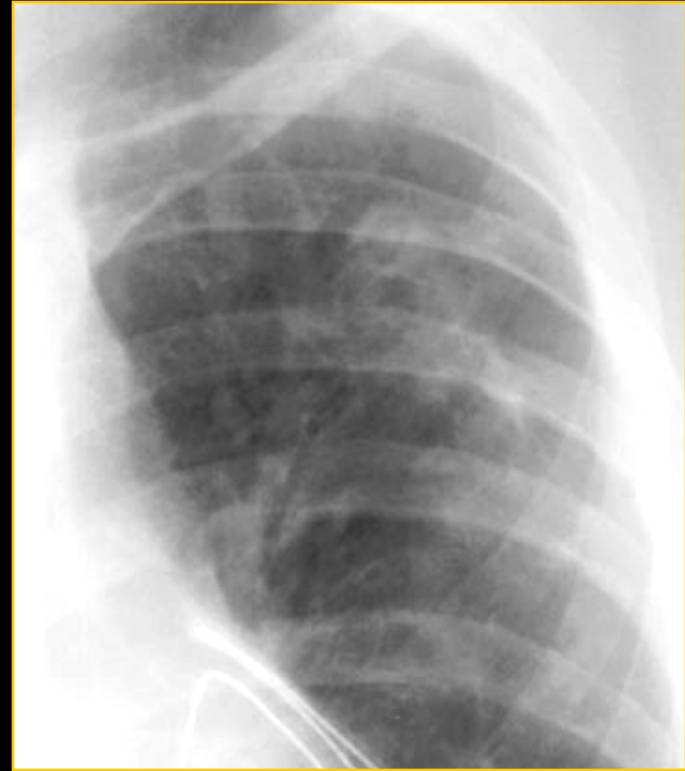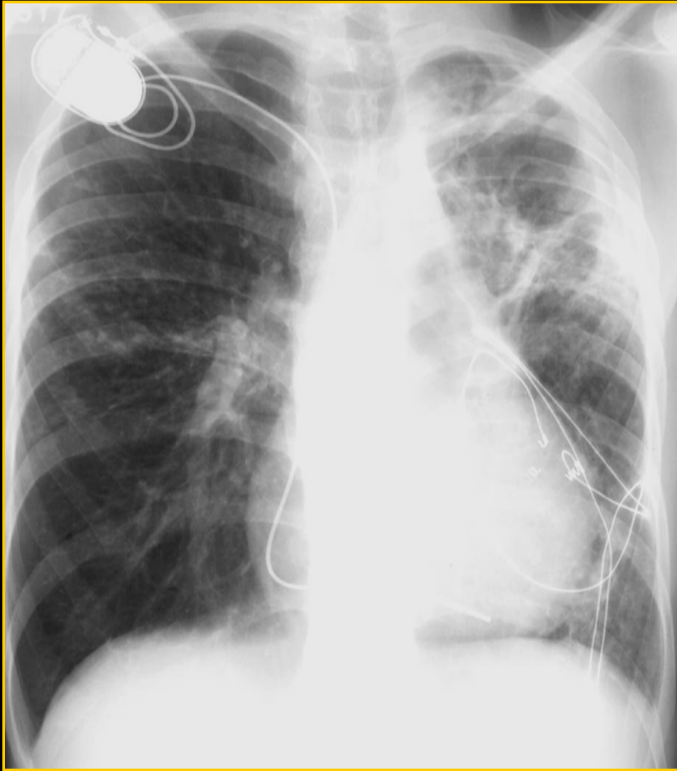




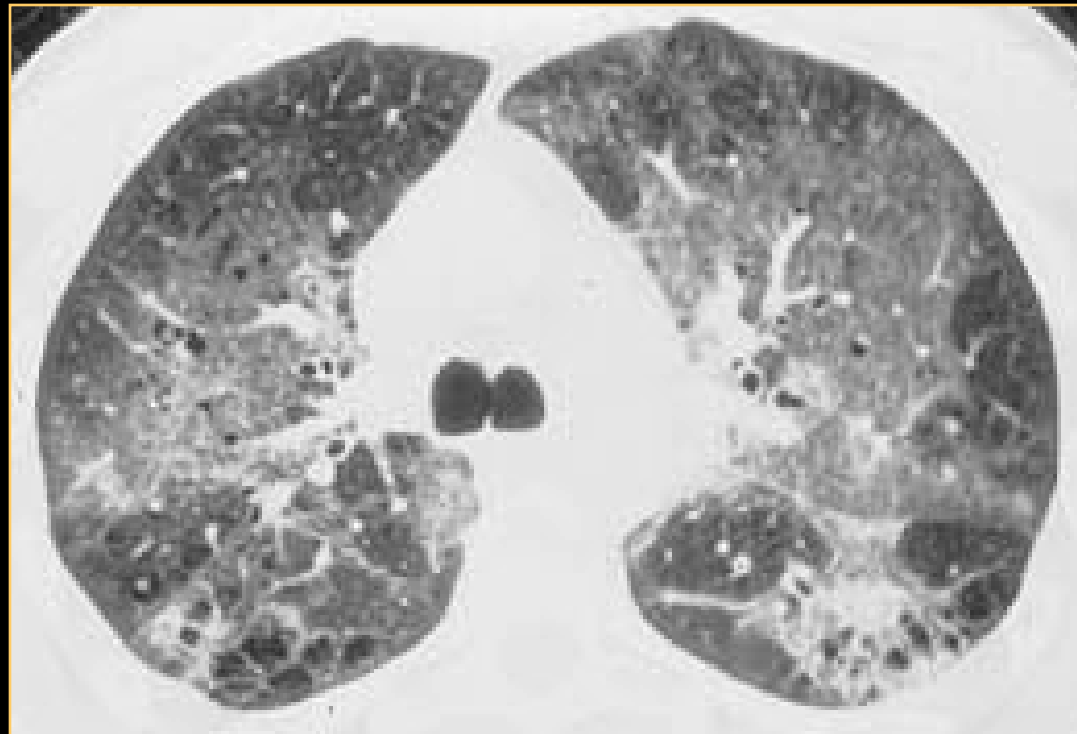
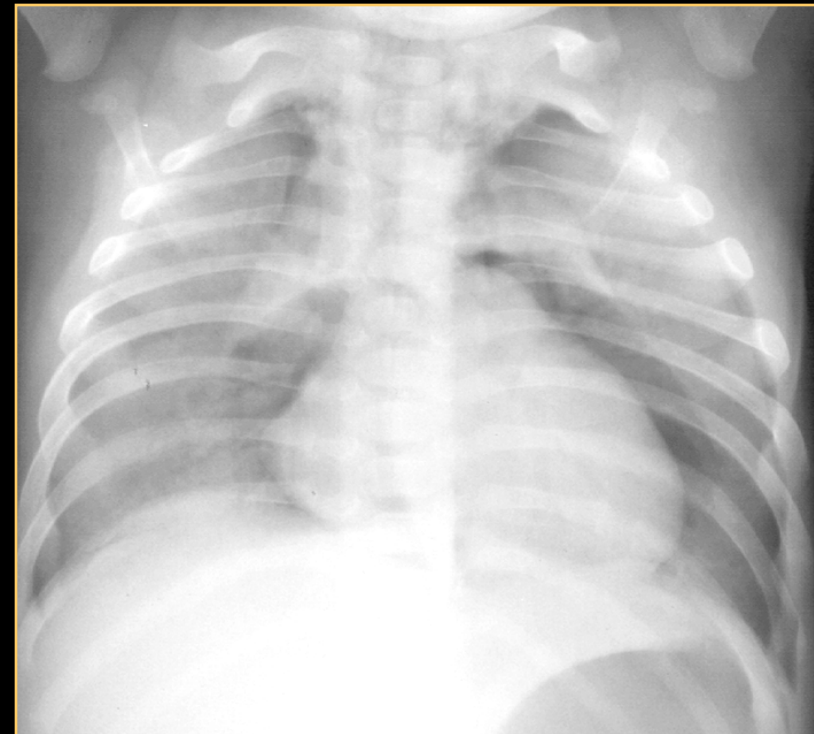
# Tuberculosis Cavidad



# Micobacterium Avium

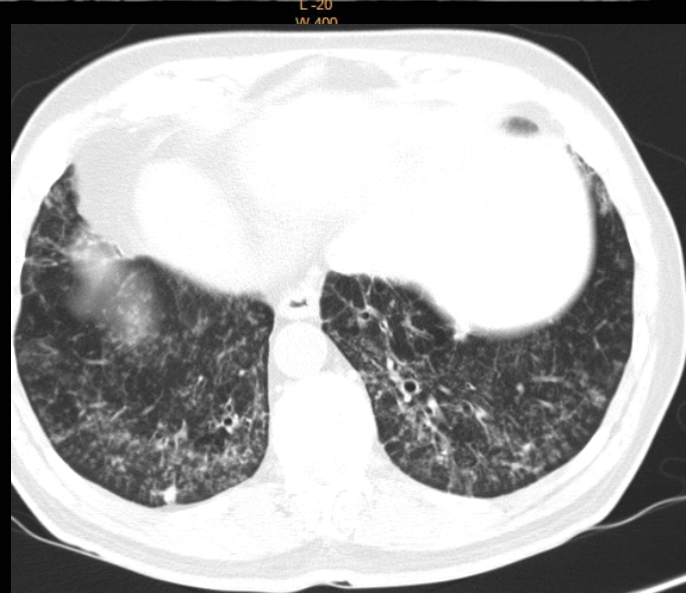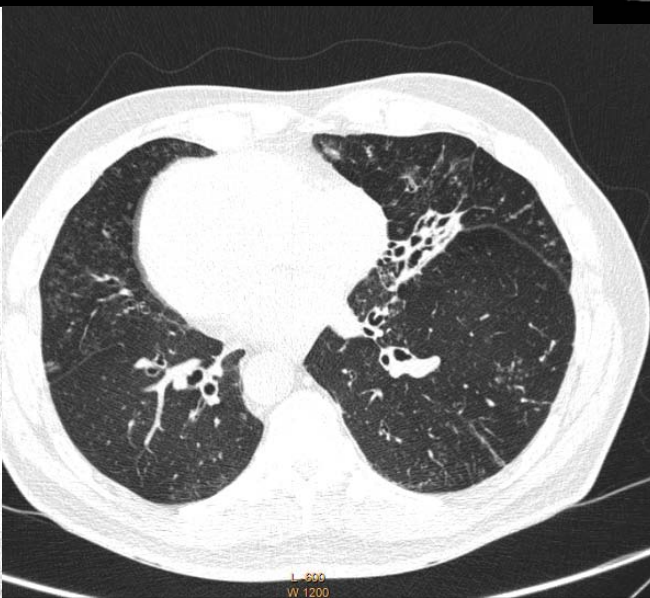
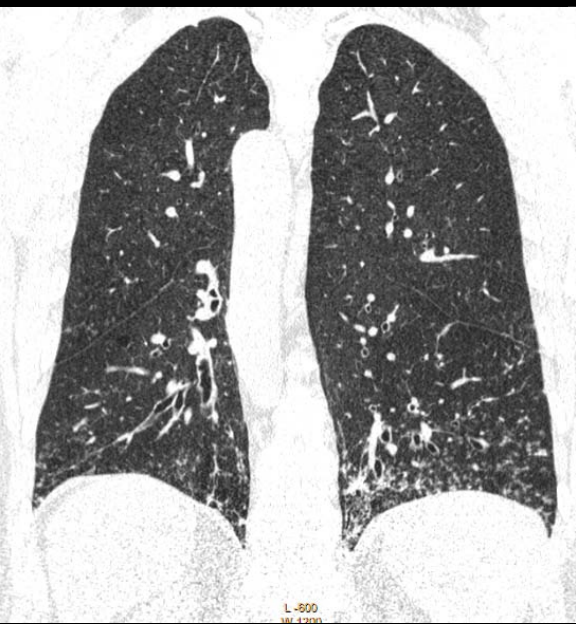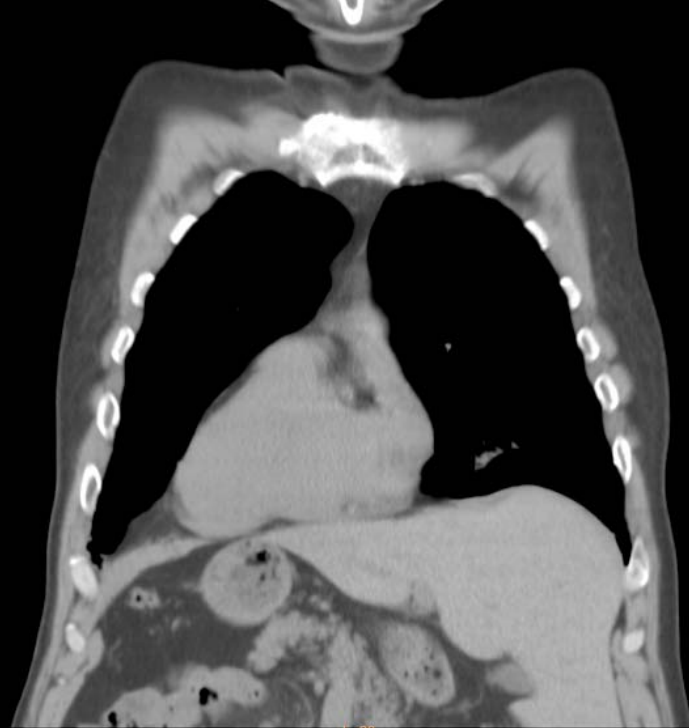
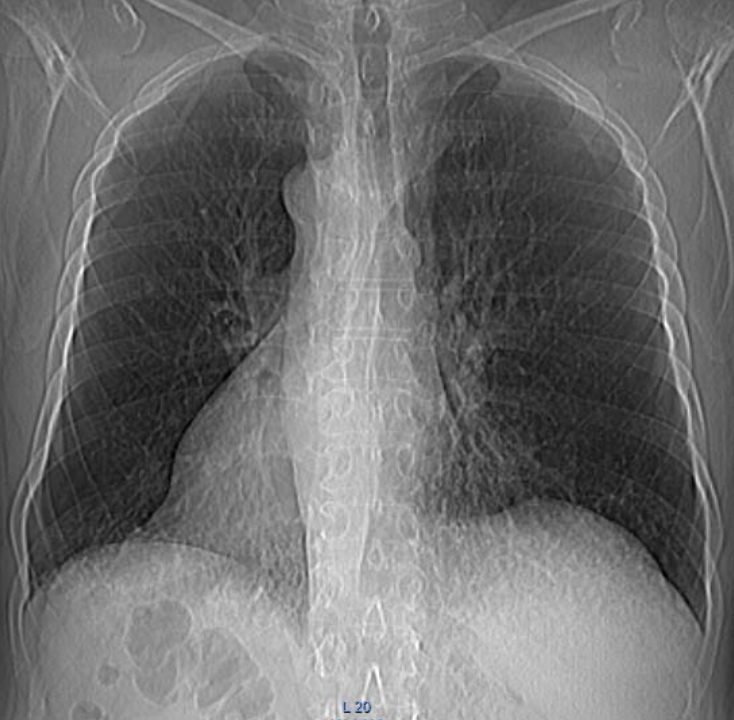


# Pneumocystis Carinii

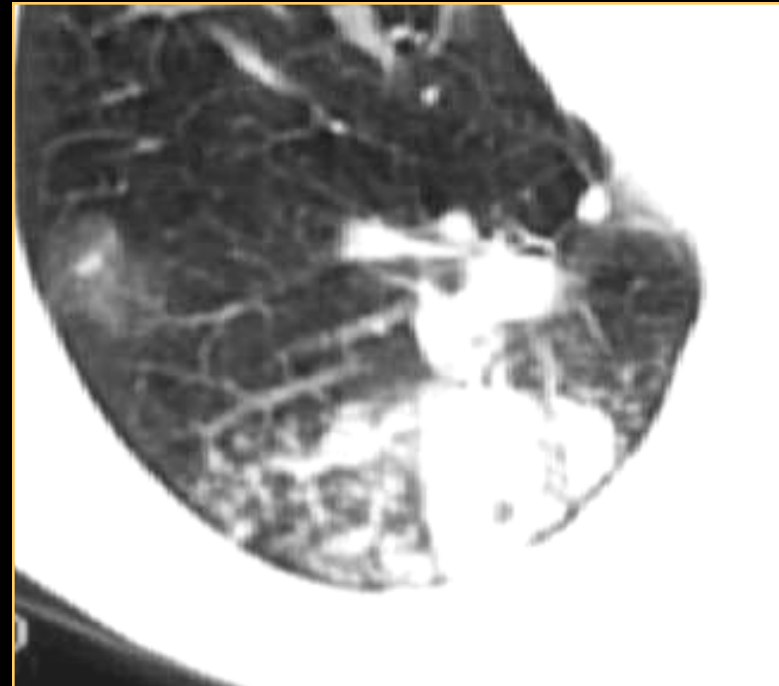
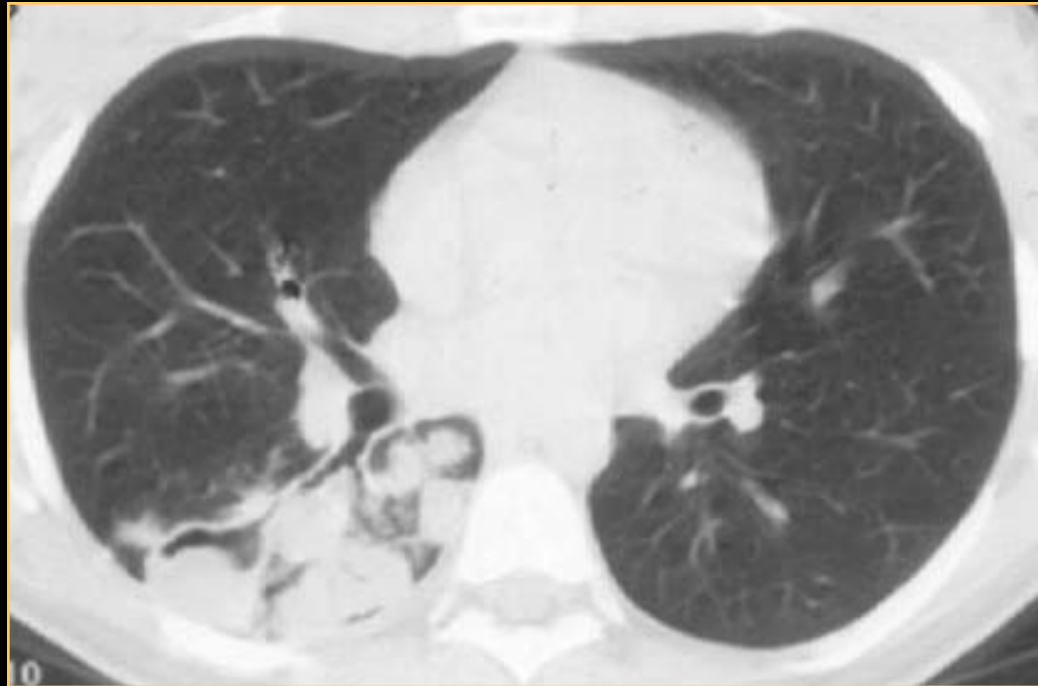




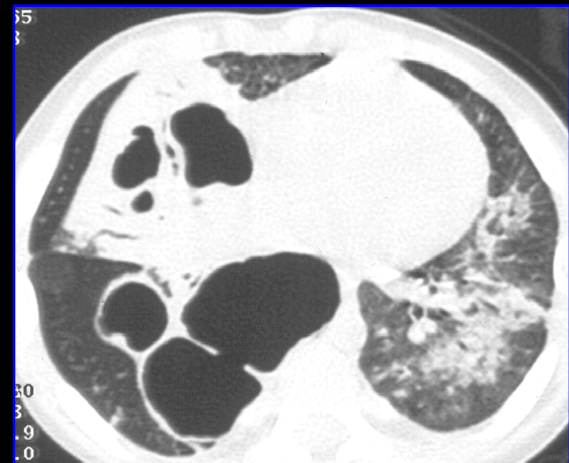
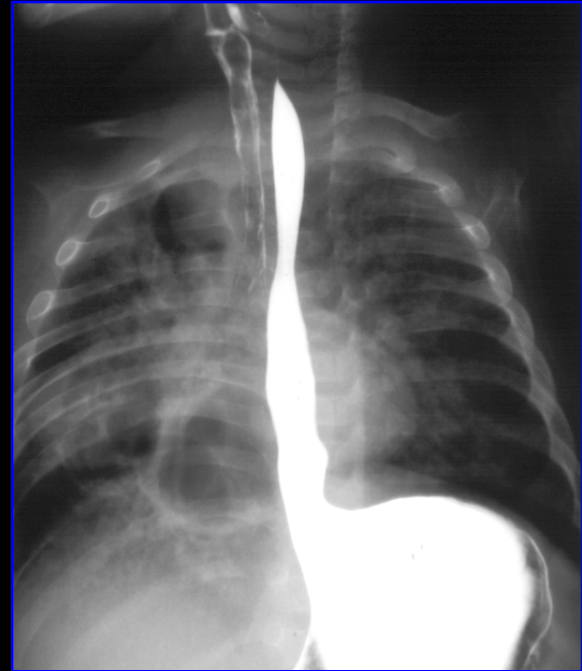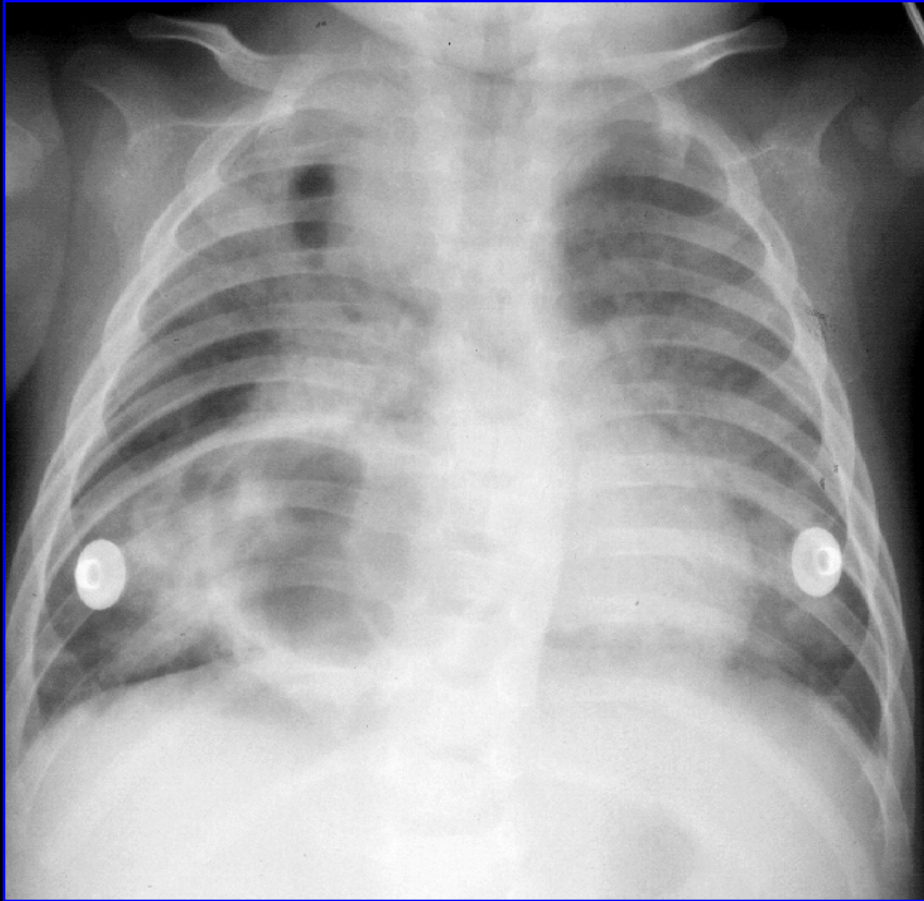
# Kartagener



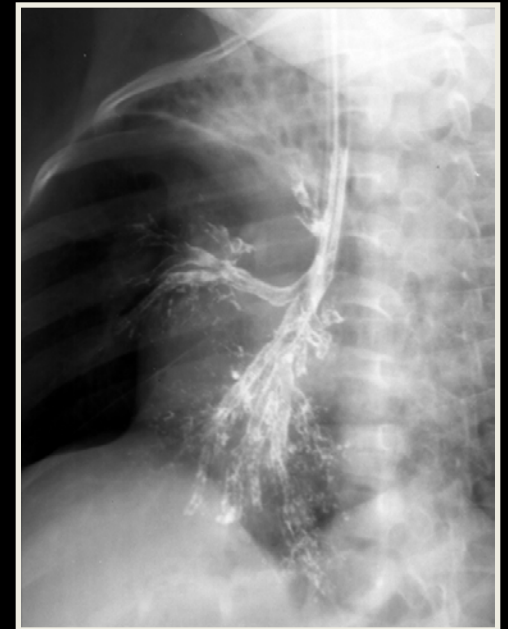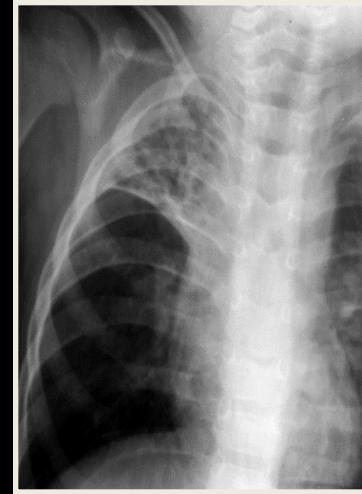
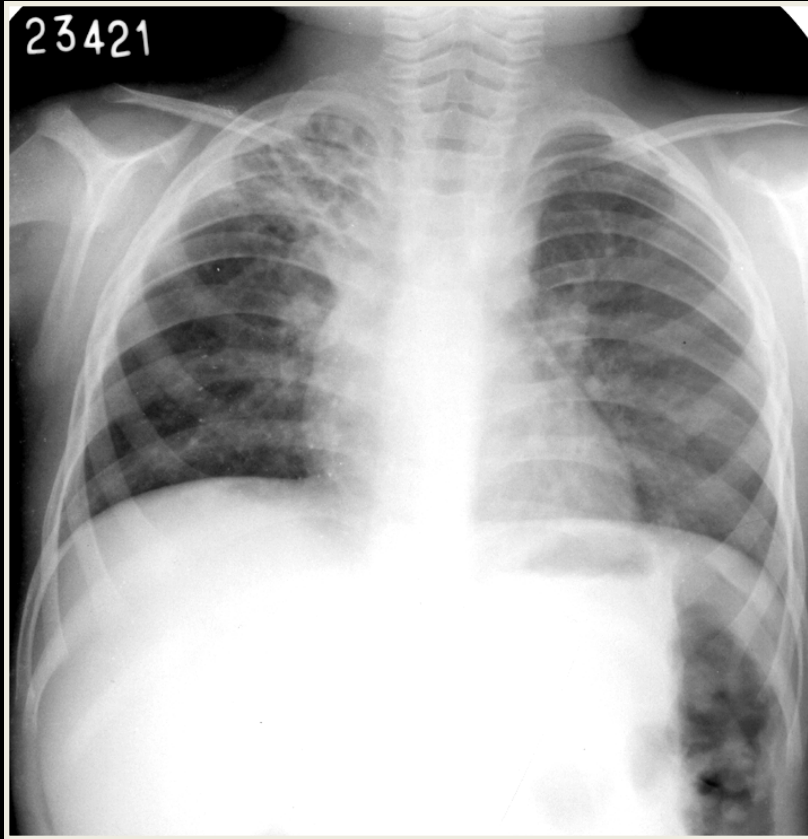
# ASPERGILOSIS Hiperdensidad



# 6 m. masc. 2da neumonía

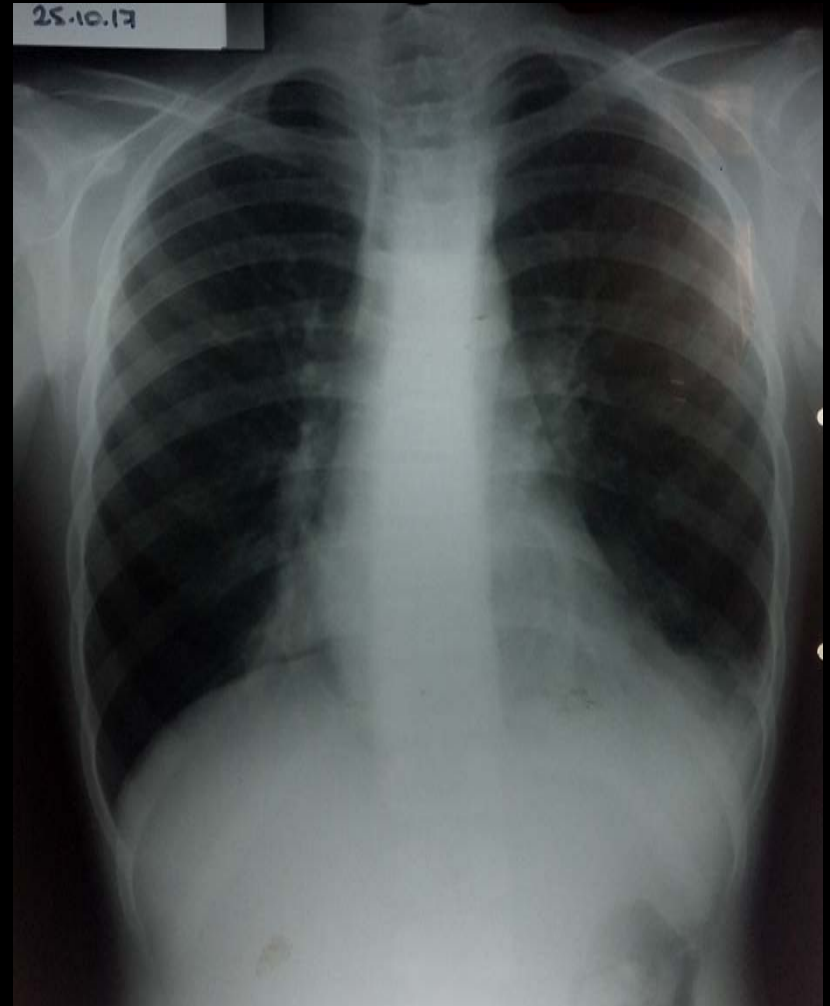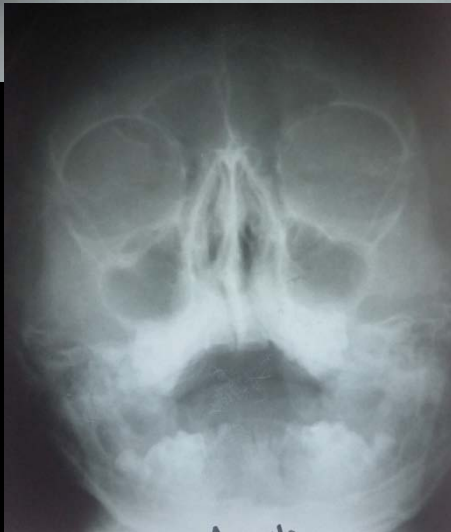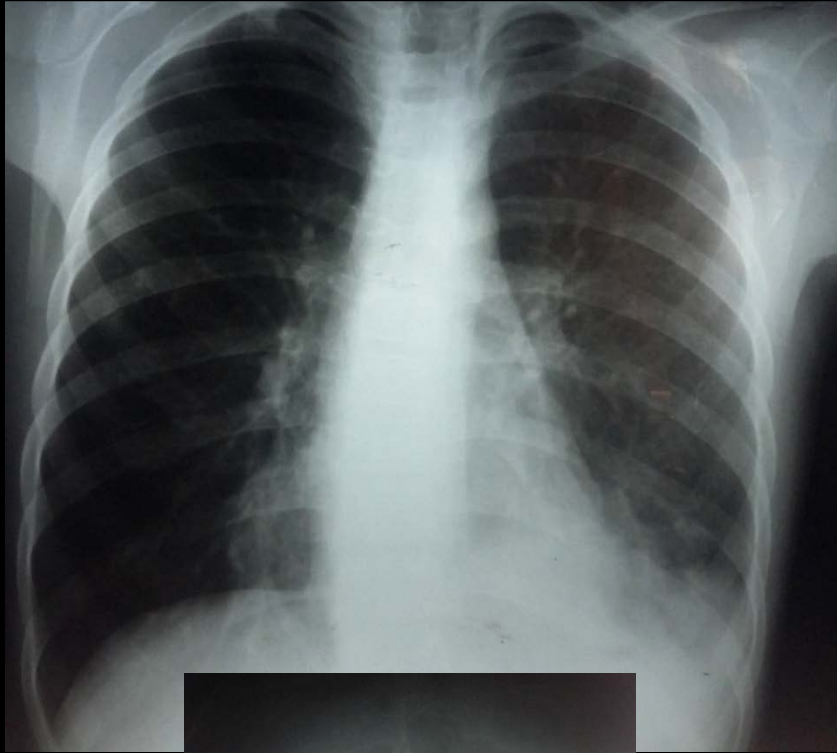


# Neumonía Aspirativa



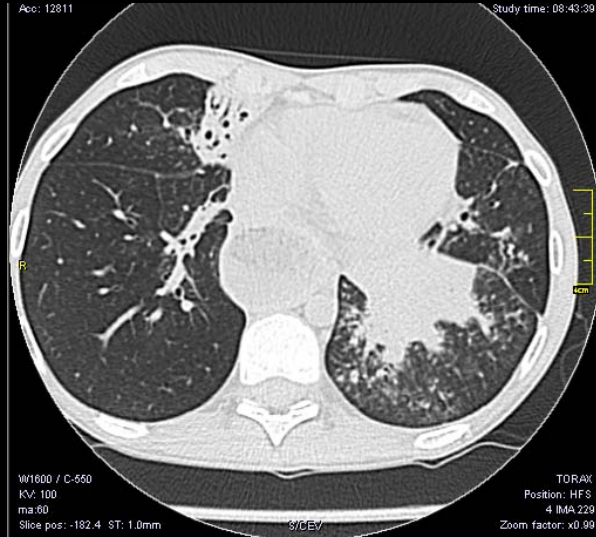
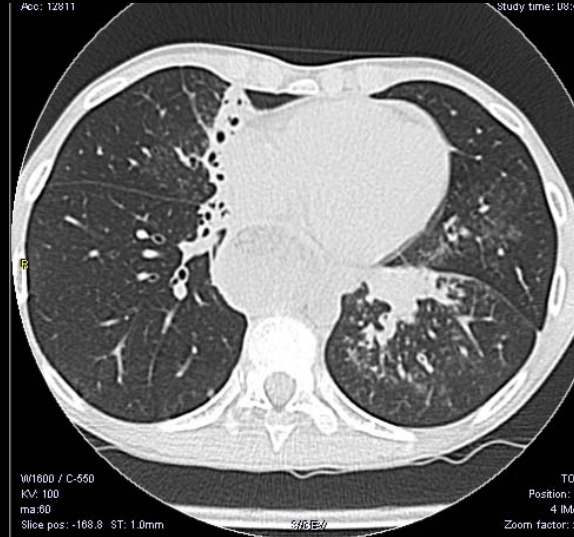
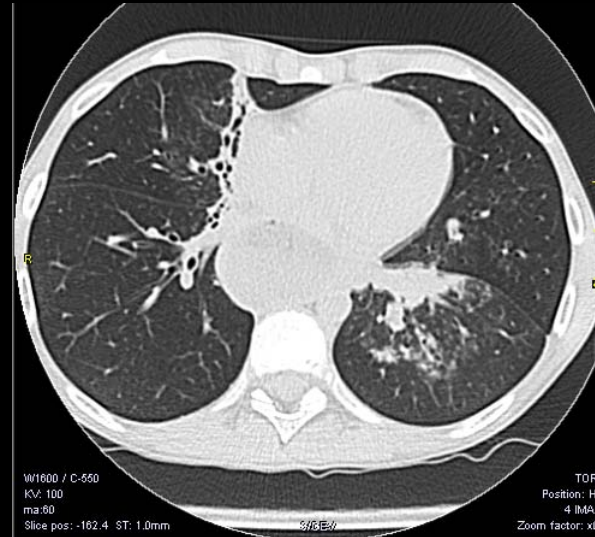
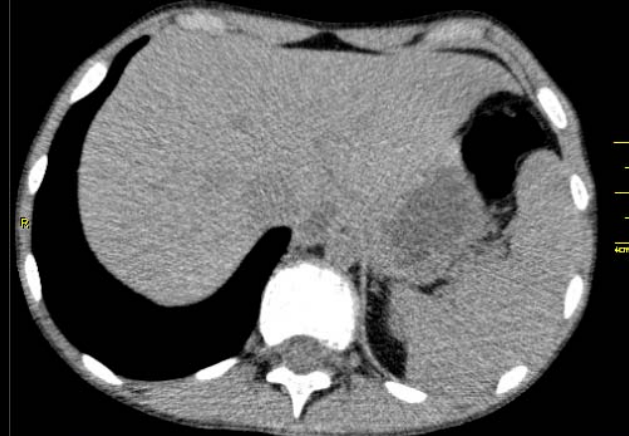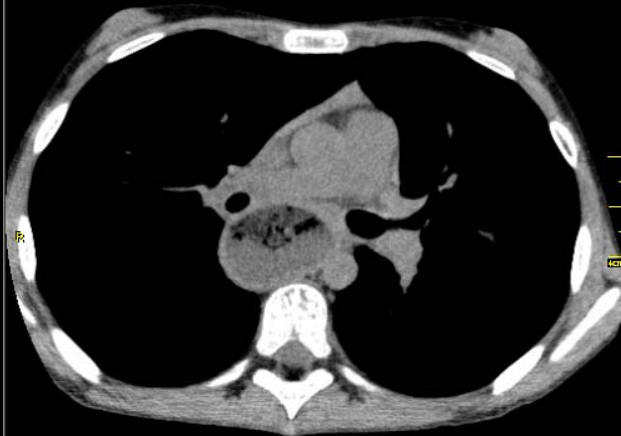

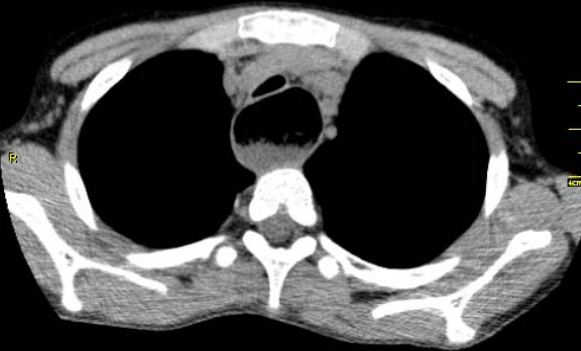
# Acalasia y bronquiectasias



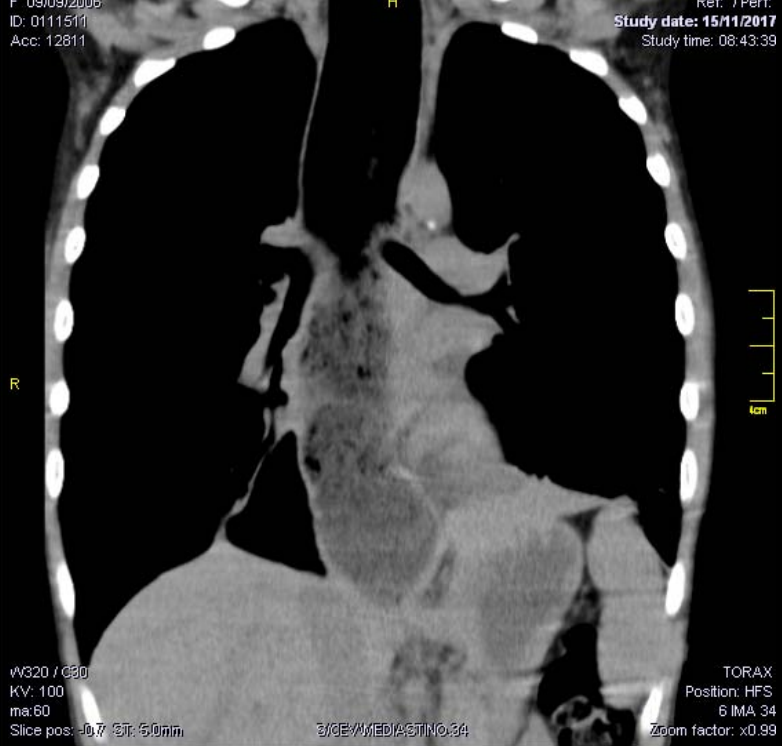


# Acalasia y bronquiectasias



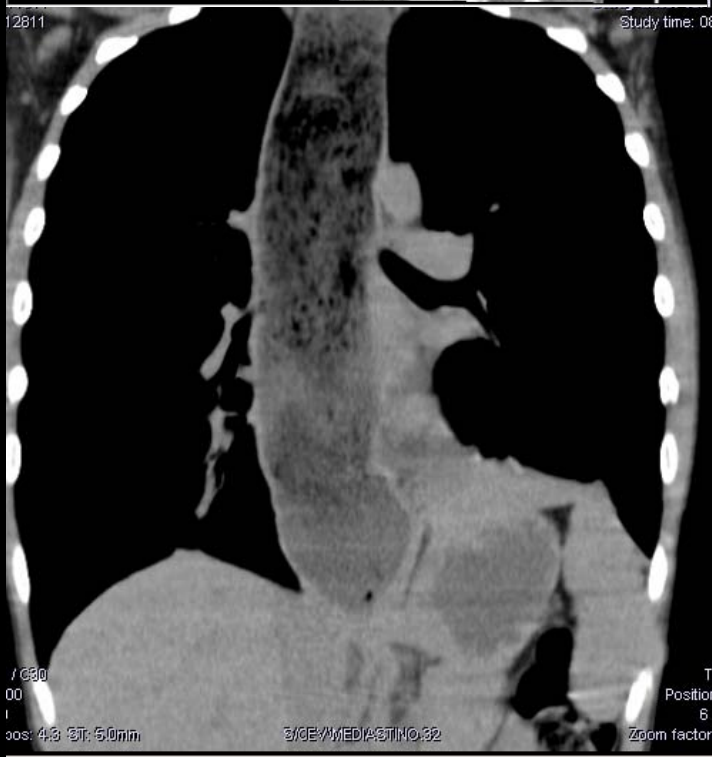
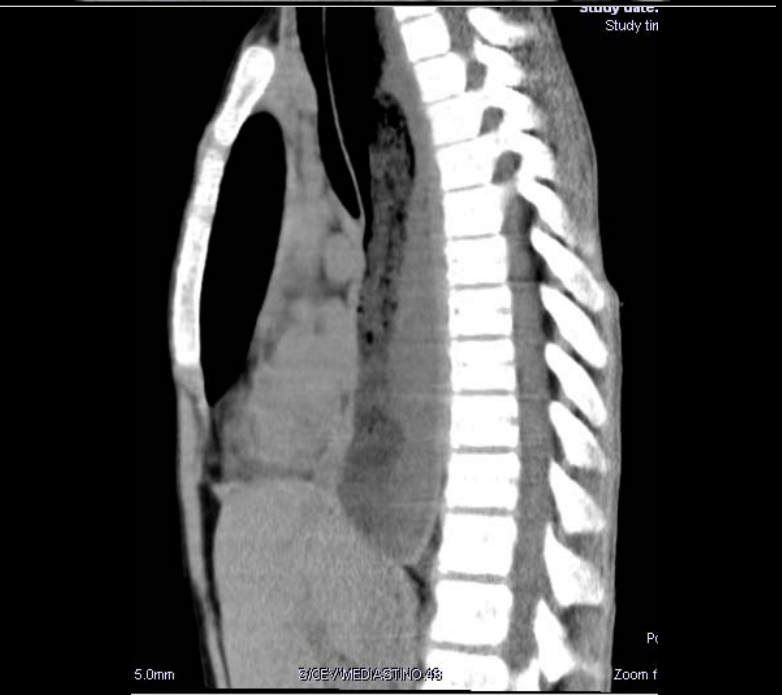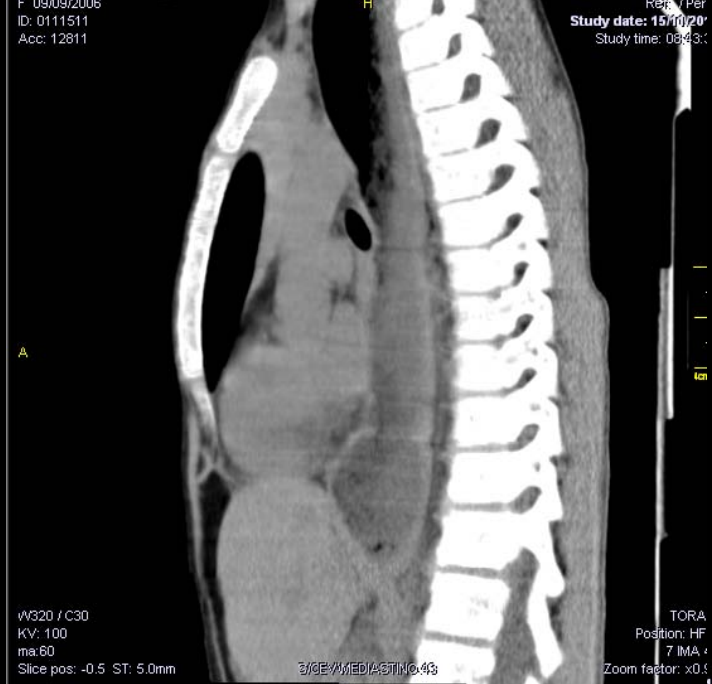F 09/09/2006  
ID: 0111511  
Acc: 12811

Ref: 7 Per:  
Study date: 15/11/2017  
Study time: 08:43:39

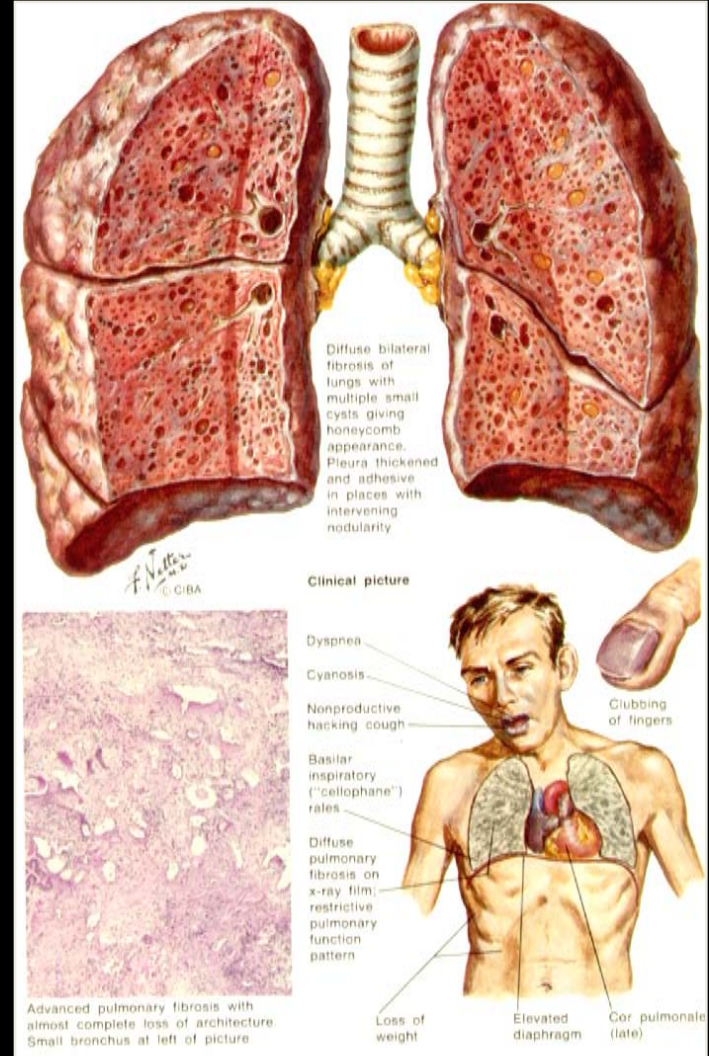
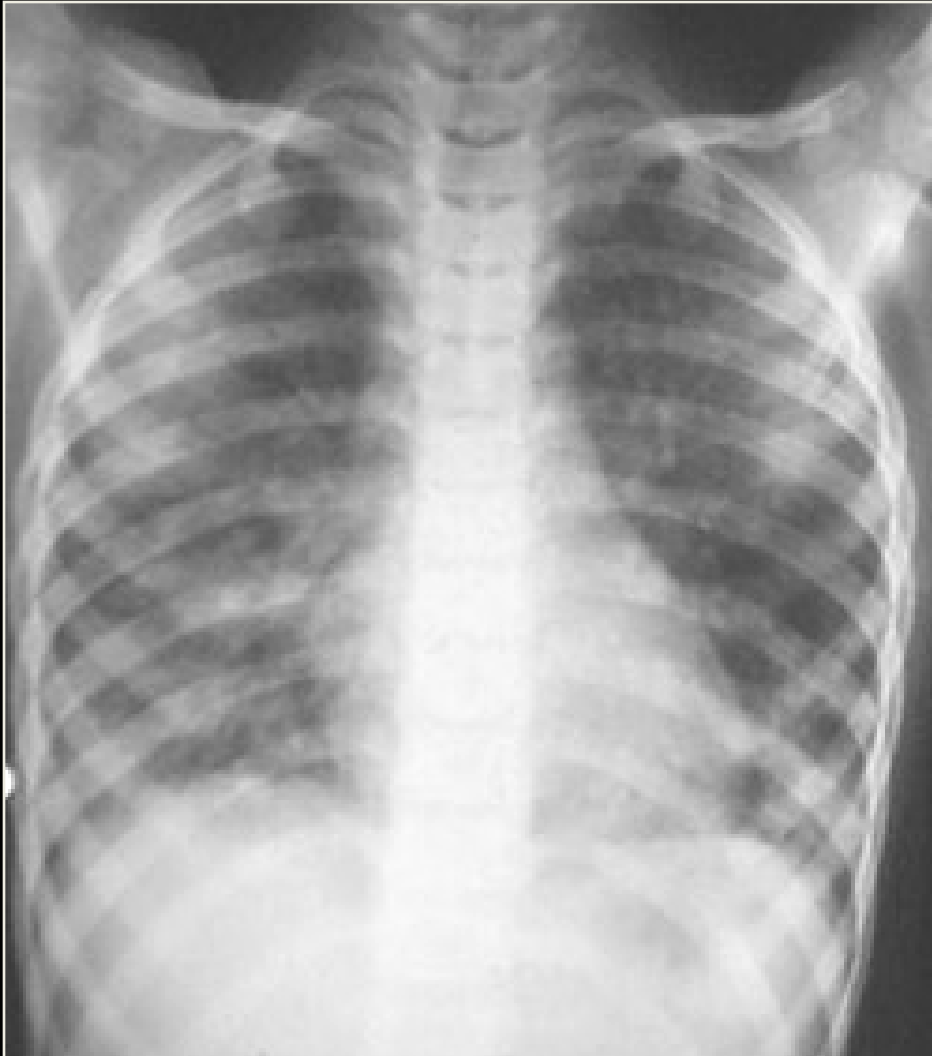

F 09/09/2006  
ID: 0111511  
Acc: 12811

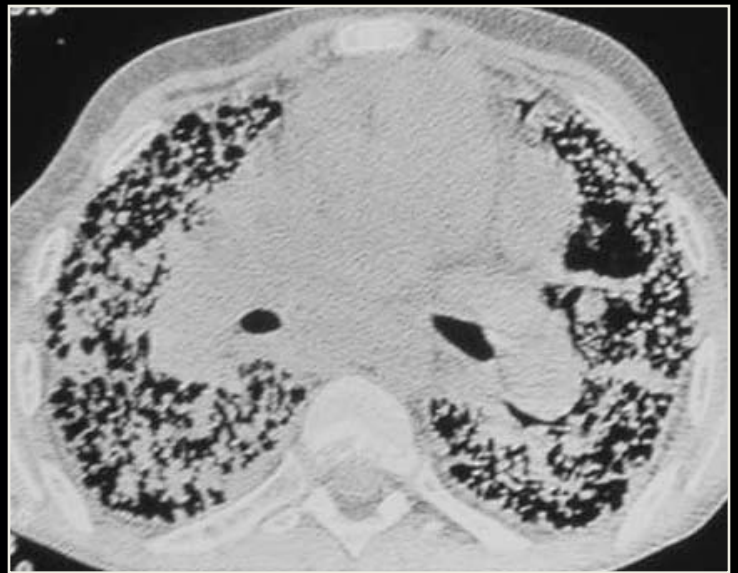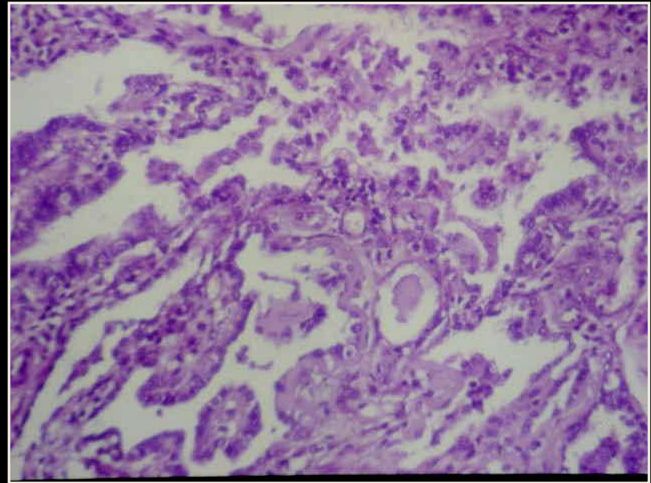
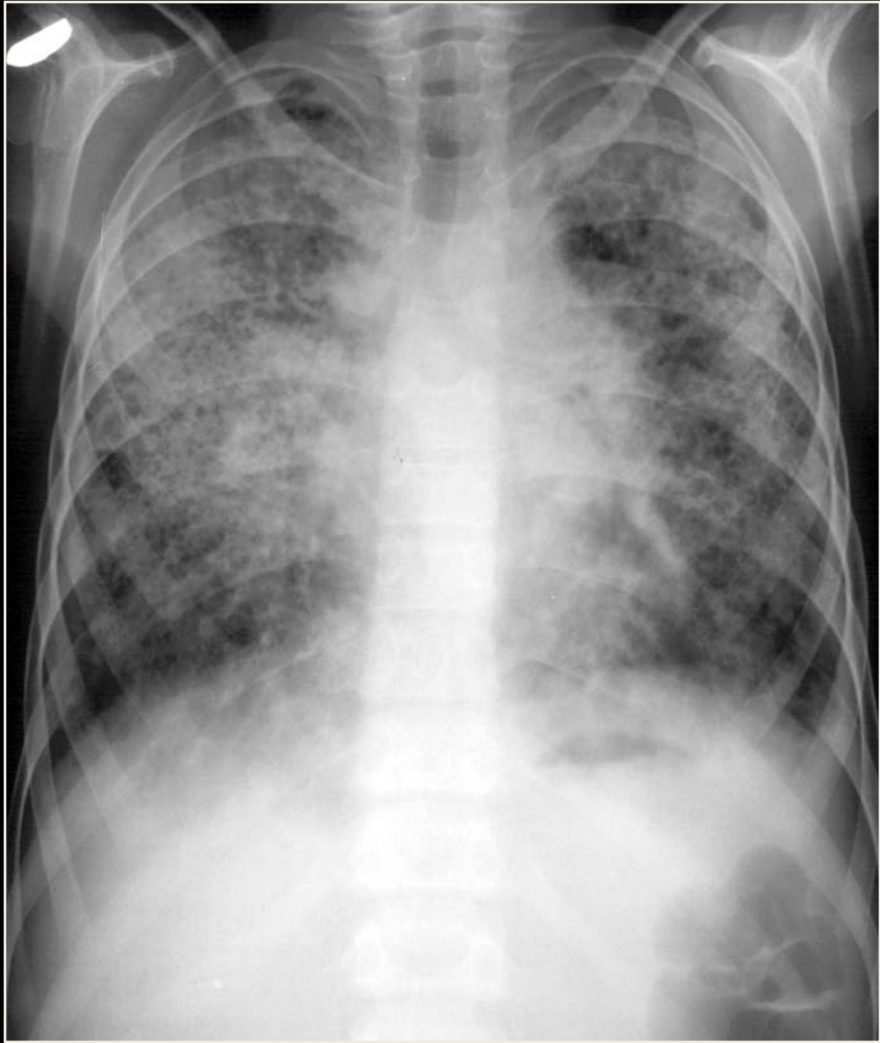
Ref: 7 Per:  
Study date: 15/11/2017  
Study time: 08:43:39

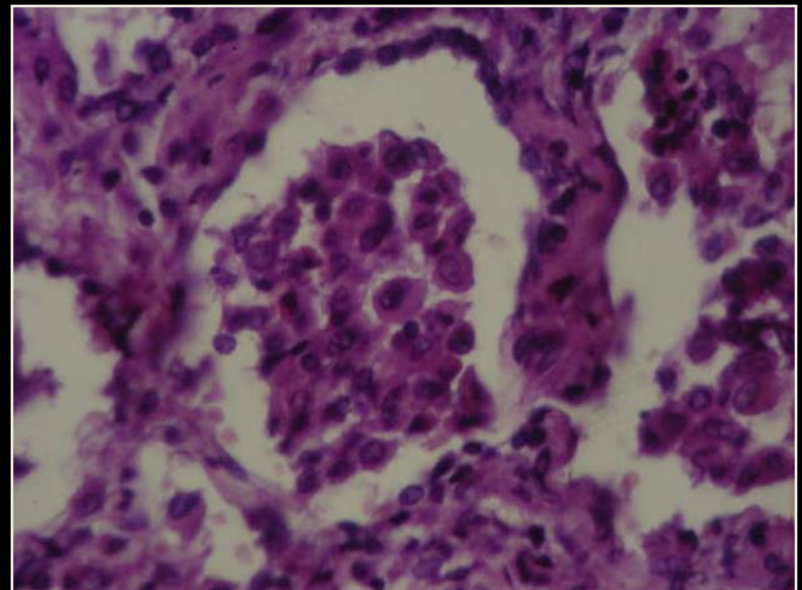
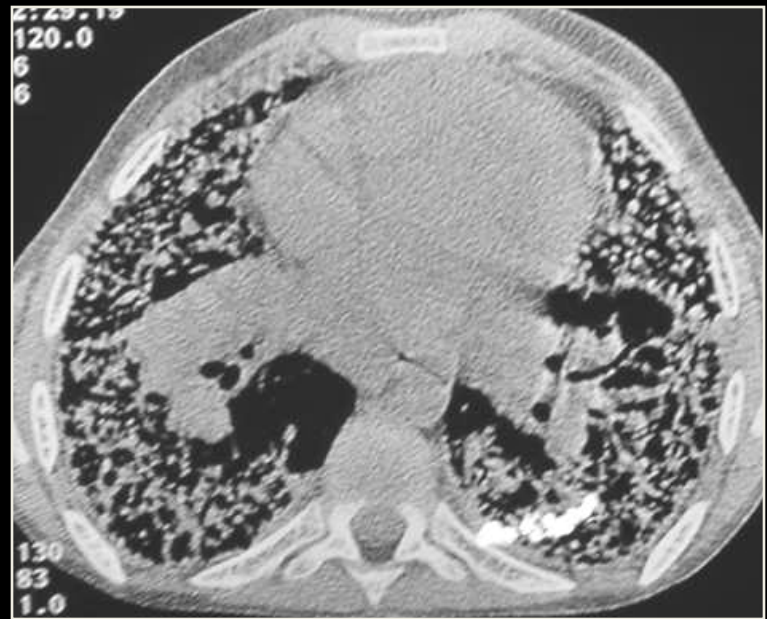
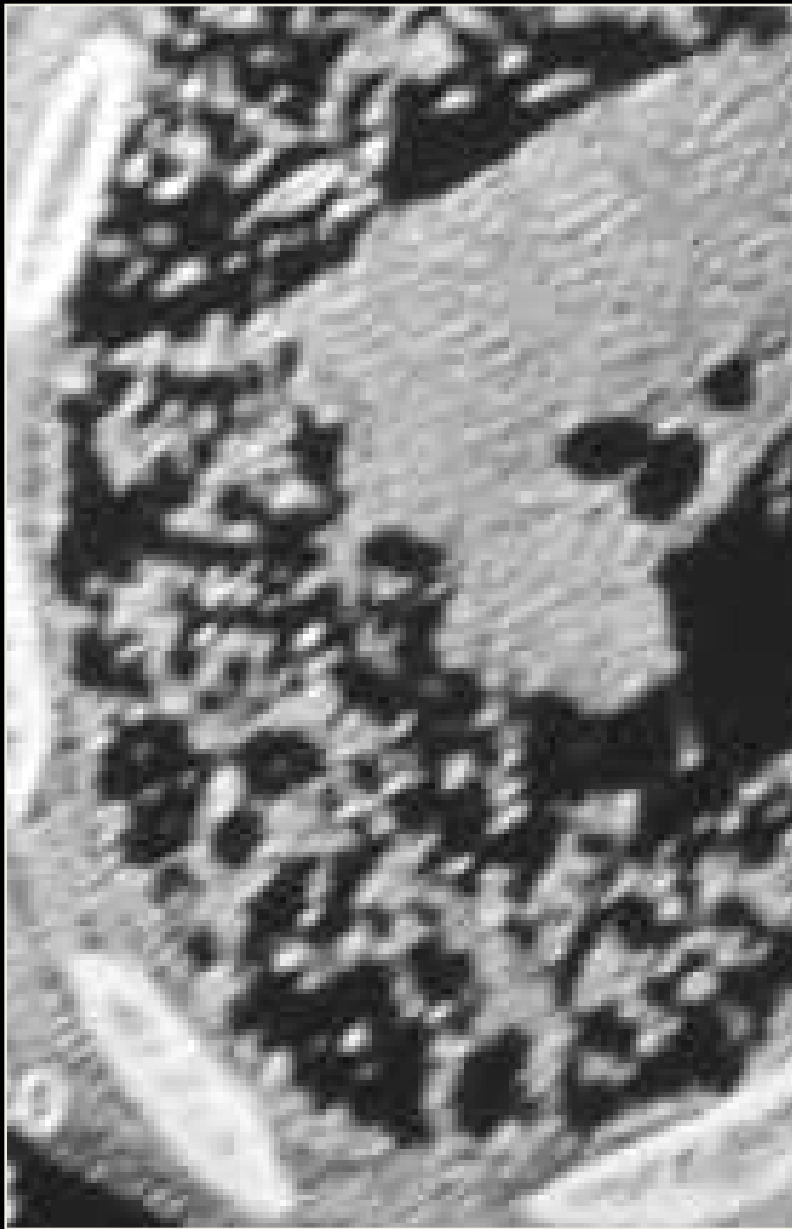


# 6 a fem. disnea

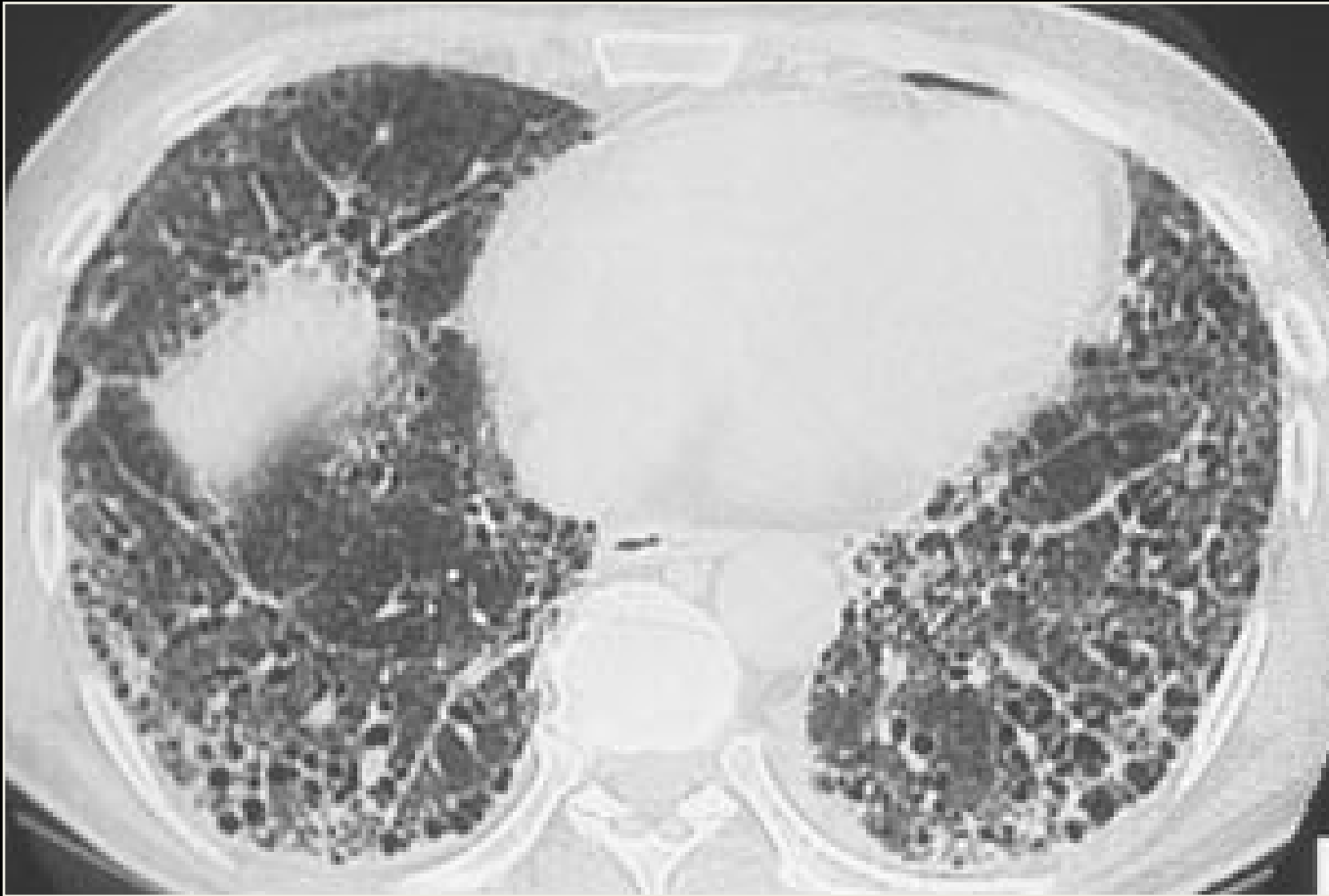







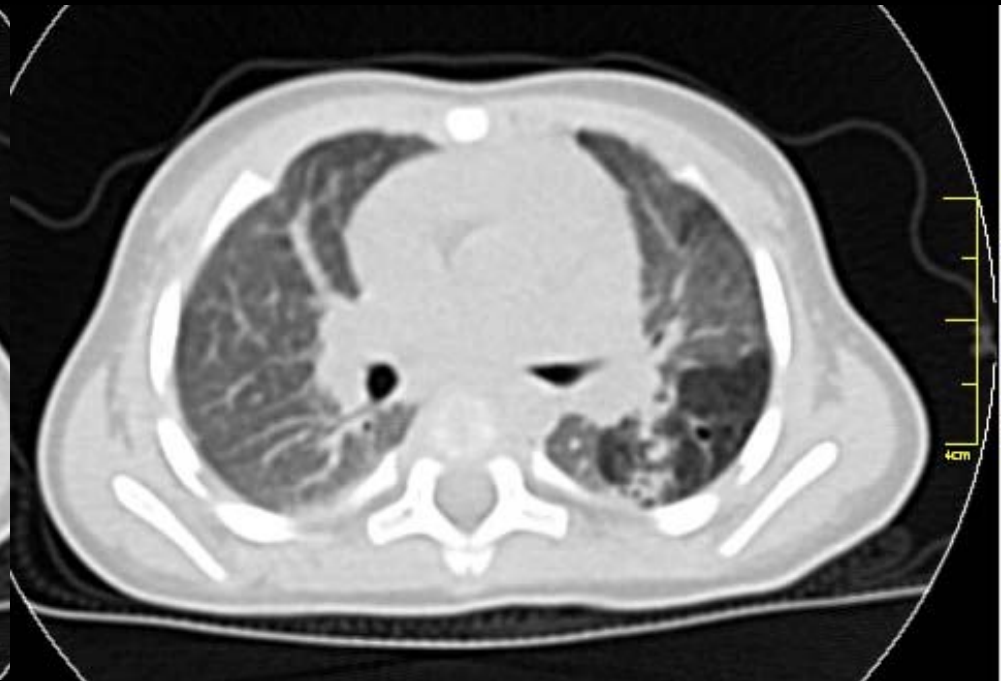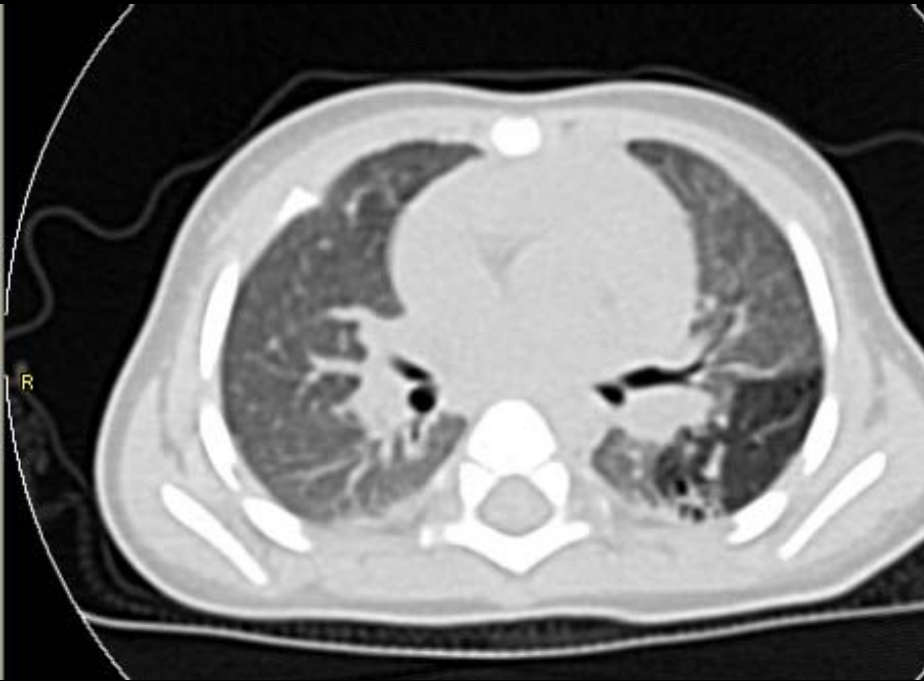# Fibrosis Pulmonar



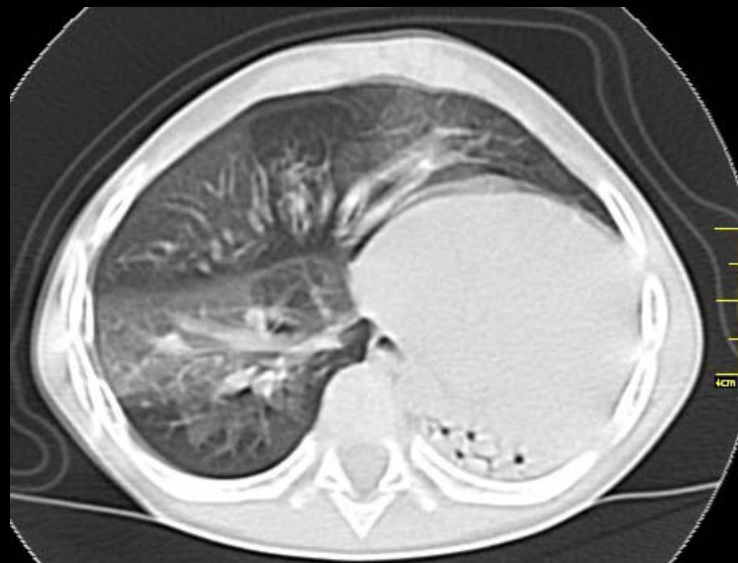
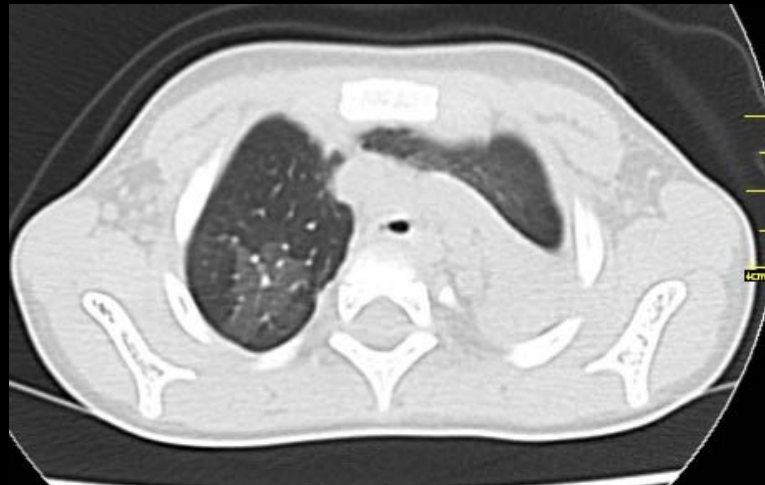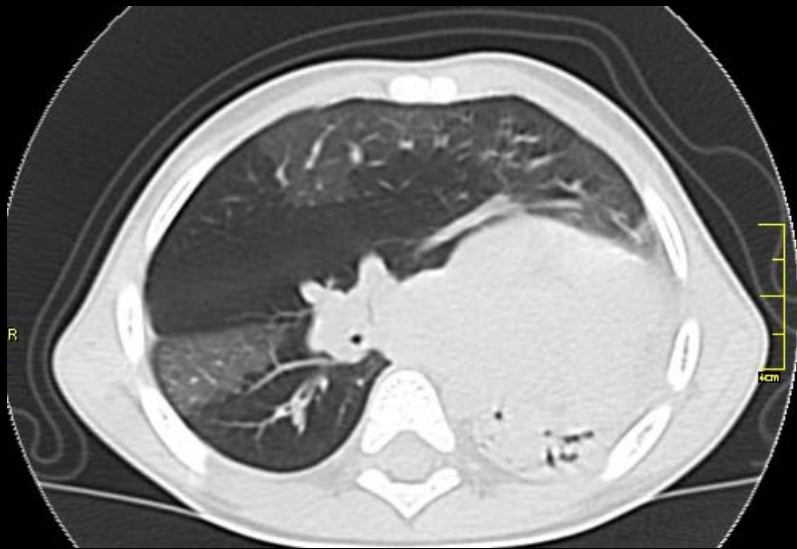From “traction bronchiectasis” to honeycombing in idiopathic pulmonary fibrosis: a spectrum of bronchiolar remodeling also in radiology?  
BMC Pulmonary Medicine 2016 16:87 Piciucci et Al



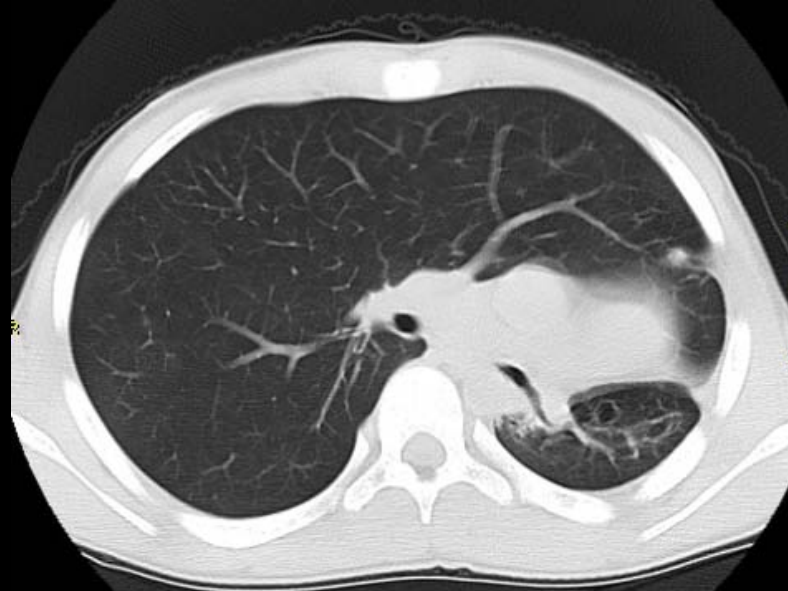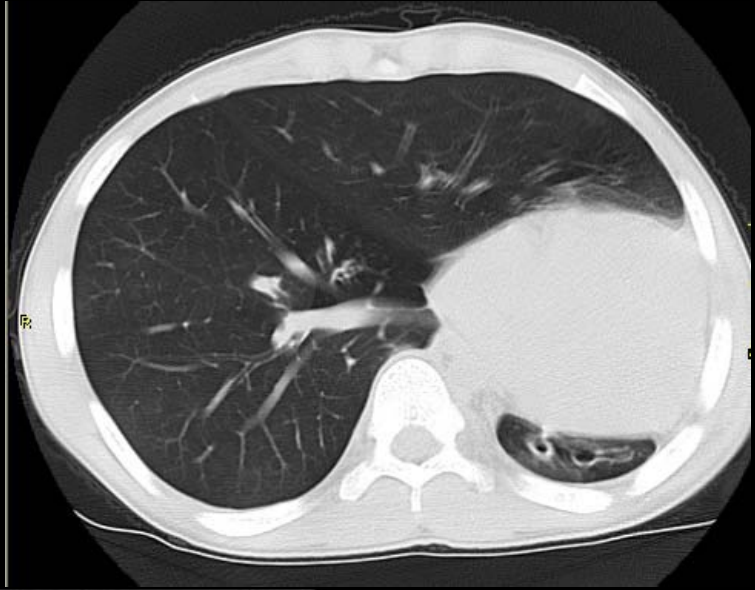
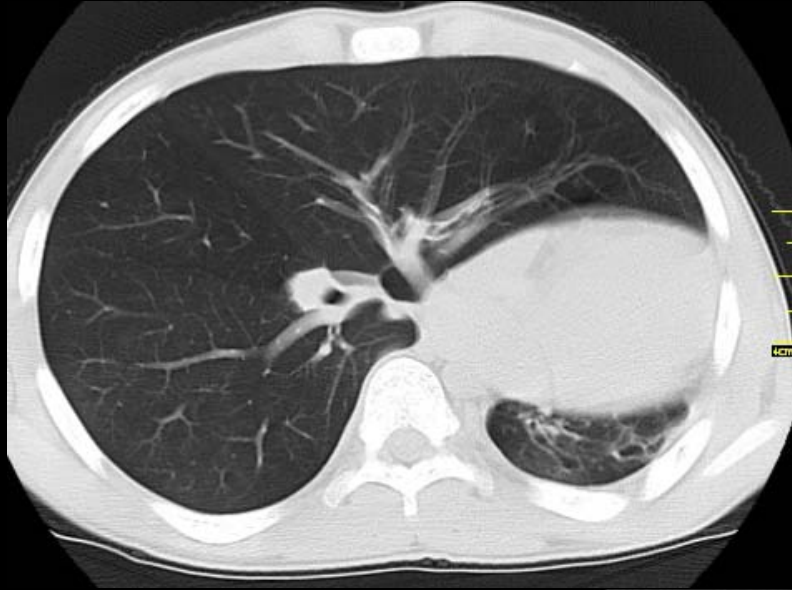
# Pos viral



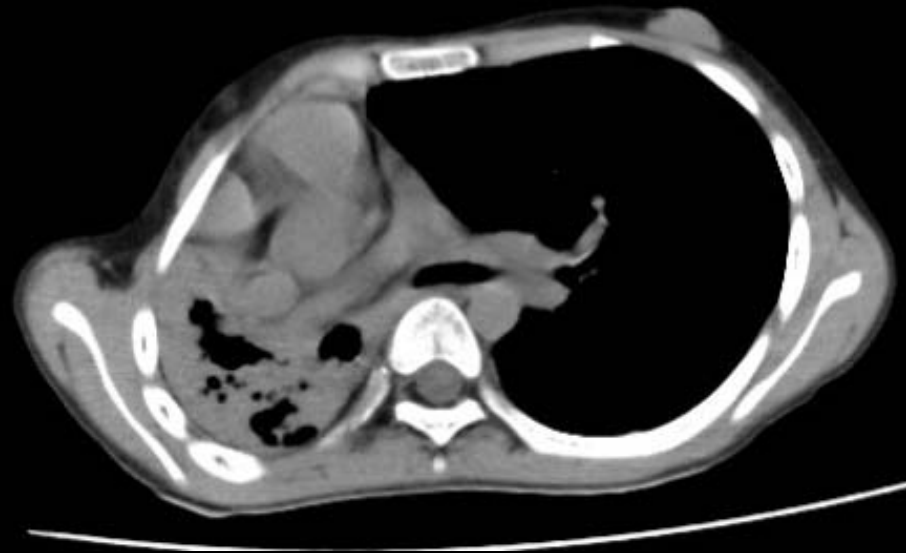
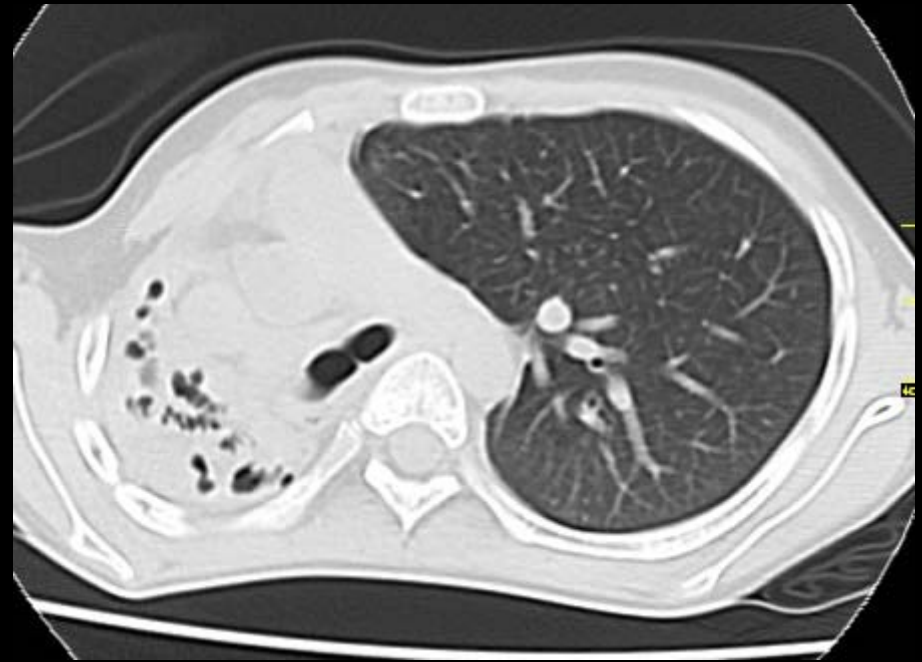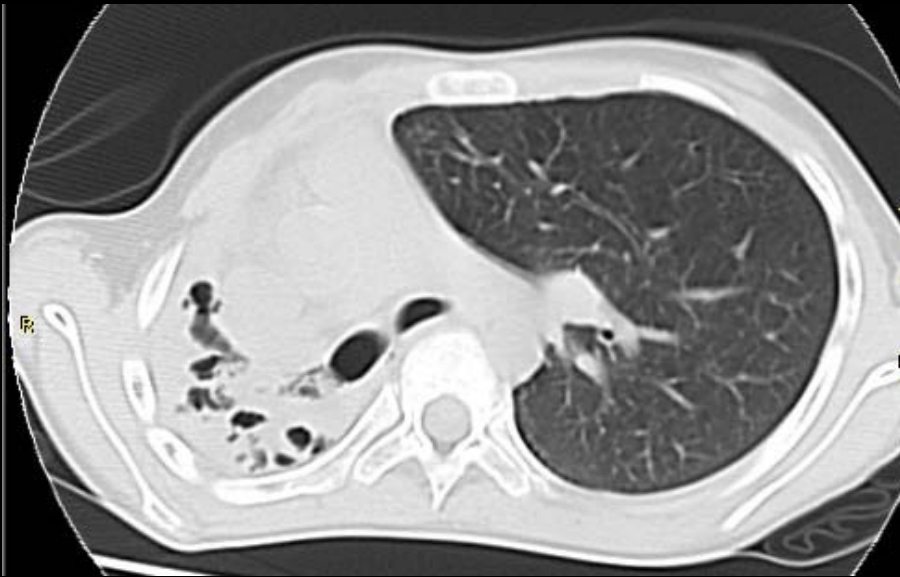
# Adenovirus



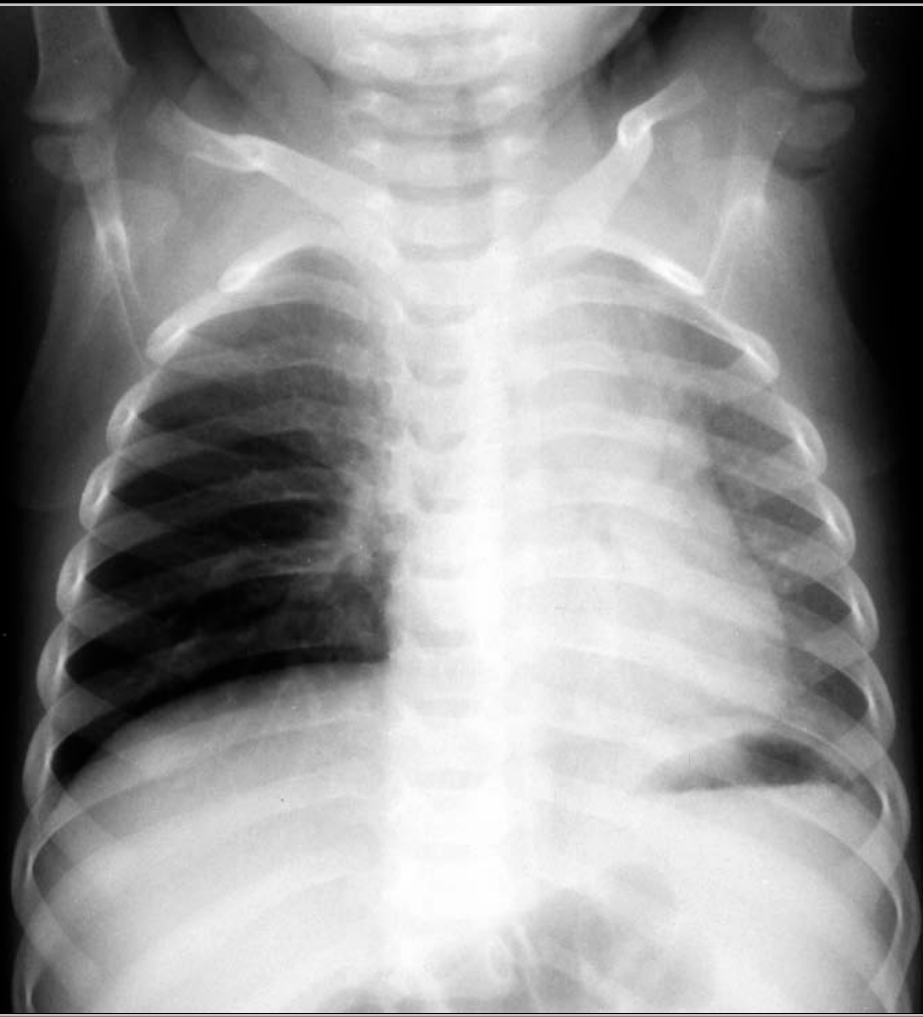# EPOC pos viral



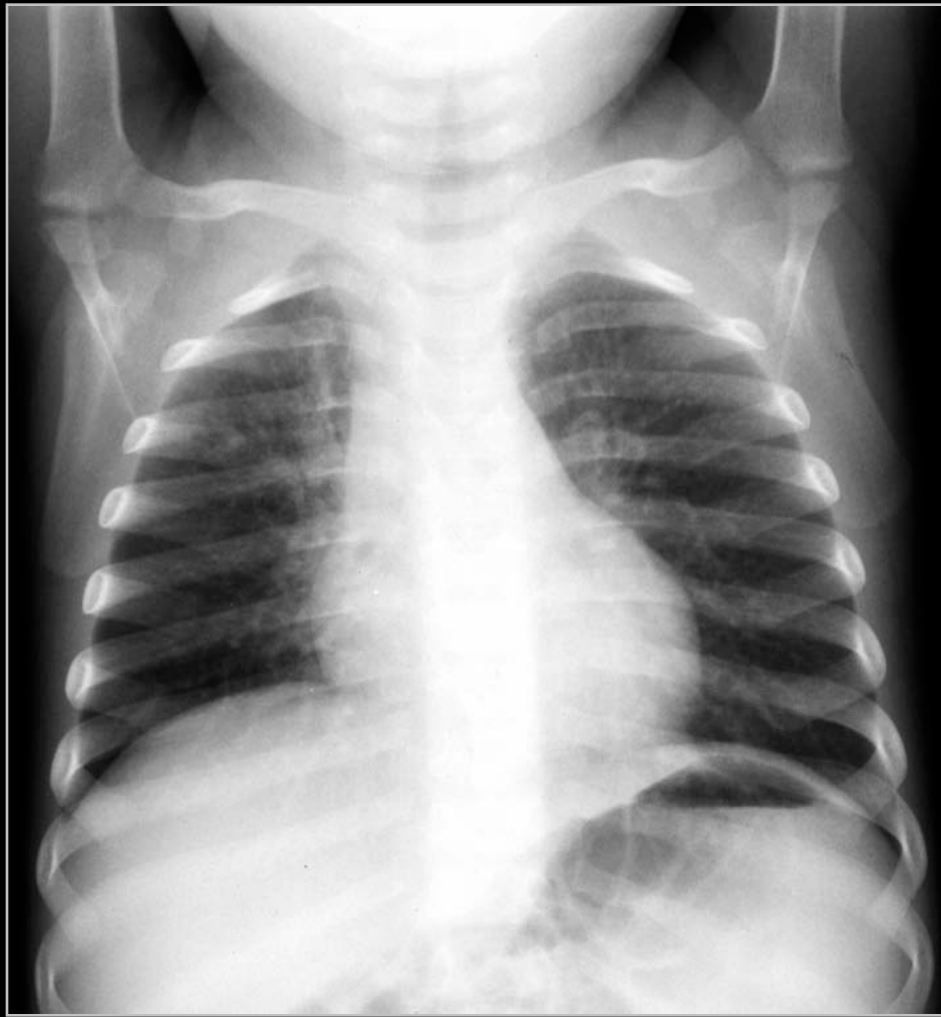# Swyer James





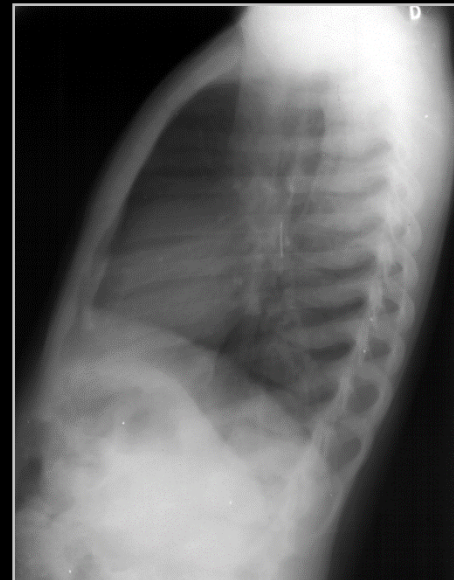
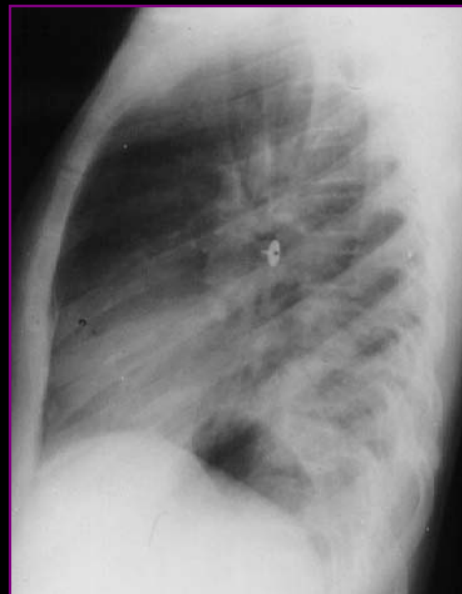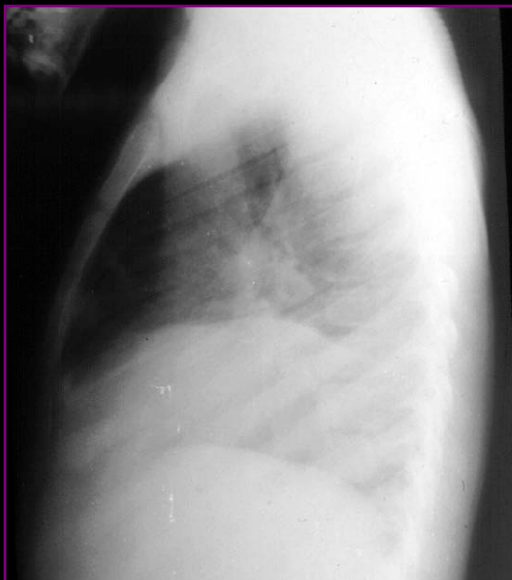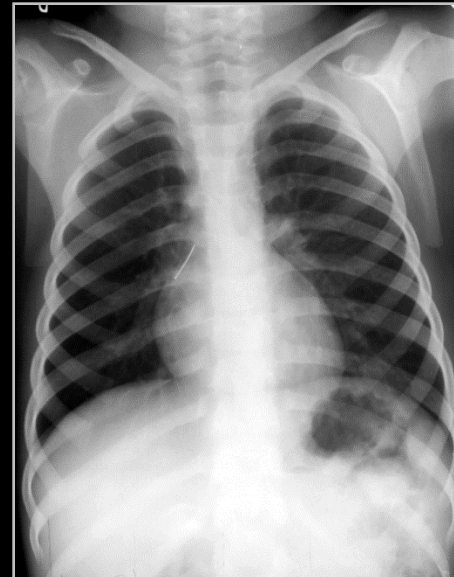
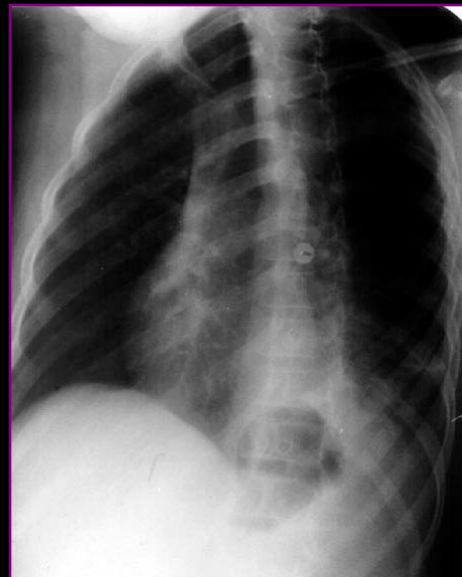
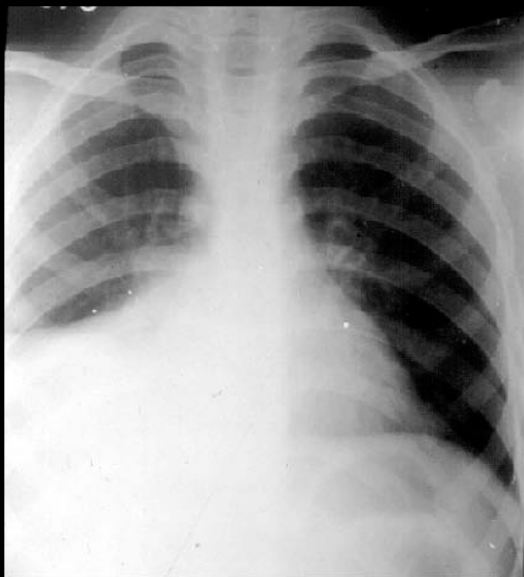


EXPIRACIÓN



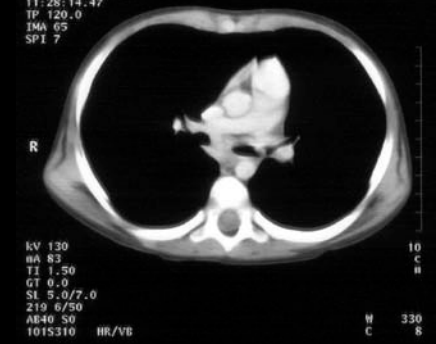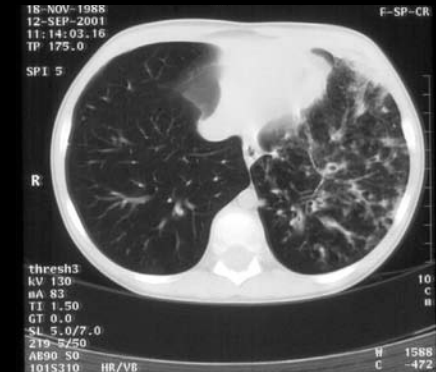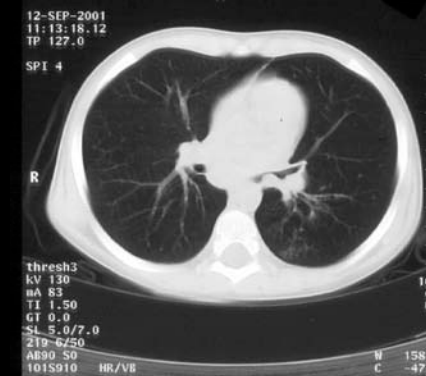
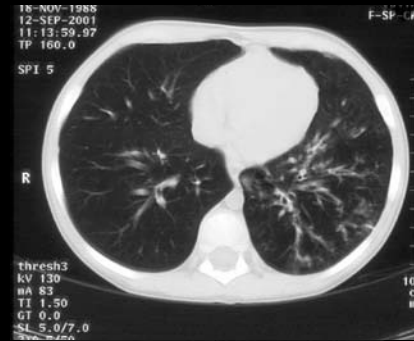
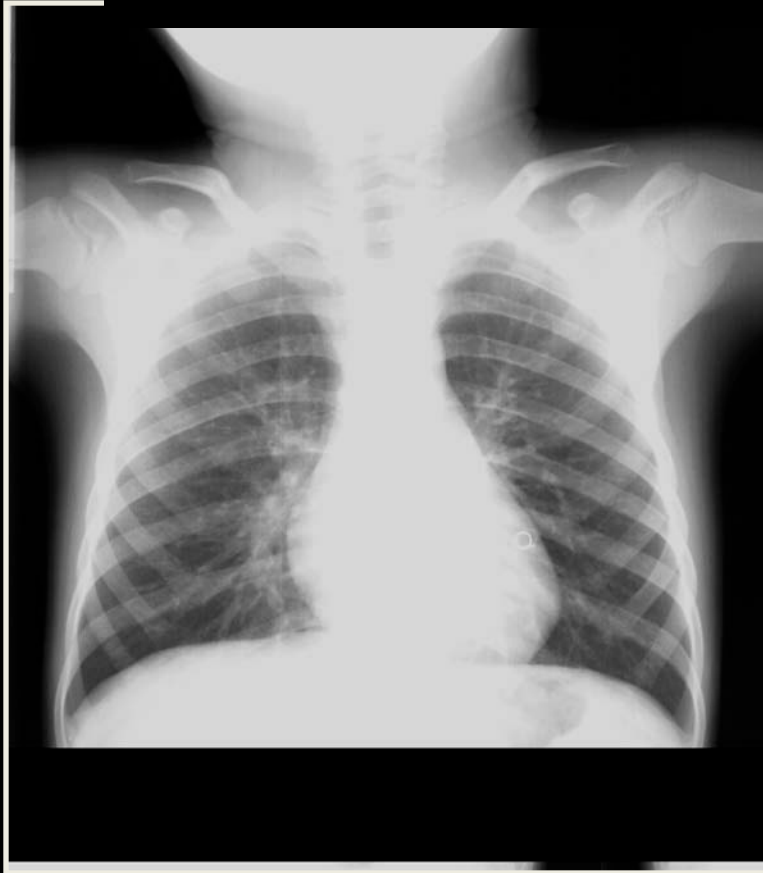INSPIRACIÓN

# Cuerpo Extraño

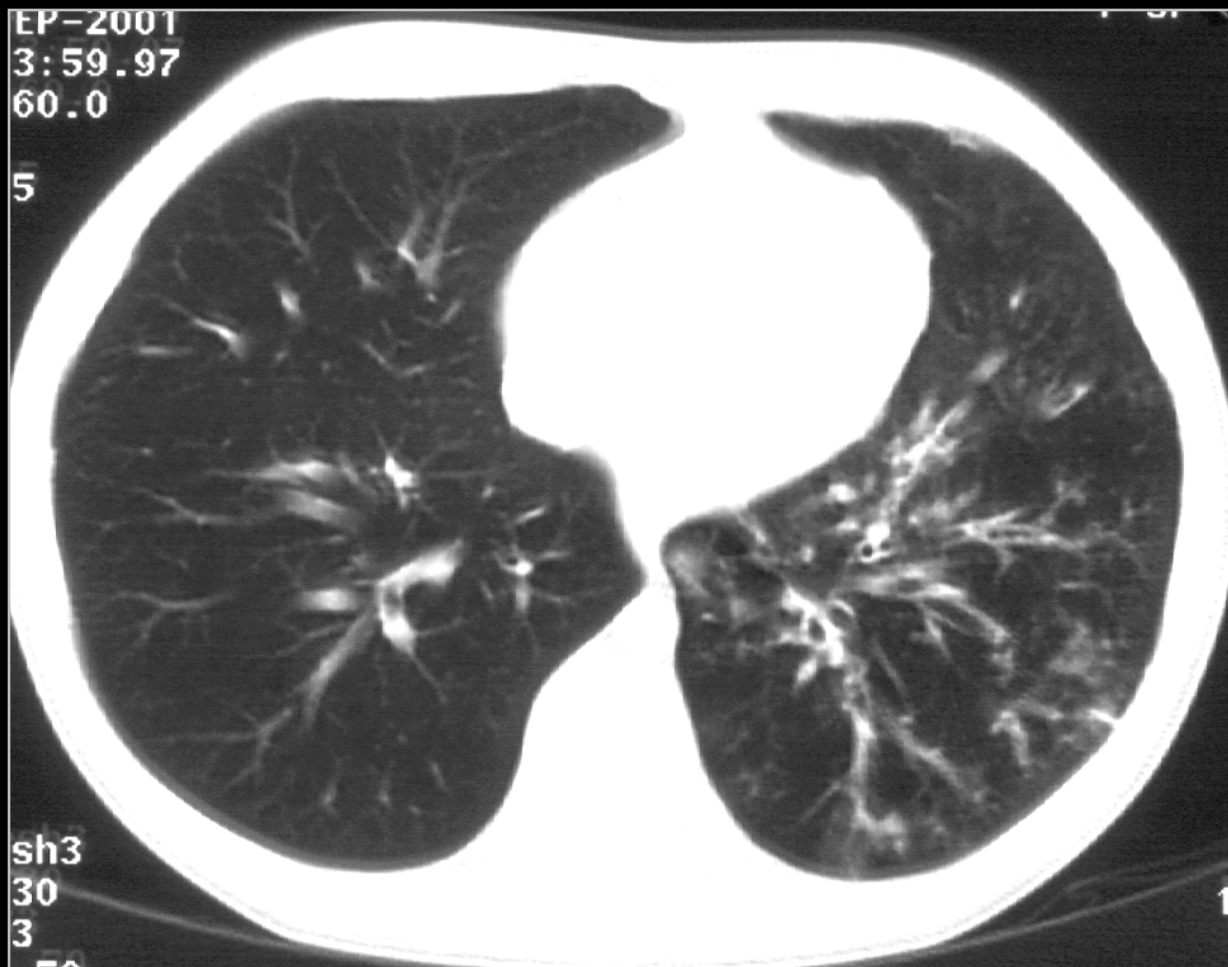




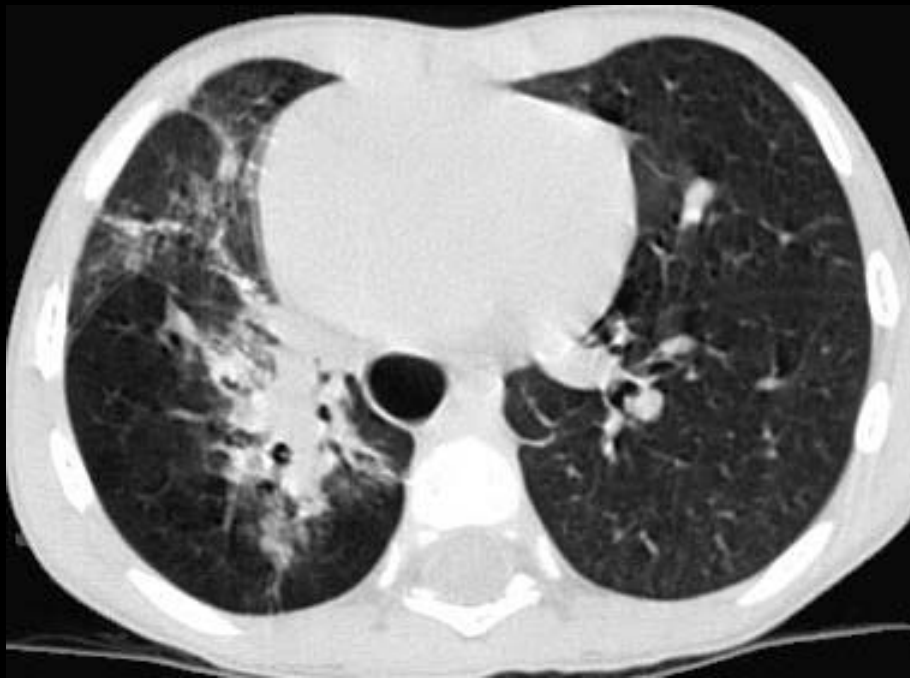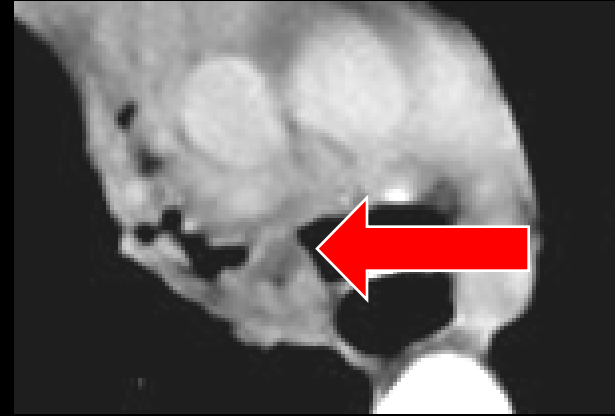
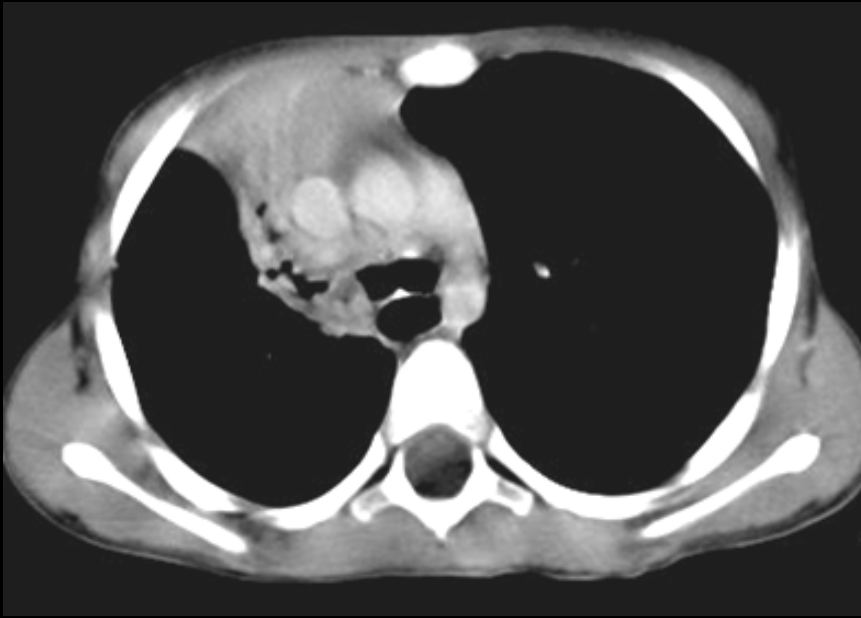
# Cuerpo Extraño endobronquial

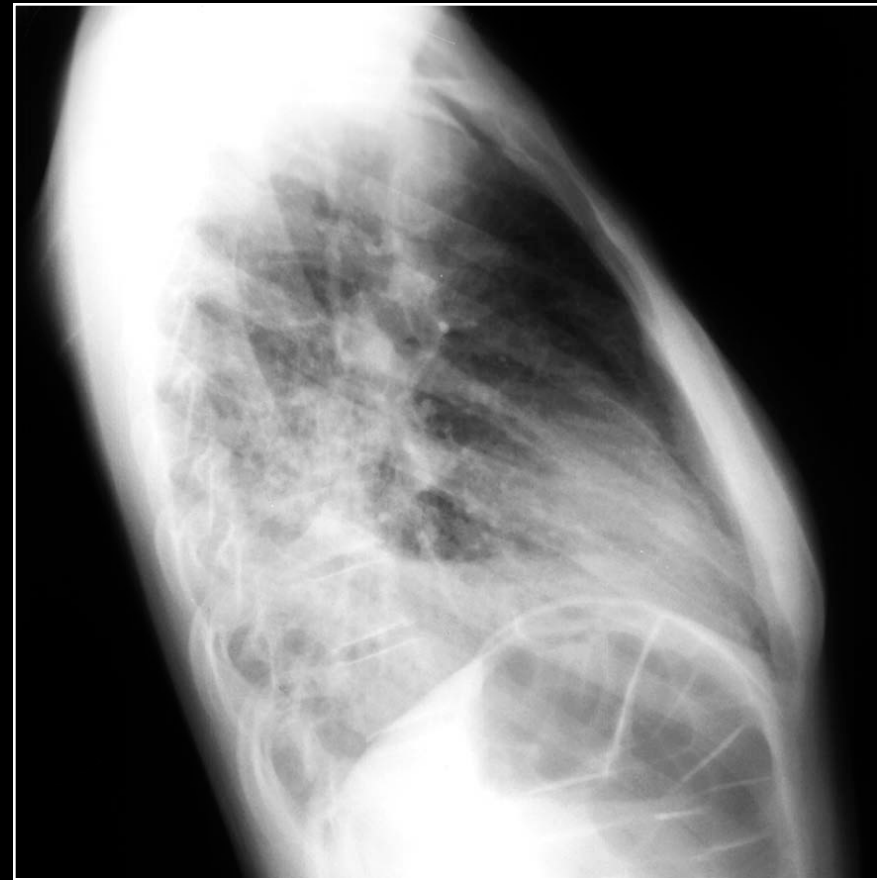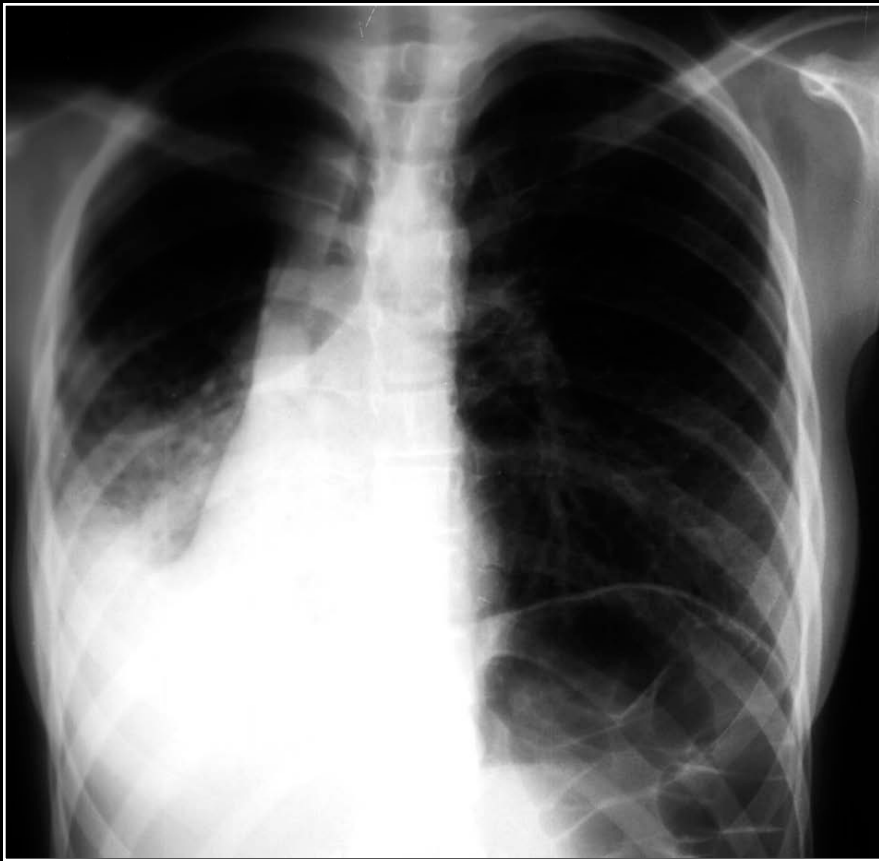


# Neumonía recurrente 7 a



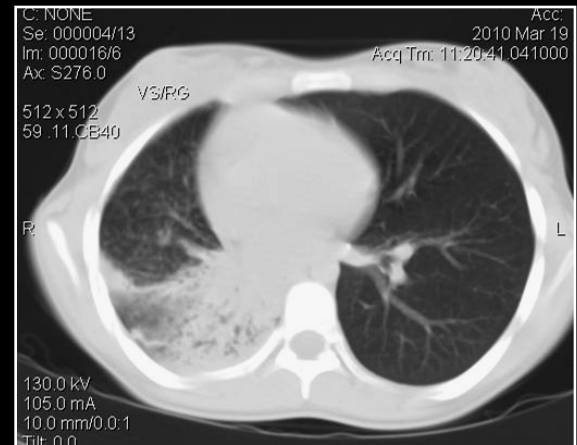
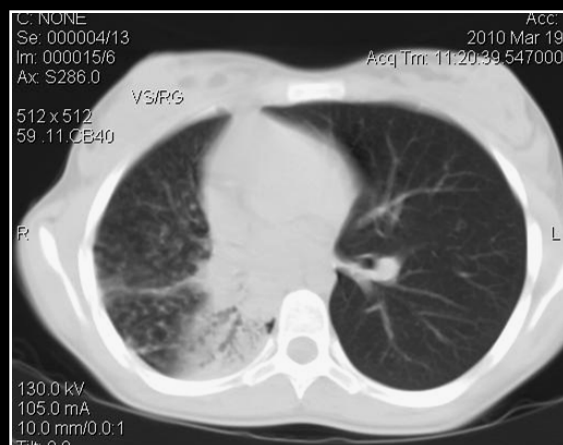
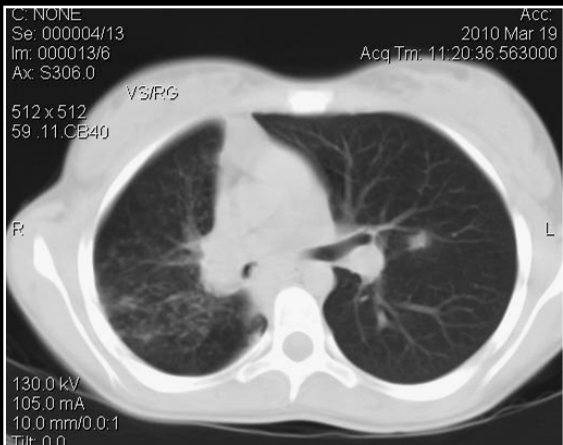
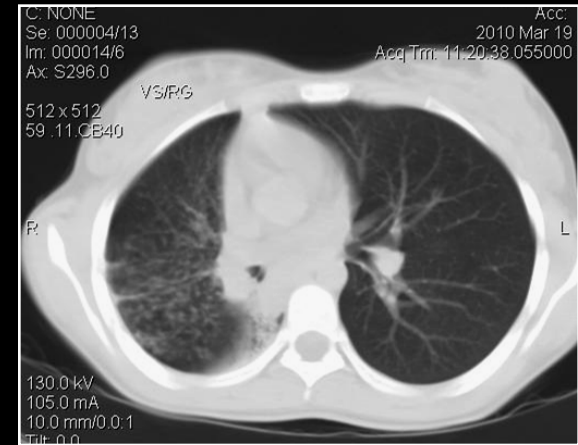
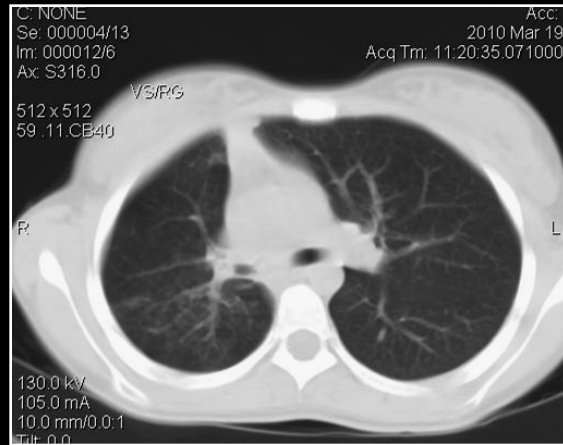
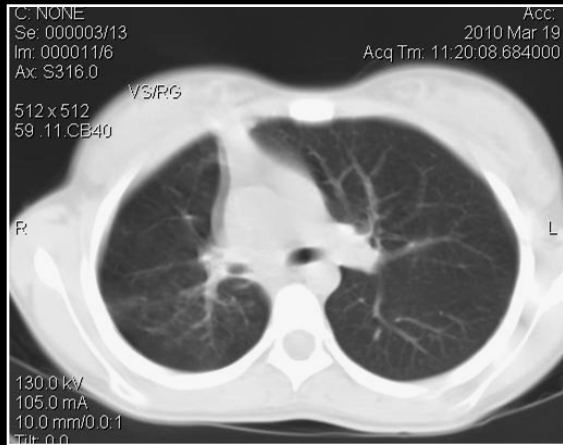
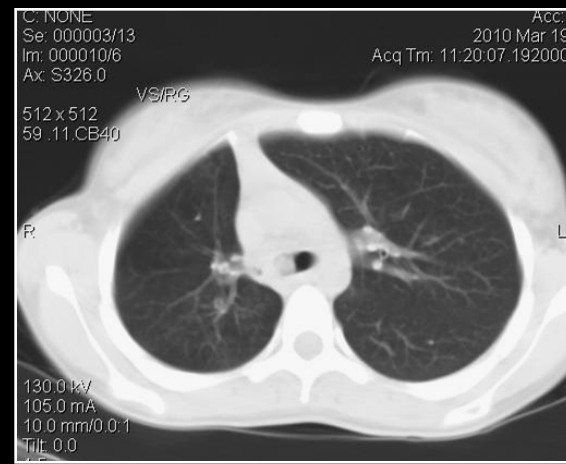
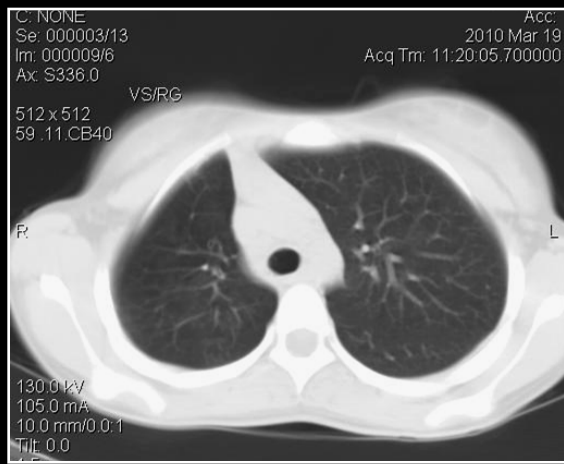
# Mani

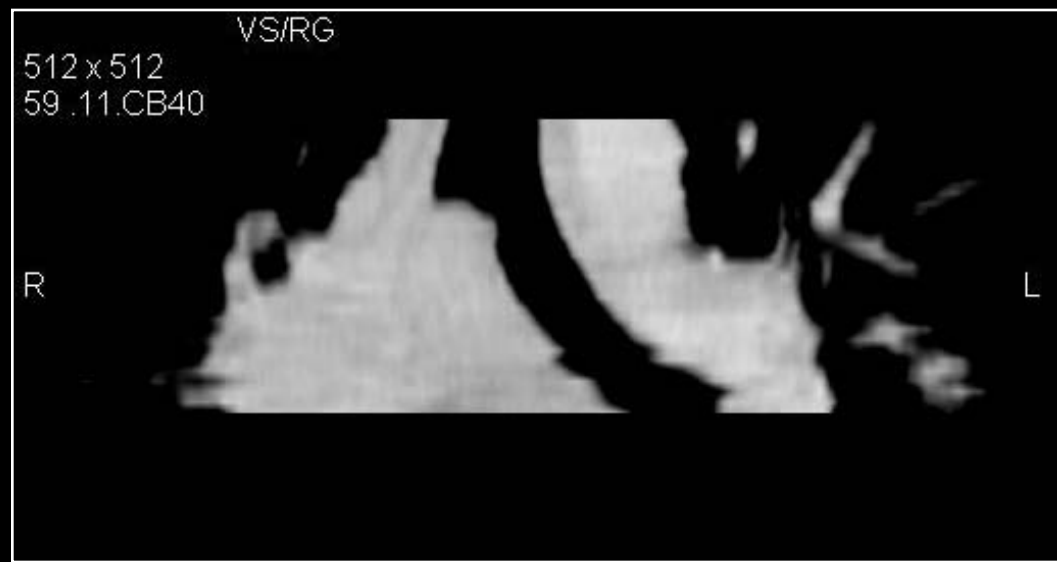
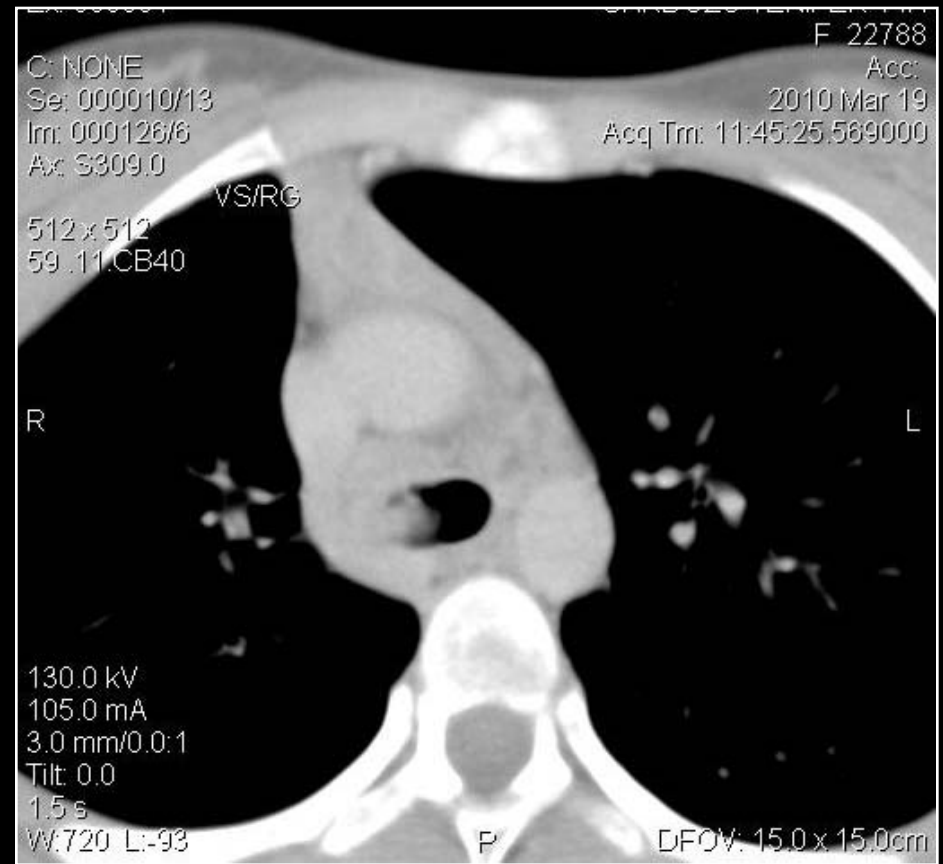
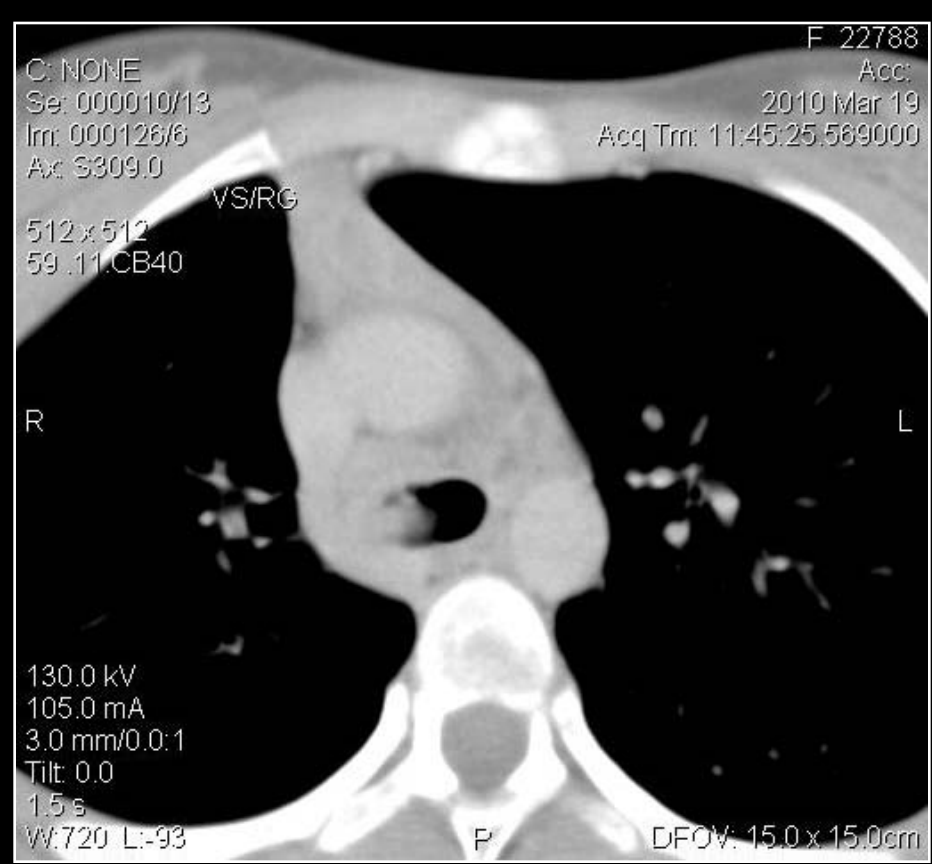




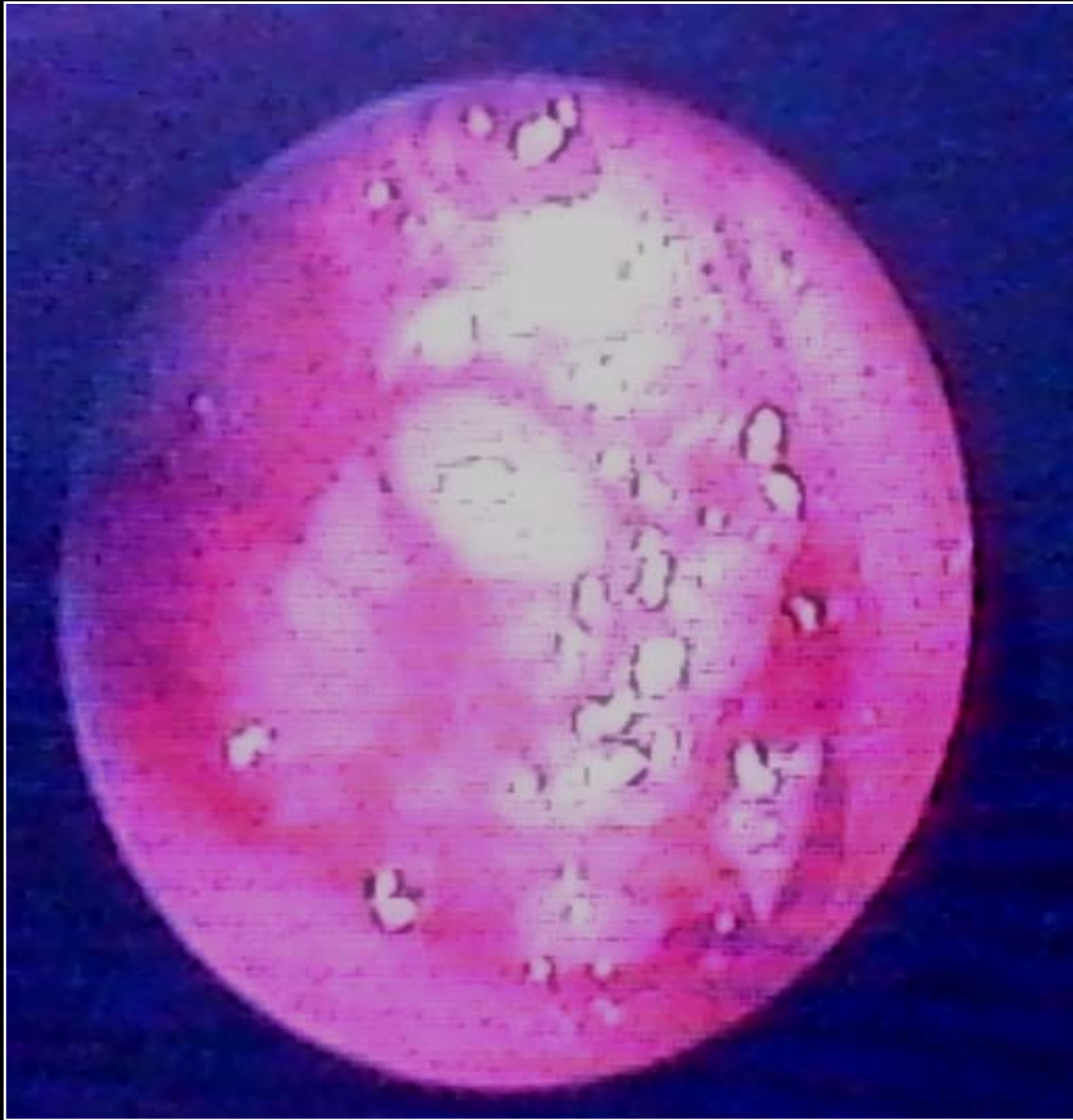
13 a Tos seca 6 meses de evolucion perdida de 13 Kg

15-03-2010





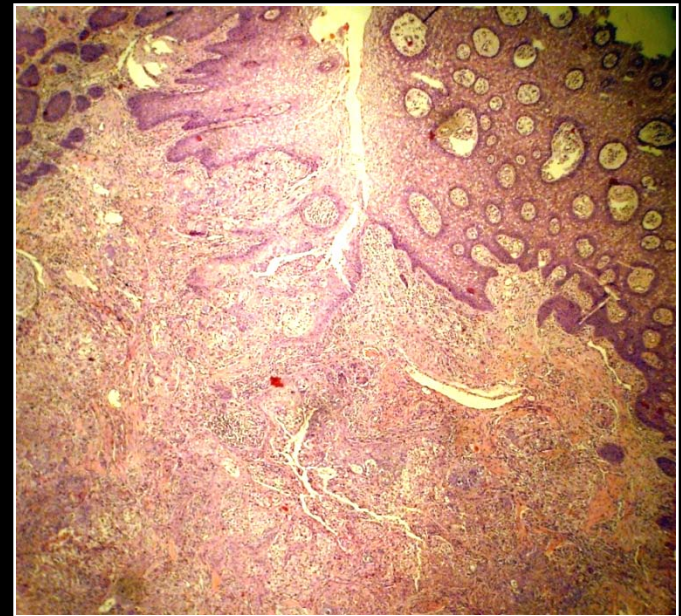




## Endoscopía

Masa ocupando luz del bronquio fuente, de colorido pardo con áreas blanquecinas y configuración nodular.

## Microscopía



CARCINOMA MUCOEPIDERMOIDE

# Primary Lung and Large Airway Neoplasms in Children

## Current Imaging Evaluation with Multidetector Computed Tomography

Behrang Amini, MD, PhD<sup>a</sup>, Steven Y. Huang, MD<sup>a</sup>,  
Jason Tsai, MD<sup>b</sup>, Marcelo F. Benveniste, MD<sup>a</sup>,  
Hector H. Robledo, MD<sup>c</sup>, Edward Y. Lee, MD, MPH<sup>d,e,\*</sup>

### KEYWORDS

- Multidetector computed tomography (MDCT) • Primary lung neoplasm • Primary airway neoplasm
- Radiation dose • Pediatric patients

### KEY POINTS

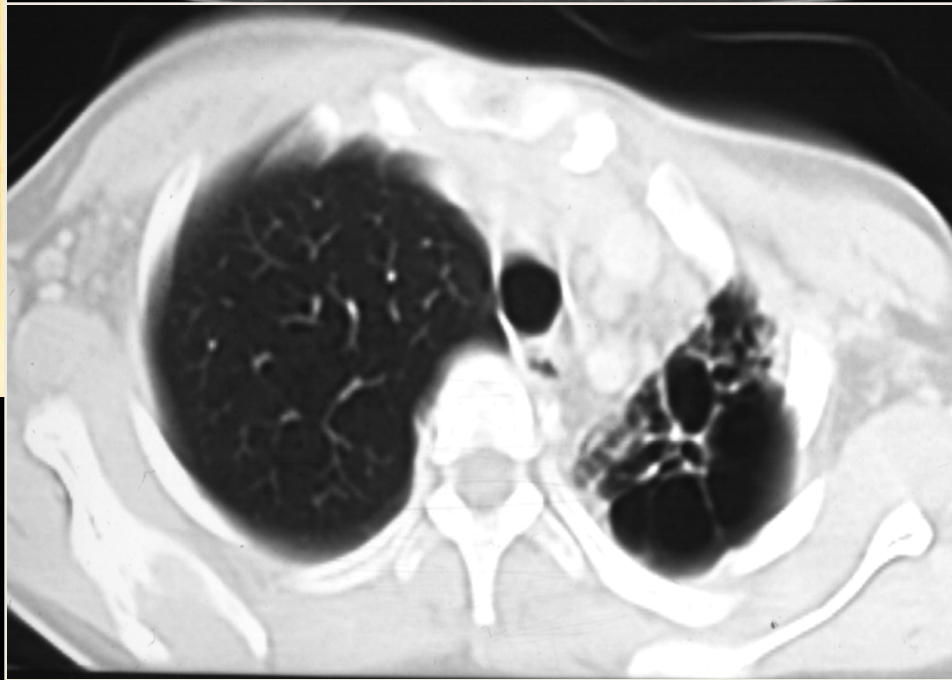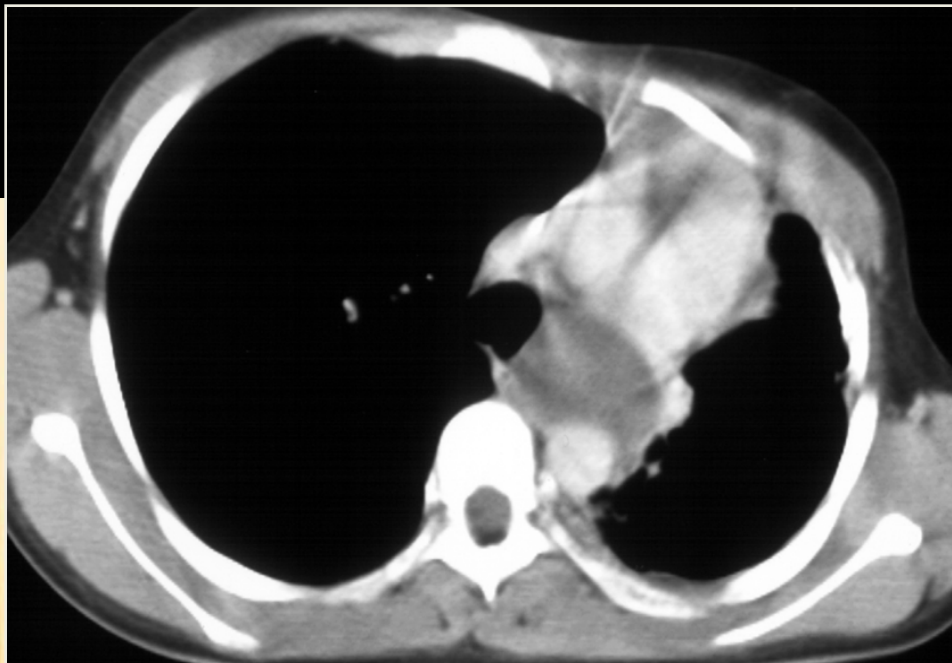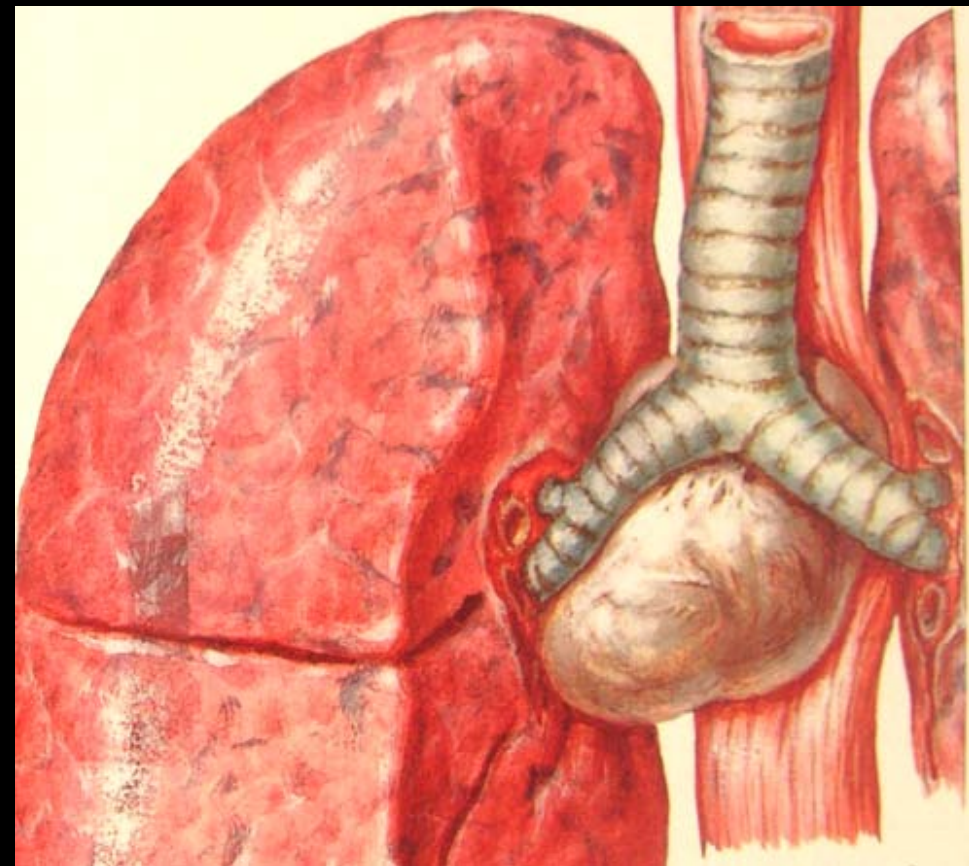
- The relative rarity of primary neoplasms of the lung and large airway may lead to a low index of suspicion for these lesions, with subsequent delay in achieving a correct diagnosis and initiating effective treatment.
- In the case of malignant neoplasms, this delay can adversely affect prognosis by allowing progression of disease to an advanced stage.
- Multidetector computed tomography (MDCT), with its improved efficiency and diagnostic capability compared with single-detector computed tomography, offers an important noninvasive imaging modality for confirmation and further characterization of these lesions in pediatric patients.
- Clear understanding of the proper MDCT techniques and the MDCT imaging appearance of primary lung and airway neoplasms aids in accurate diagnosis and thus contributes to optimal pediatric patient care.

### INTRODUCTION

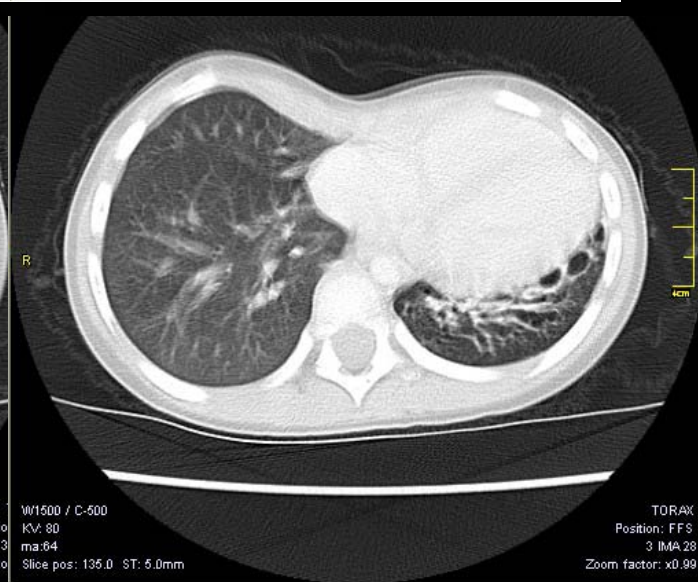
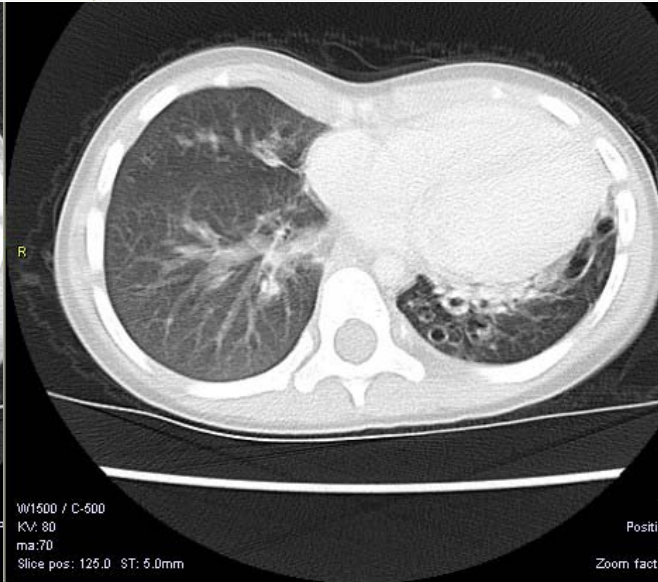
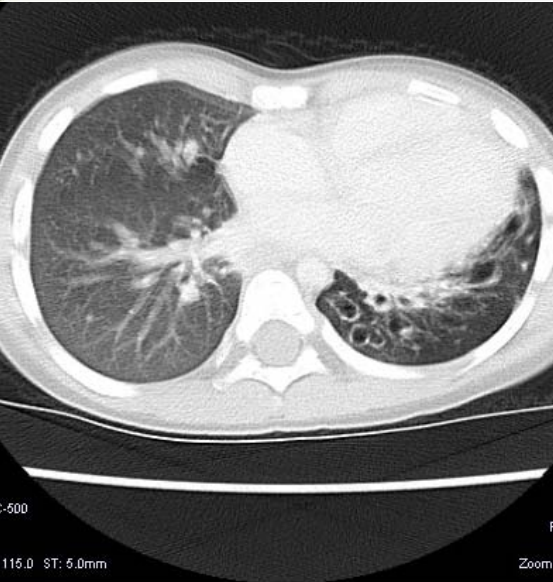
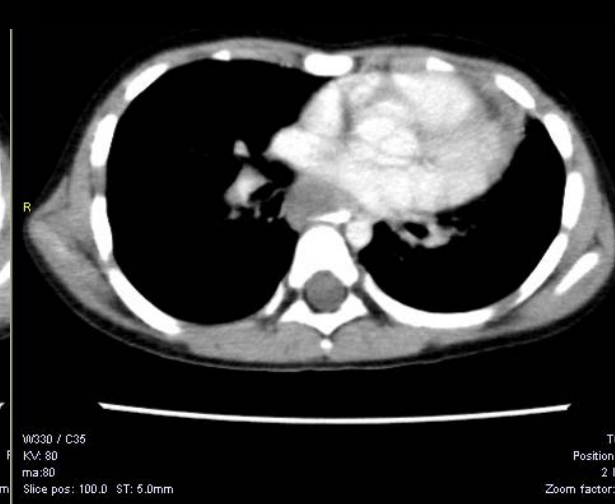
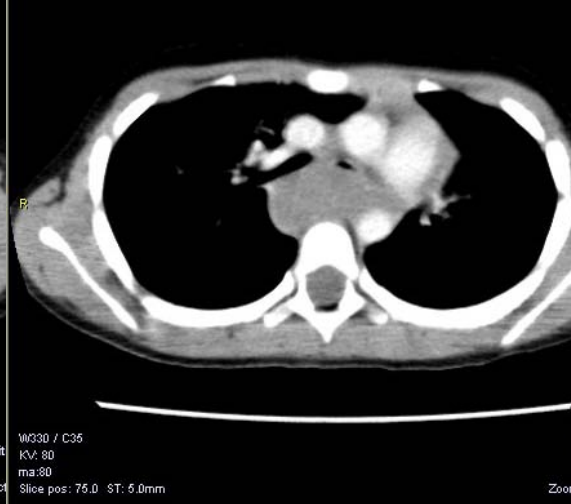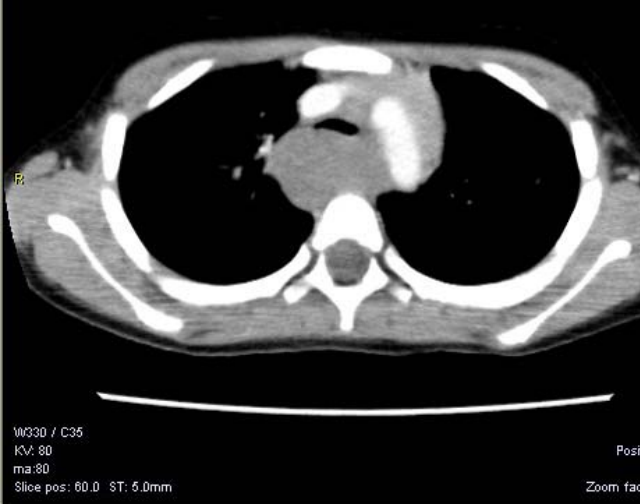Primary malignant neoplasms of the lung and large airway represent 0.2% of all malignancies in the pediatric population.<sup>1</sup> Such low incidence often results in a low index of suspicion for these lesions, and the correct diagnosis is often missed or delayed. Early and accurate diagnosis is particularly important in cases of malignant tumors involving the lung and large airway, because a missed or

delayed diagnosis can lead to progression to advanced stages before effective treatment is initiated, adversely affecting prognosis. Benign neoplasms of the lung and large airway must also be kept in mind as mimics of more aggressive processes. Familiarity with both, therefore, is important in the effective workup and optimal management of a child who presents with a primary lung or airway neoplasm on imaging evaluation.

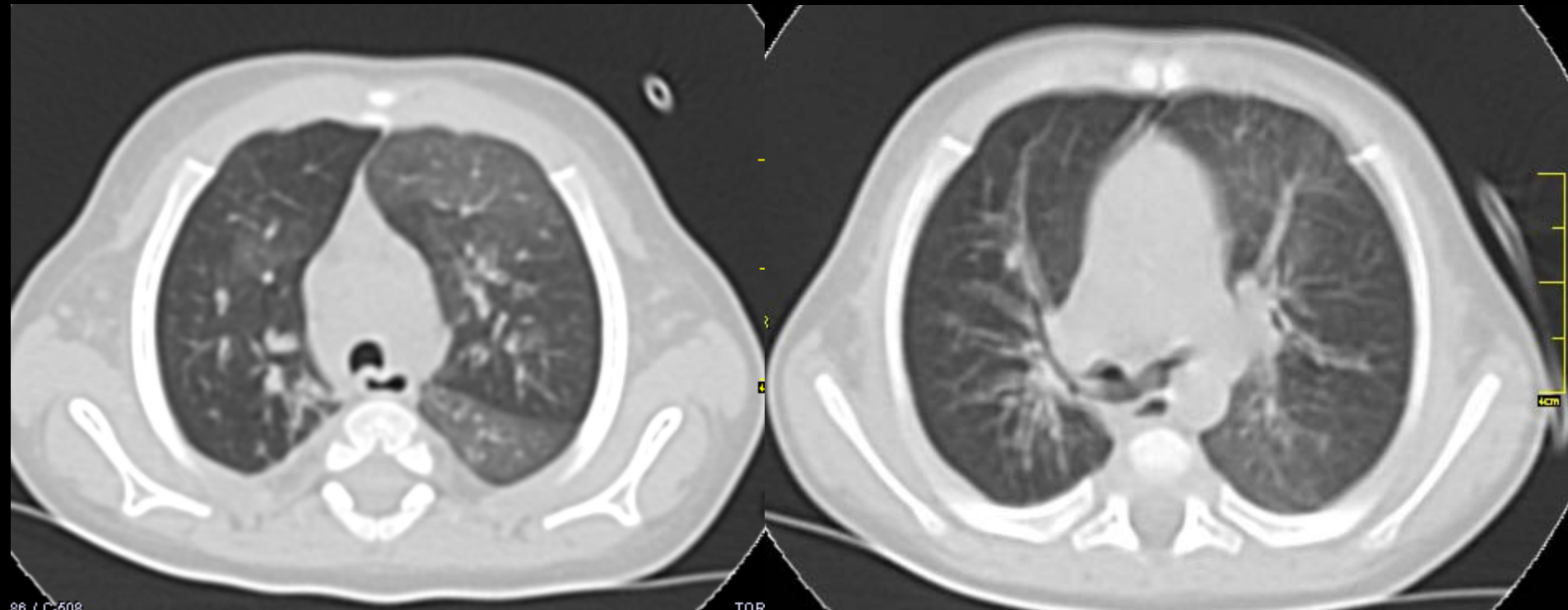




# Enfermedad de Castelman

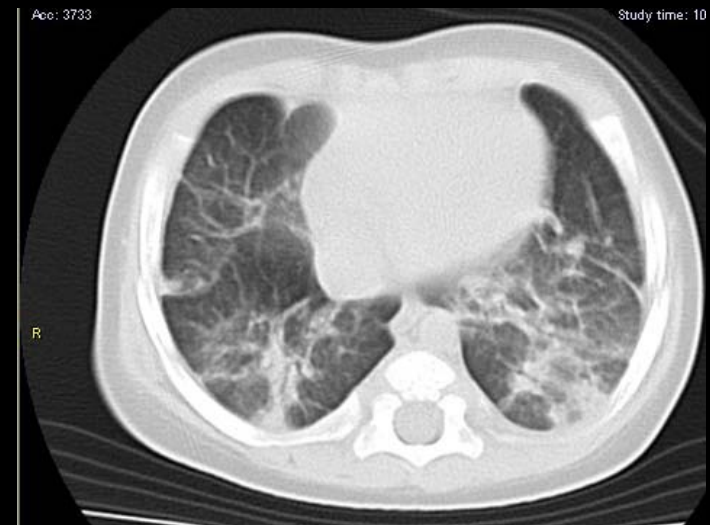
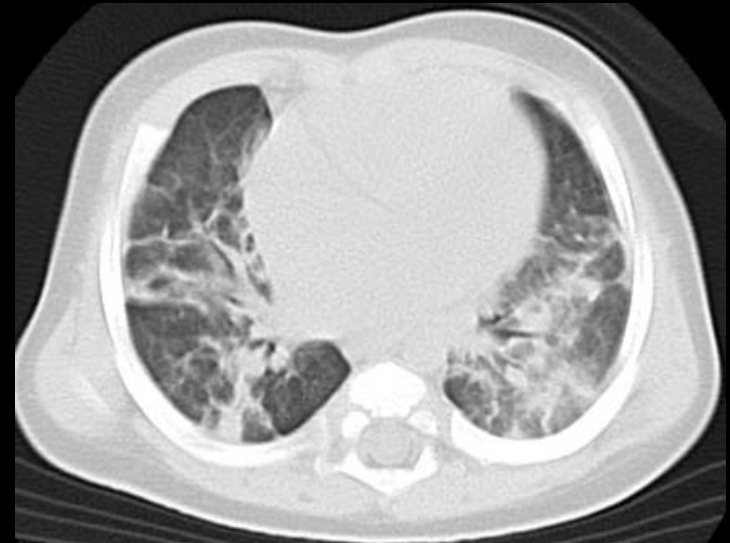
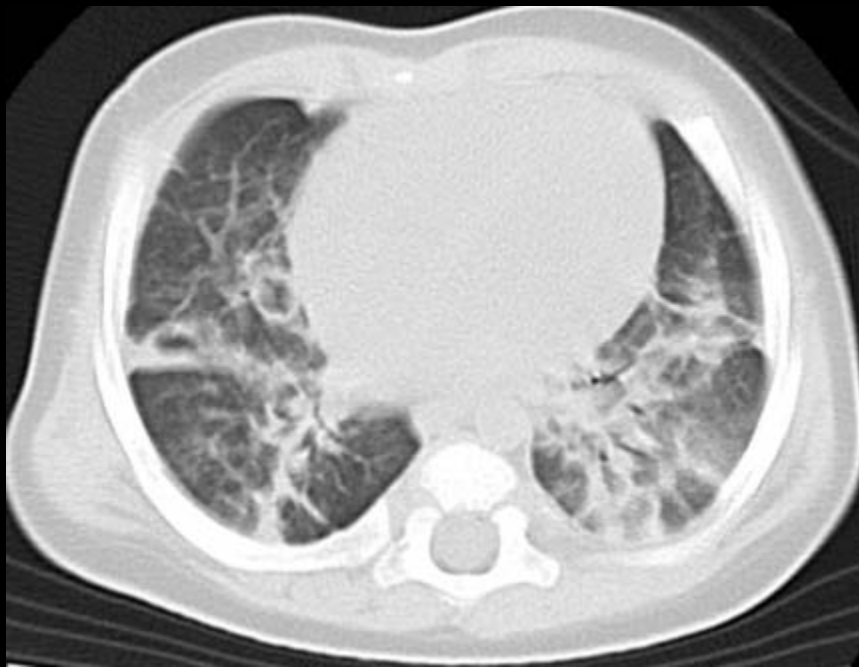# Mosaico bronquios con paredes engrosadas

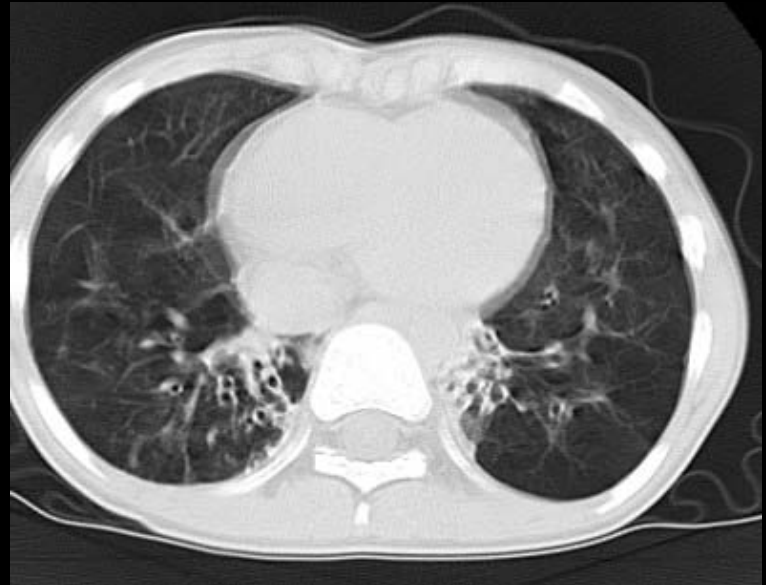
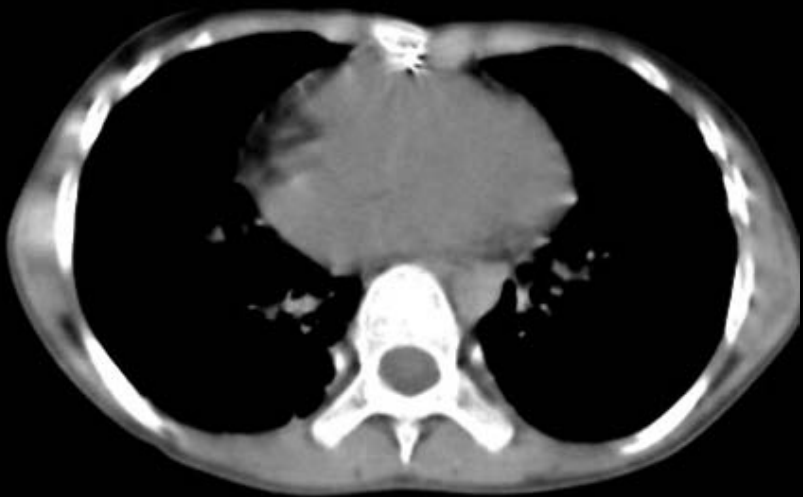
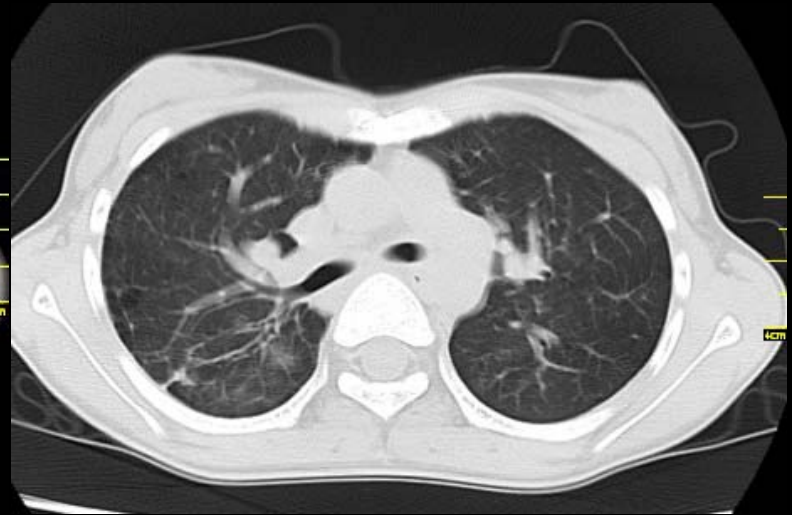
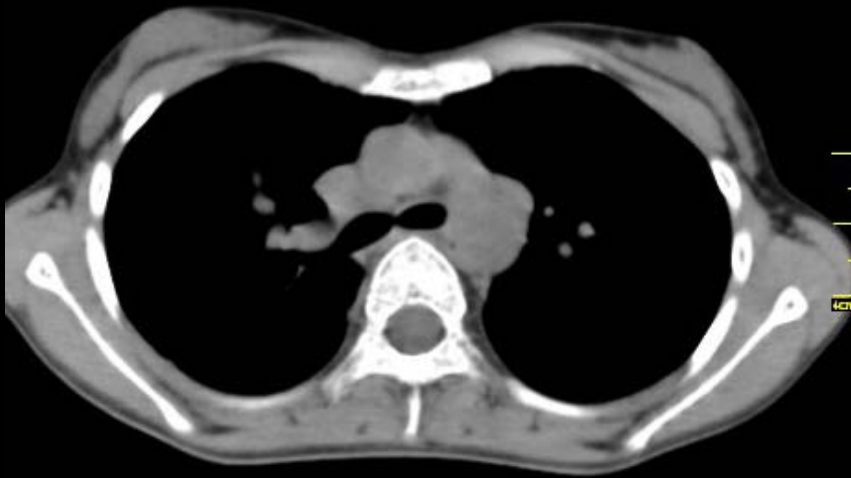
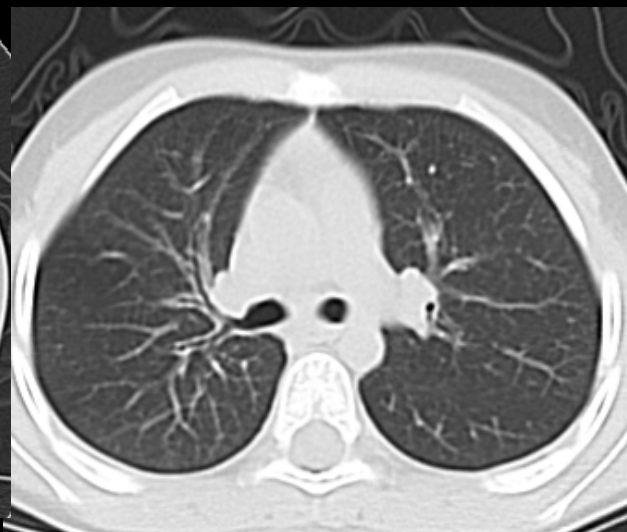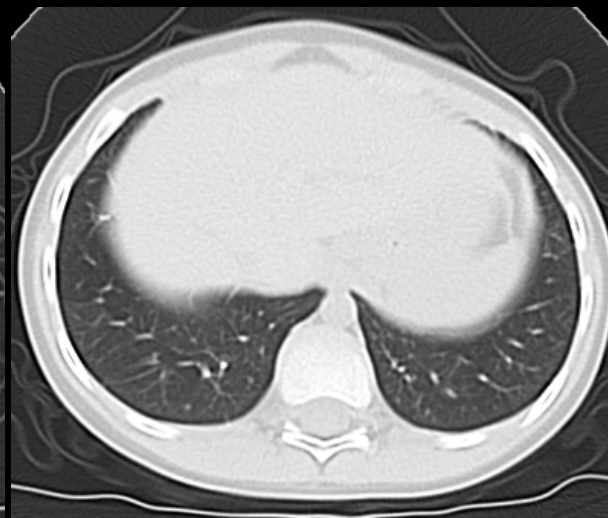
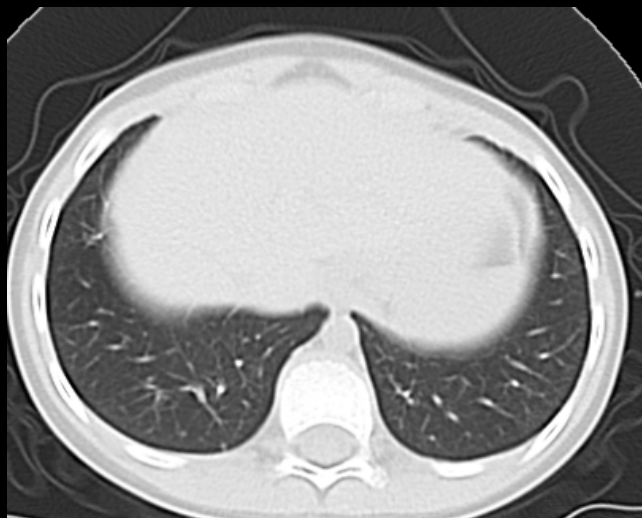
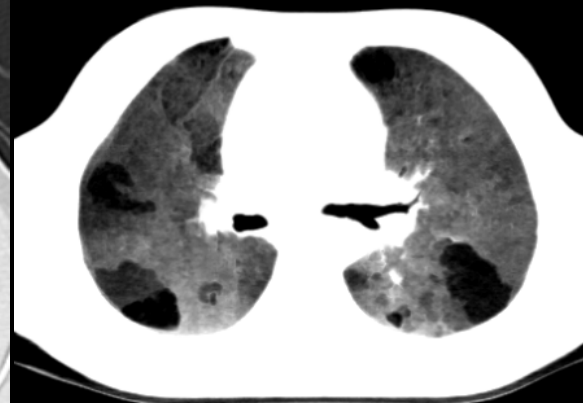
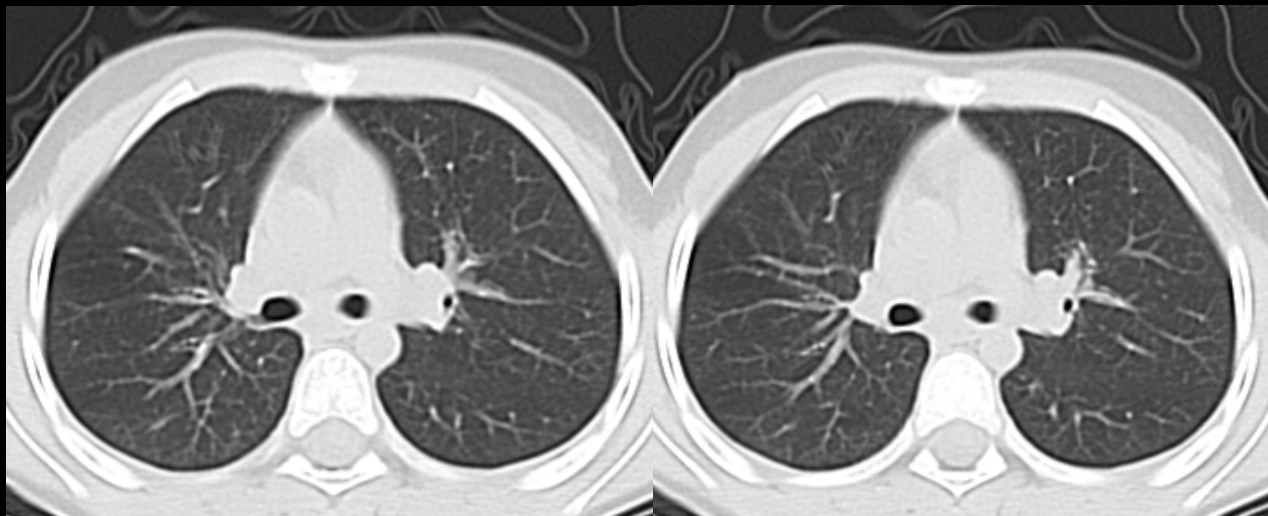# Bronquiolitis por VRS



# Di giorge

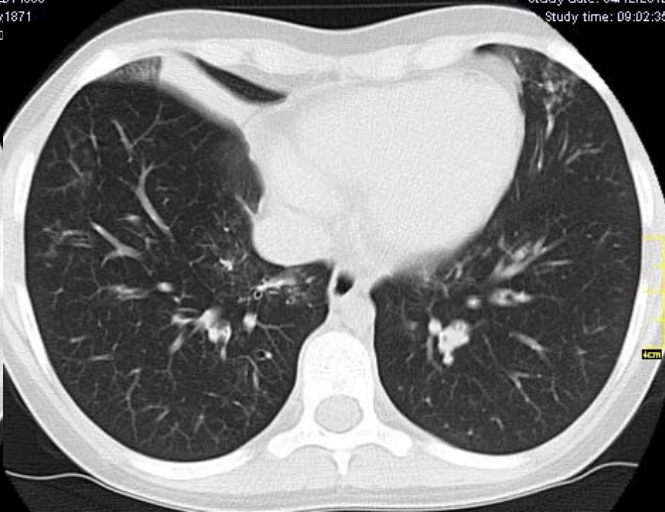
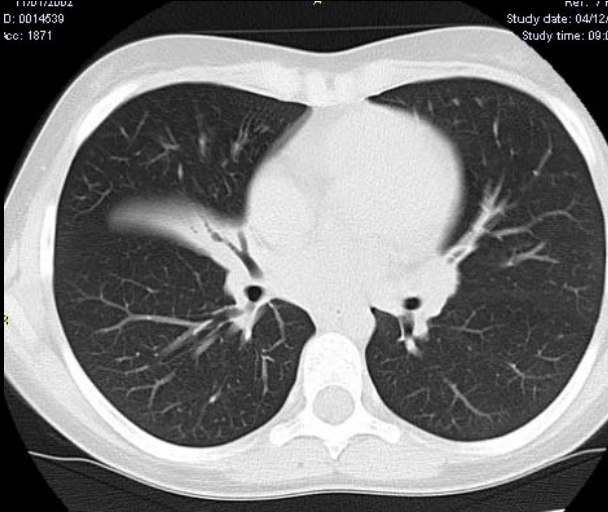
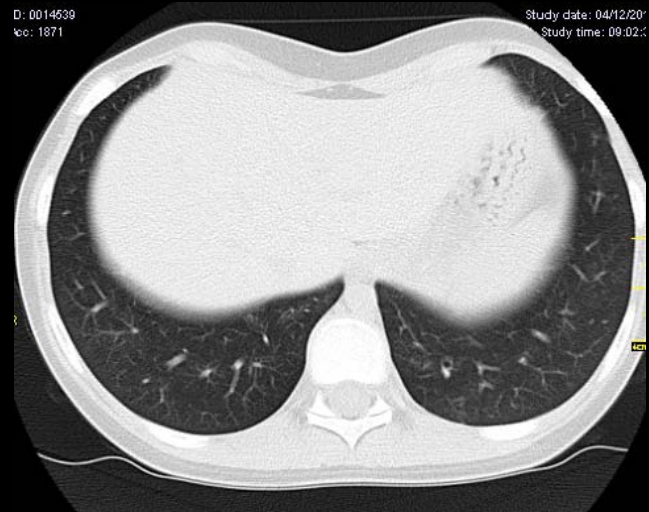
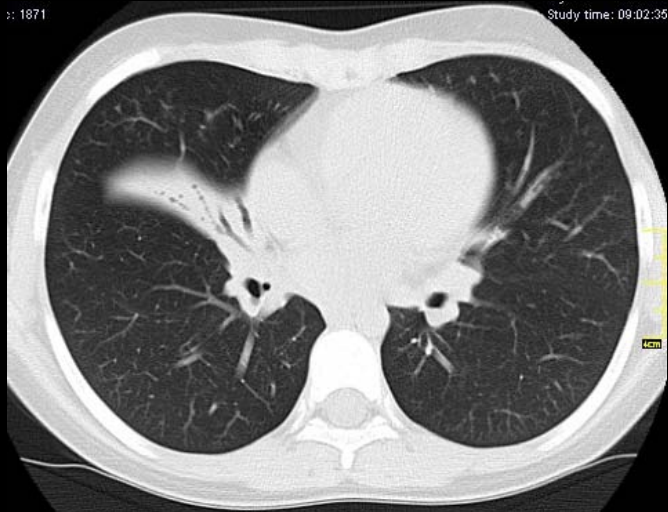
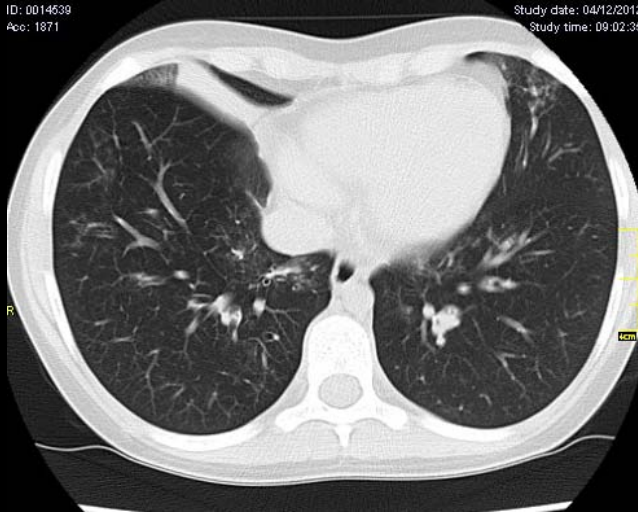


asma

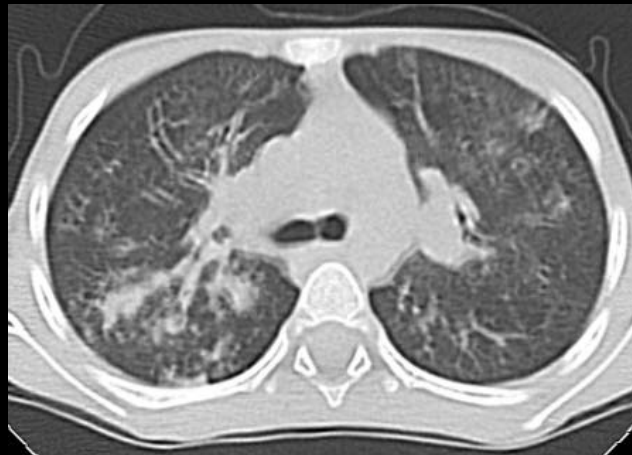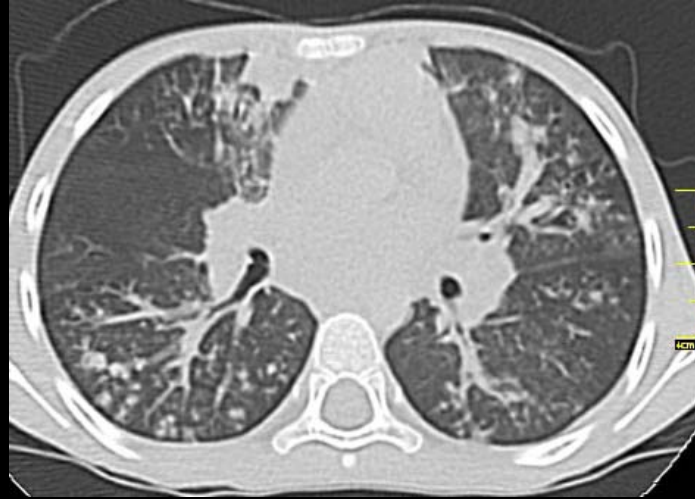
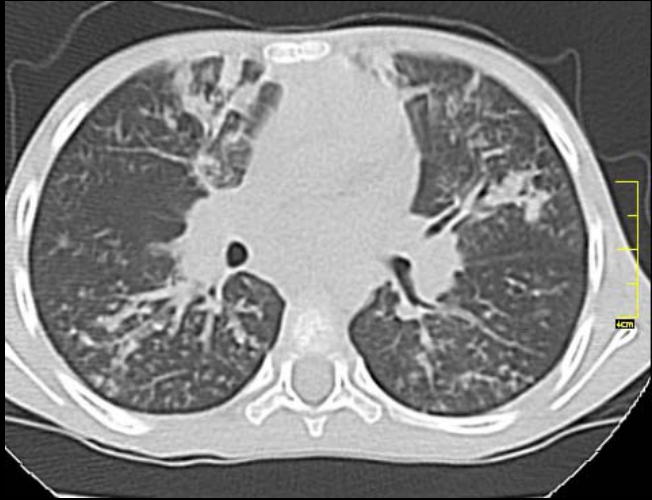




# Asma difícil control

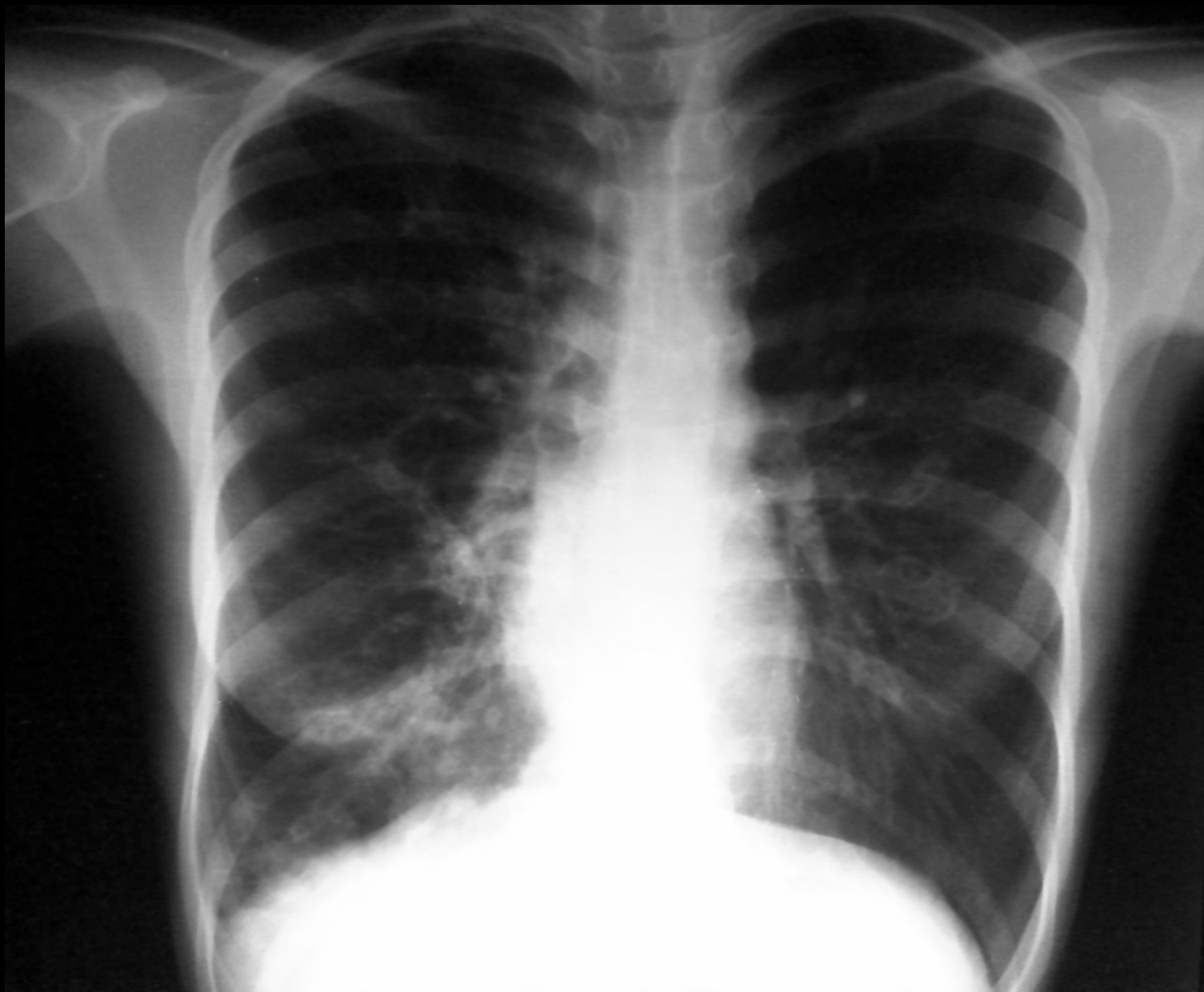

# psitacosis

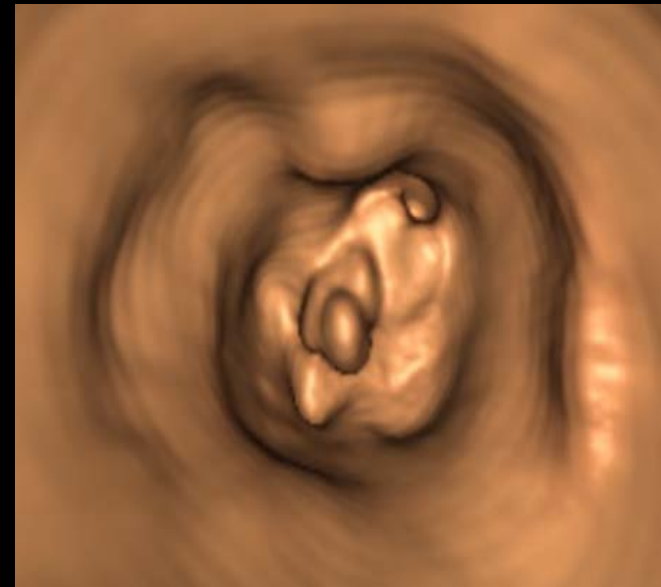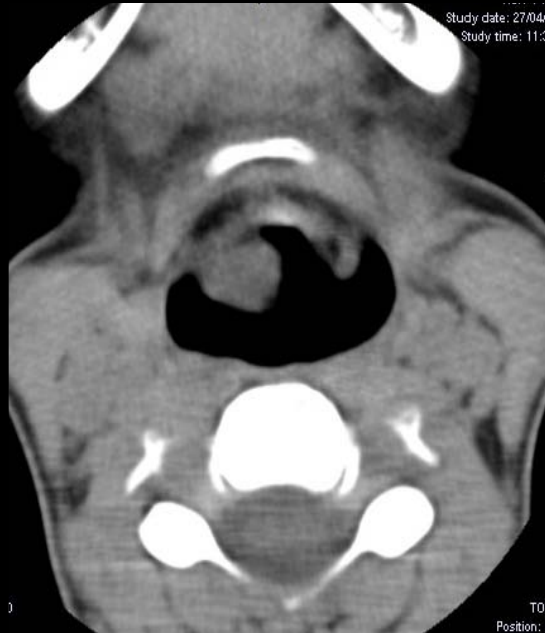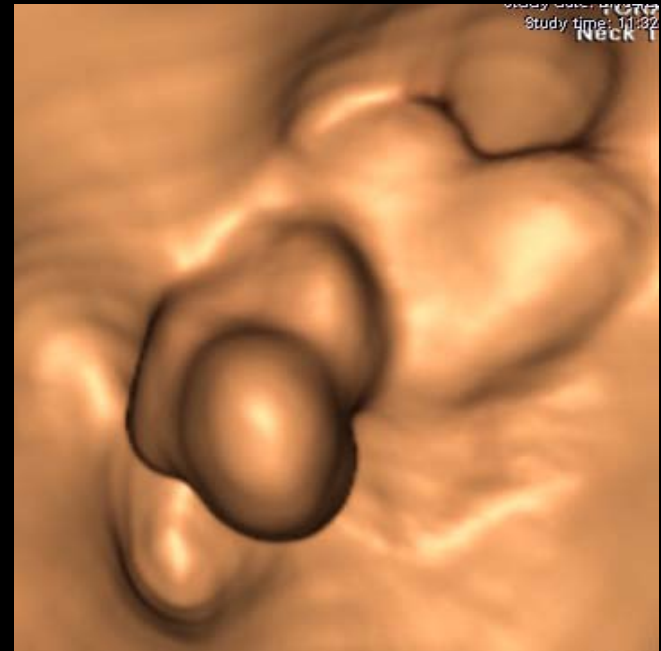
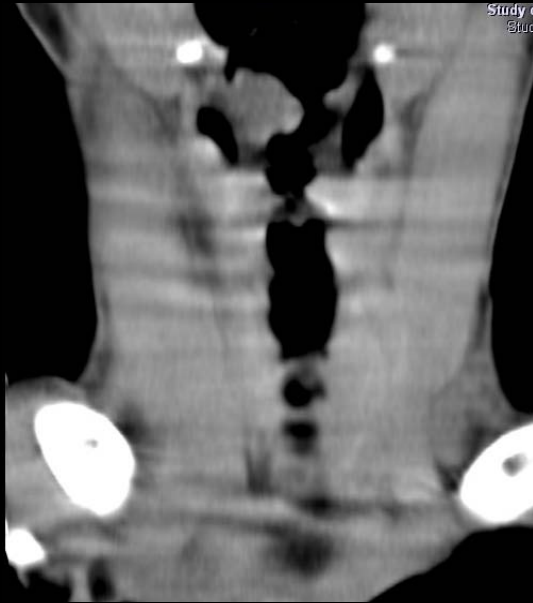


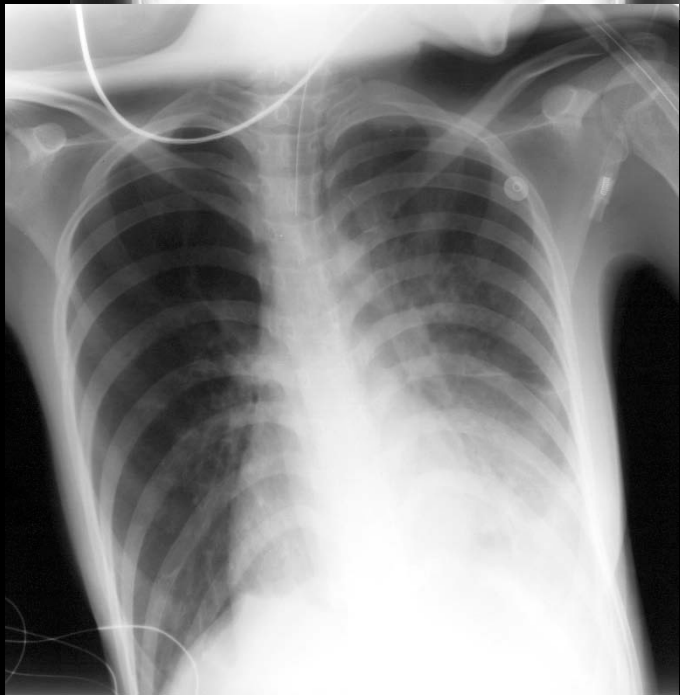
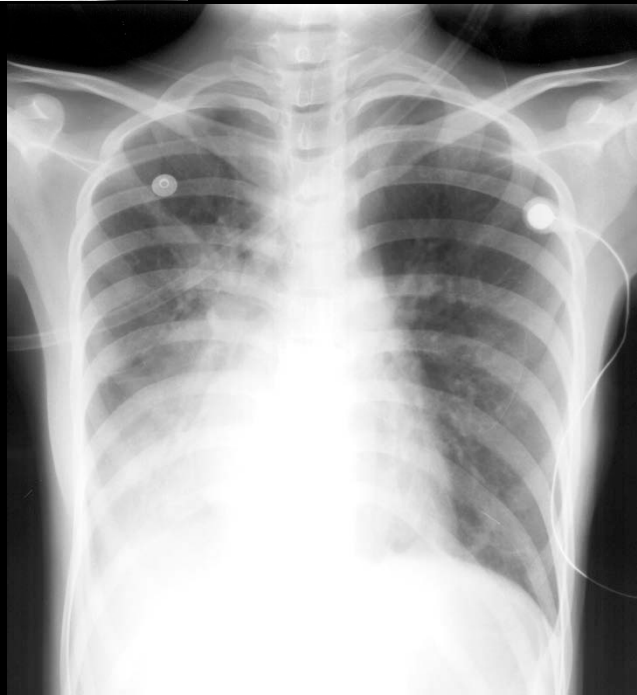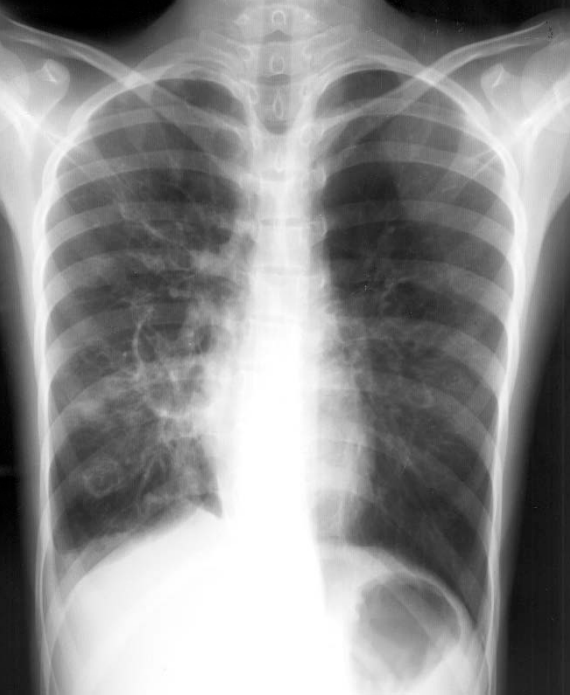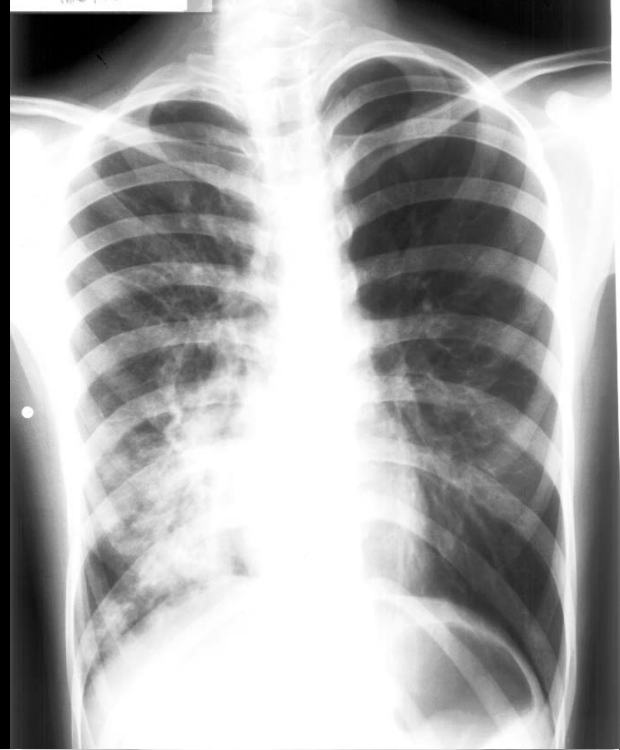


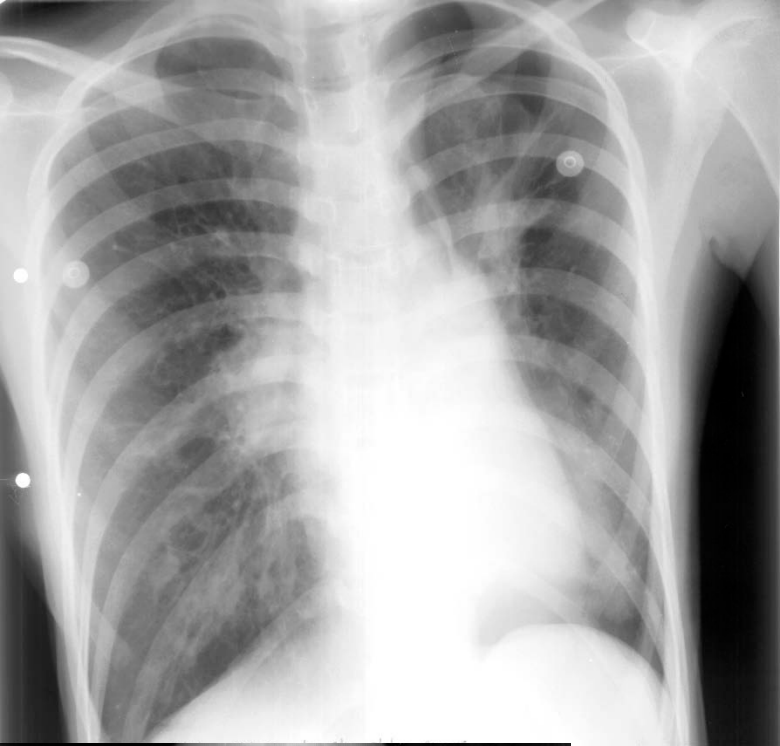## Radiografía de Tórax papilomatosis

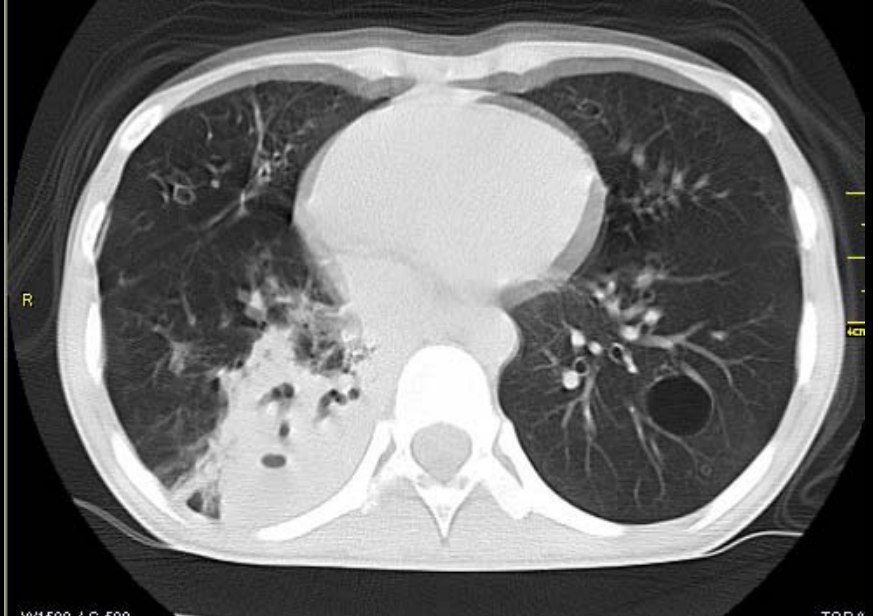
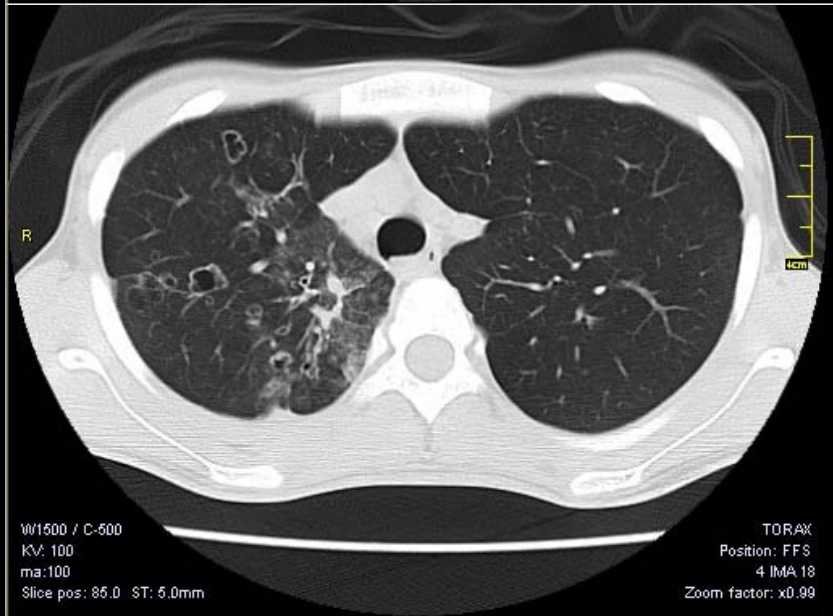
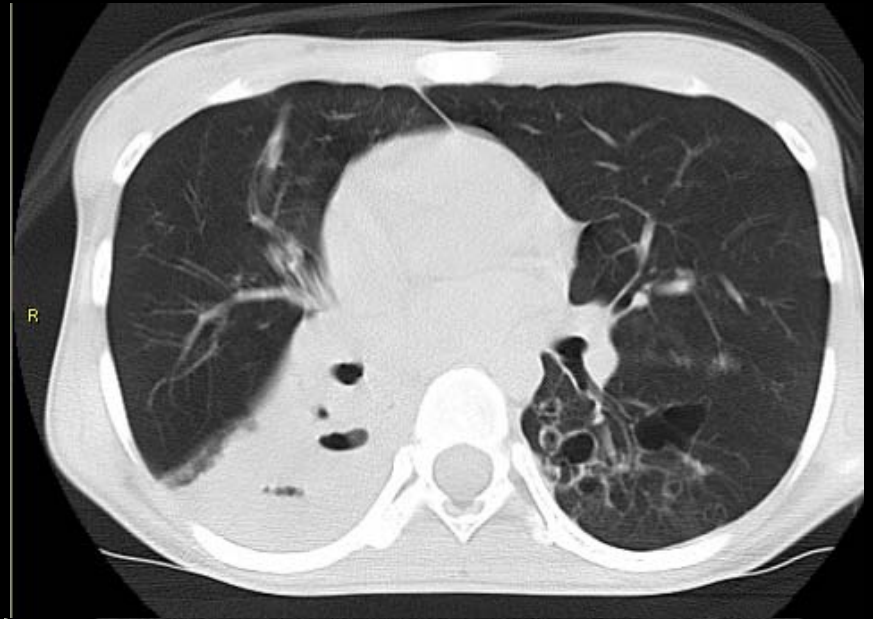
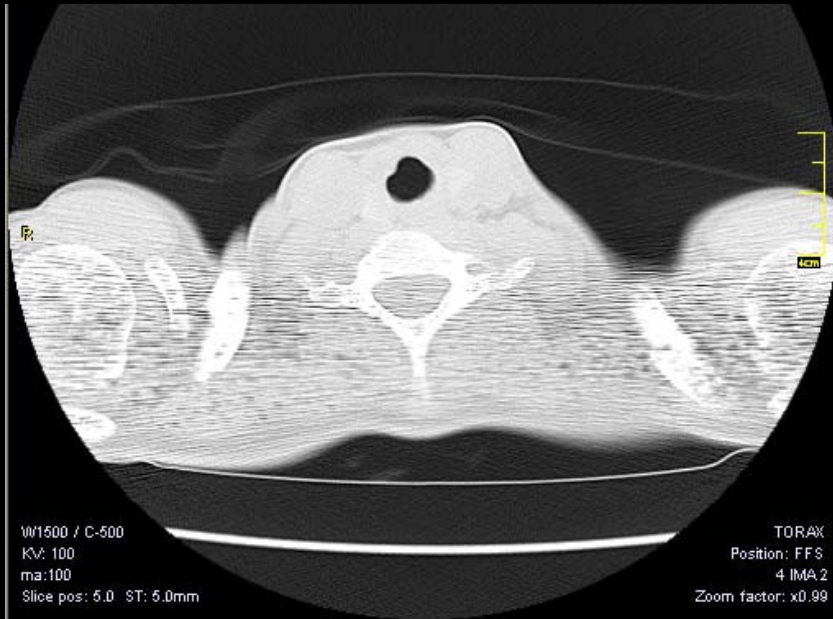

# Papillomatosis laringea





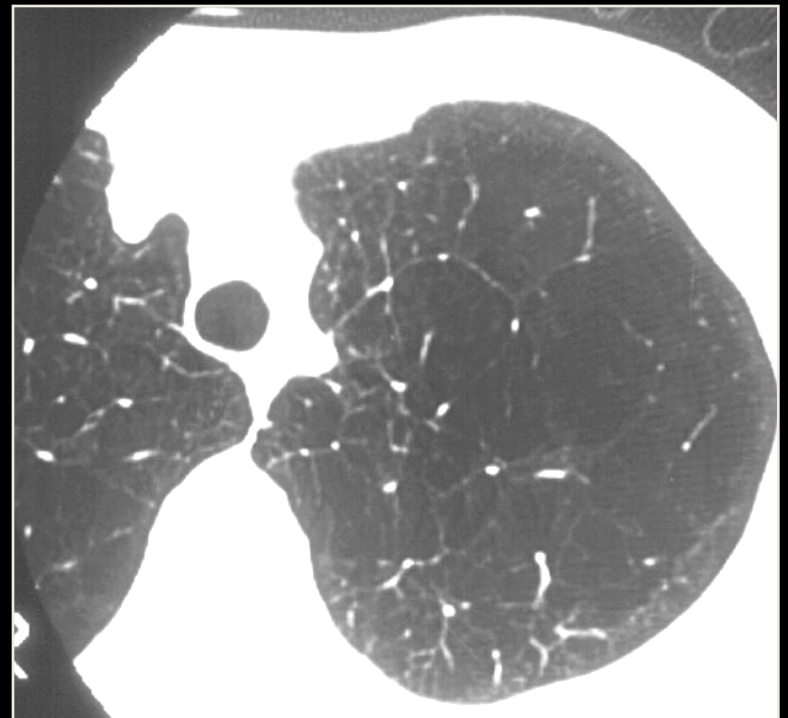
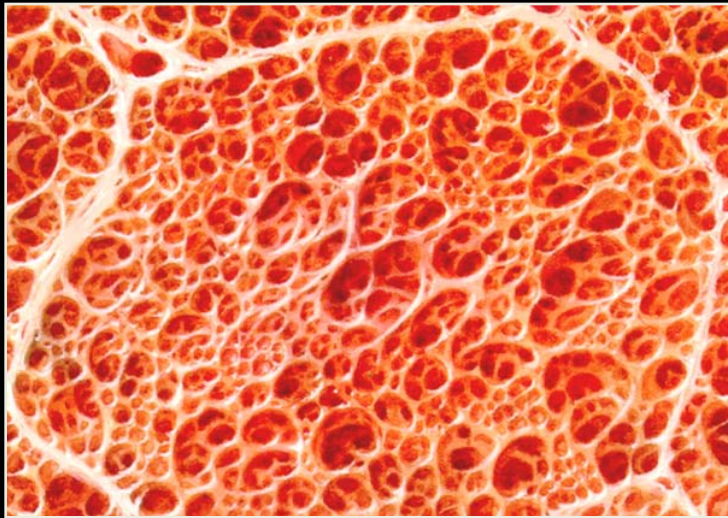
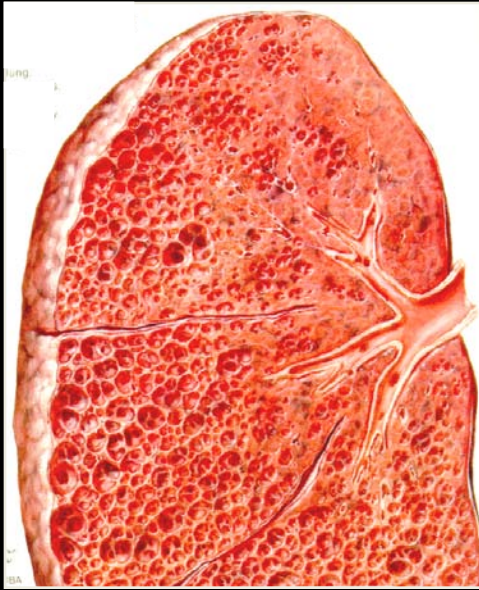
# Papilomatosis laringea





# Espacios Aéreos por destrucción de red de fibras elásticas

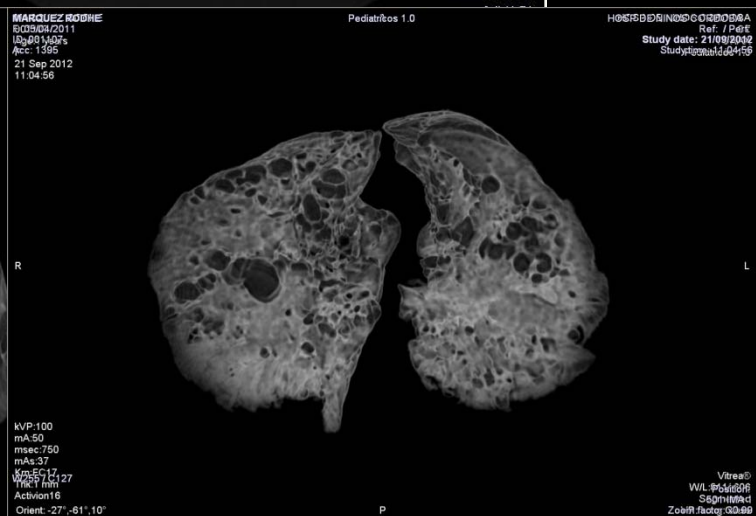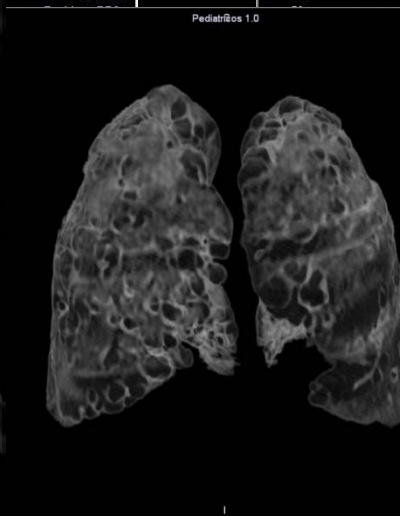
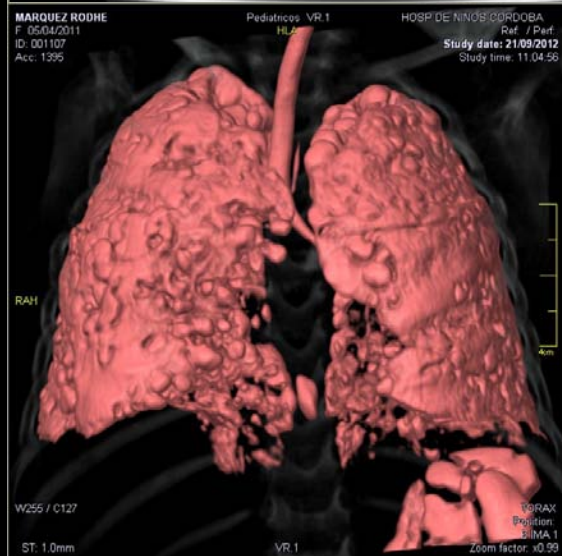
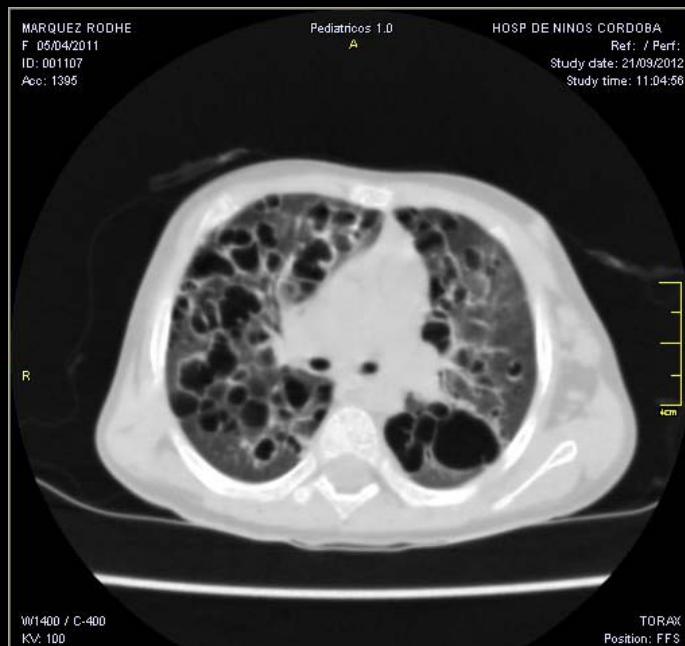
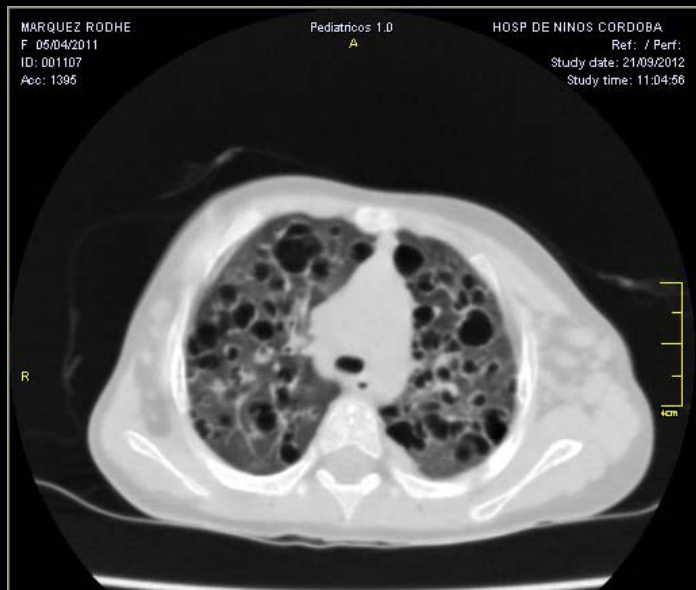Enfisema panlobulillar  
Agrandamiento de espacios  
alveolares por destrucción  
permanente de la pared alveolar  
TAC: Área de < densidad  
Distorsión de Arquitectura  
“Poda” de vasos



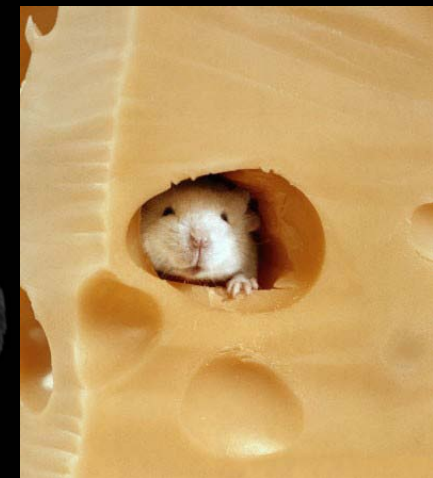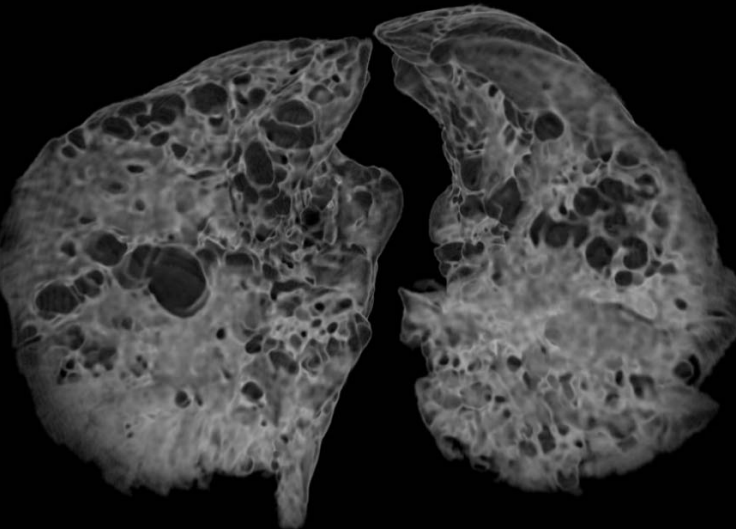
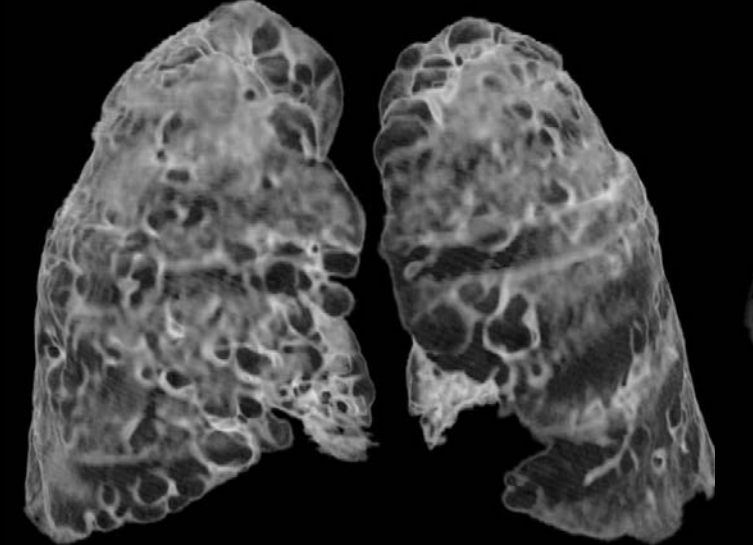
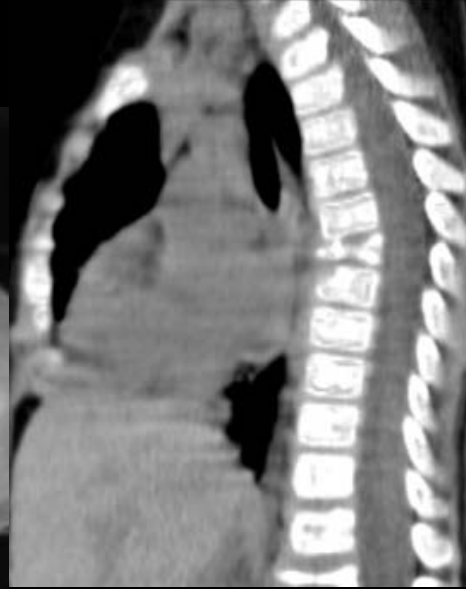
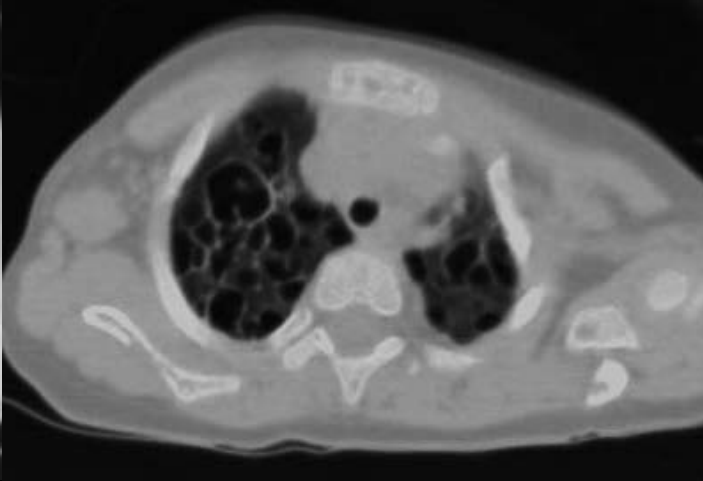
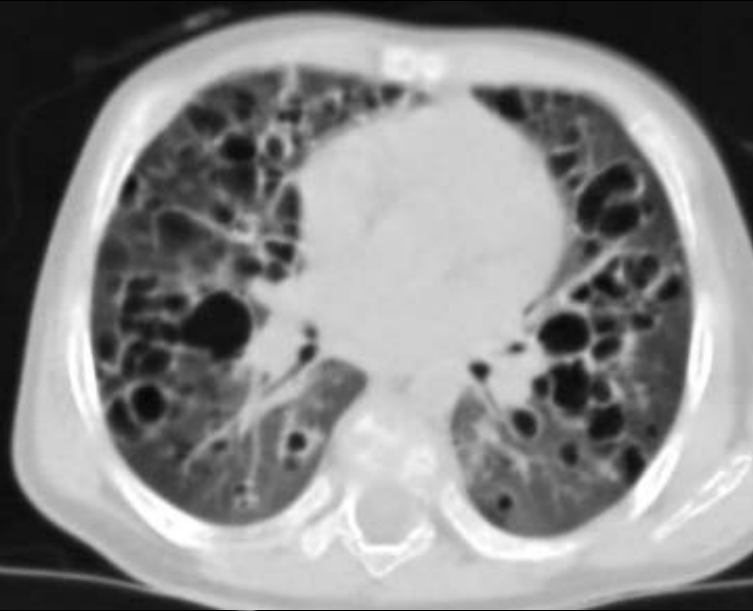
Déficit de Alfa 1 Antitripsina



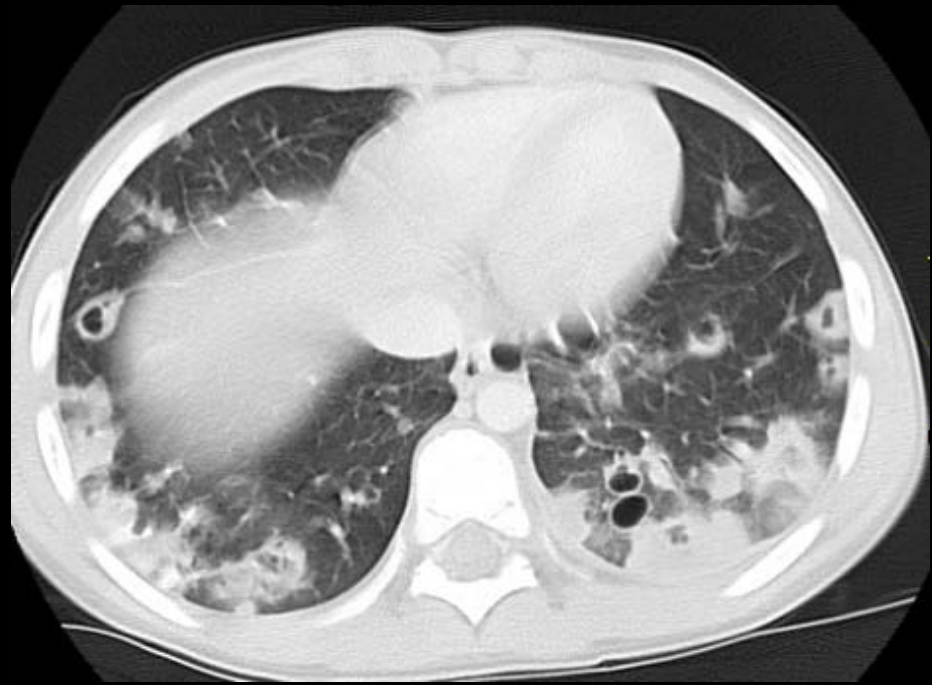
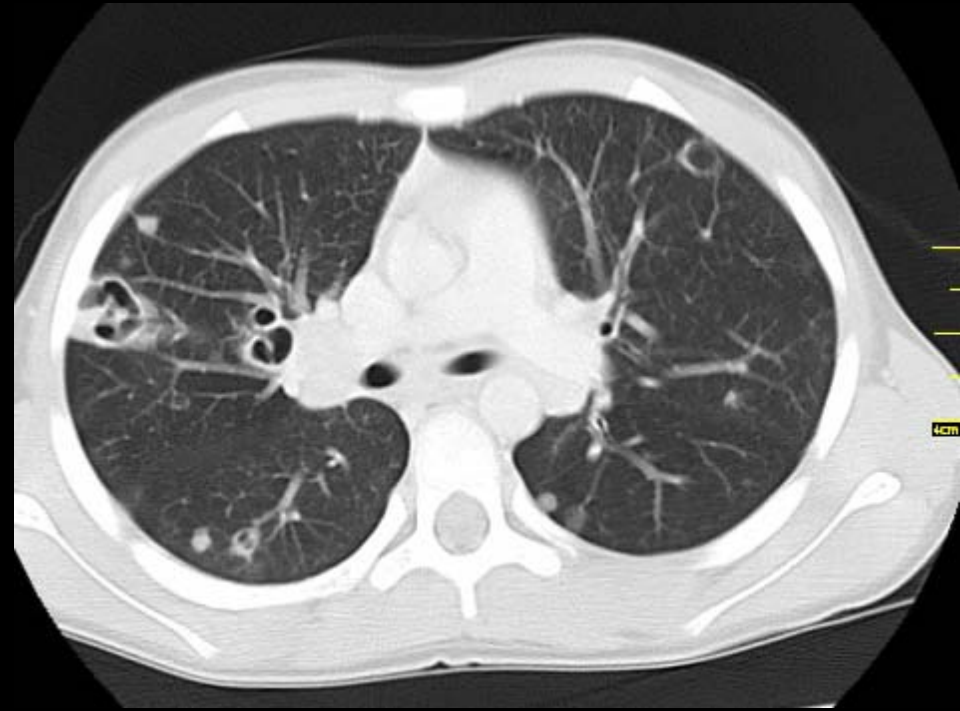
# histiocitosis Dx diferenciales



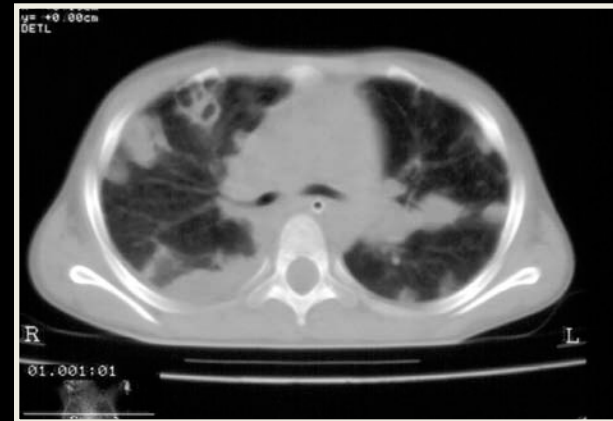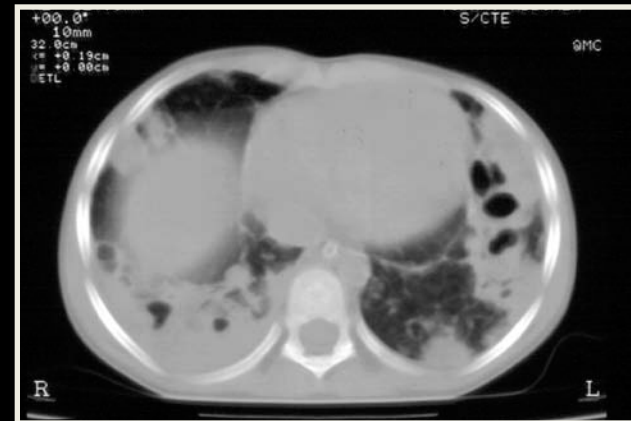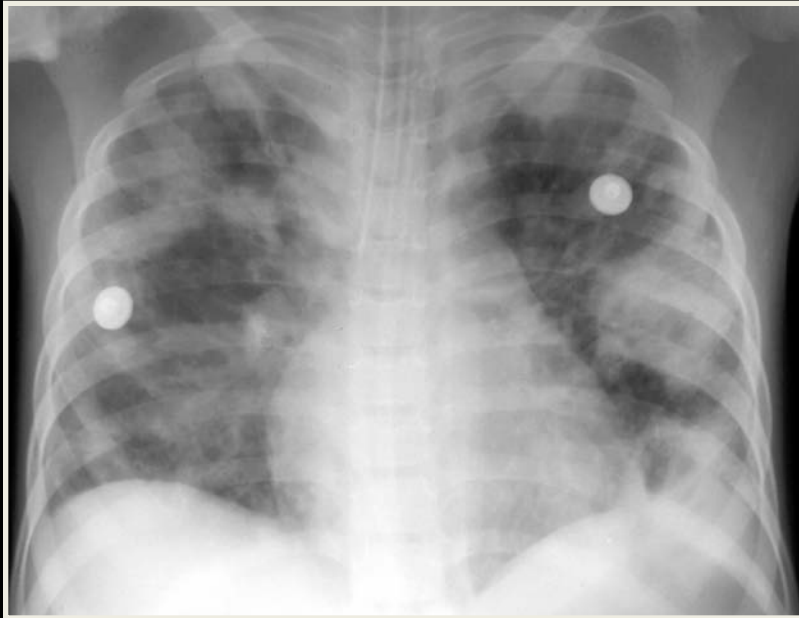
1 a síndrome febril prolongado disnea 2  
internaciones "neumonía- BOR"



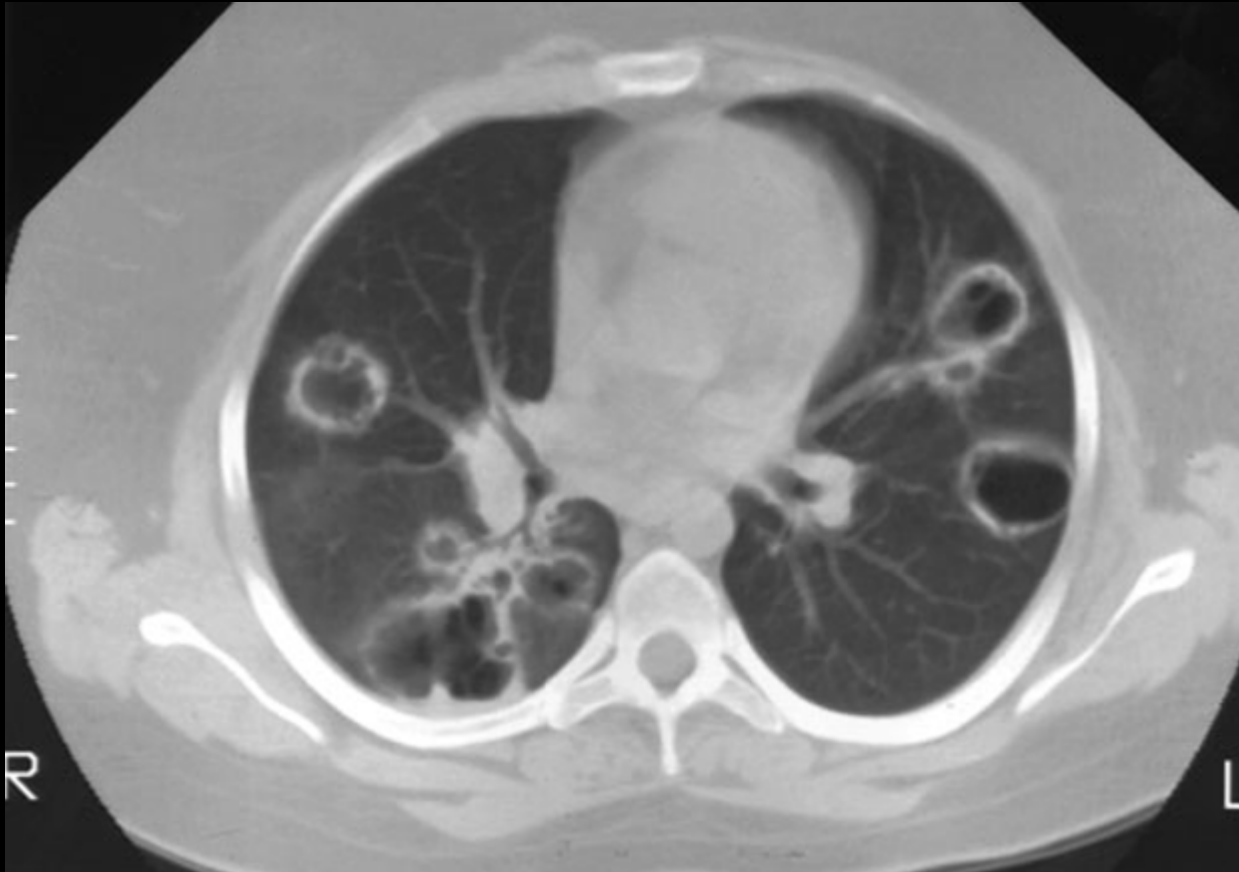
# Dx diferenciales stafilo



# Neumonía por Stafilococo

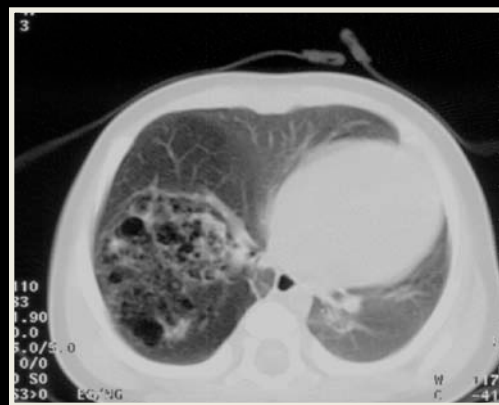
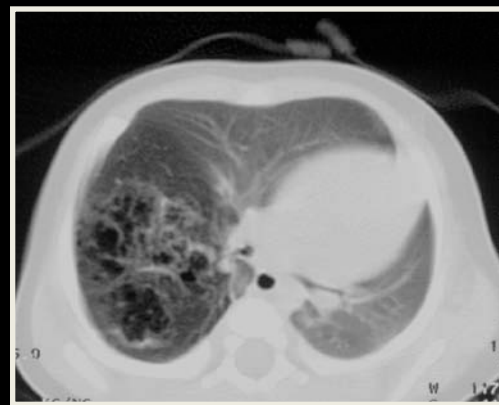
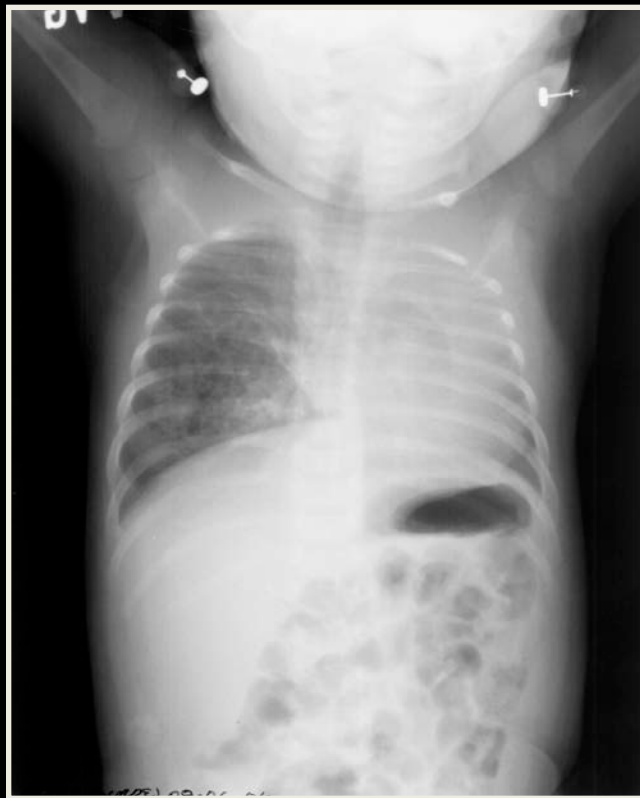# Granulomatosis de Wegener:





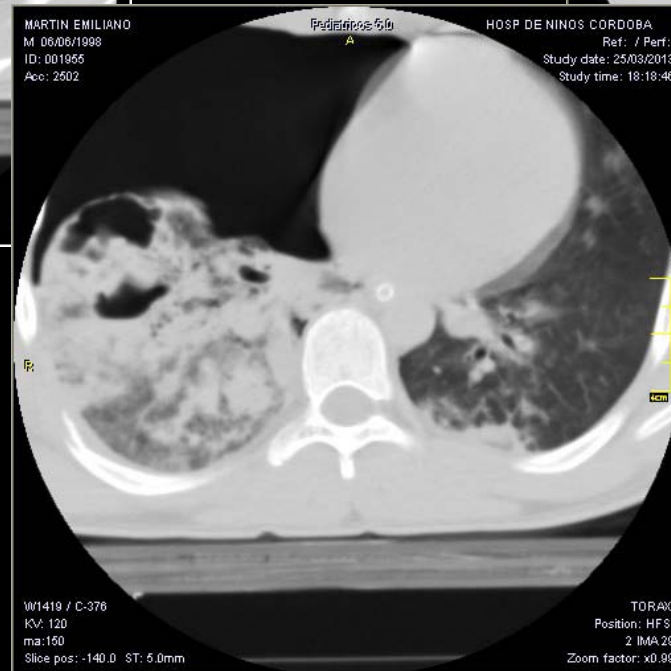
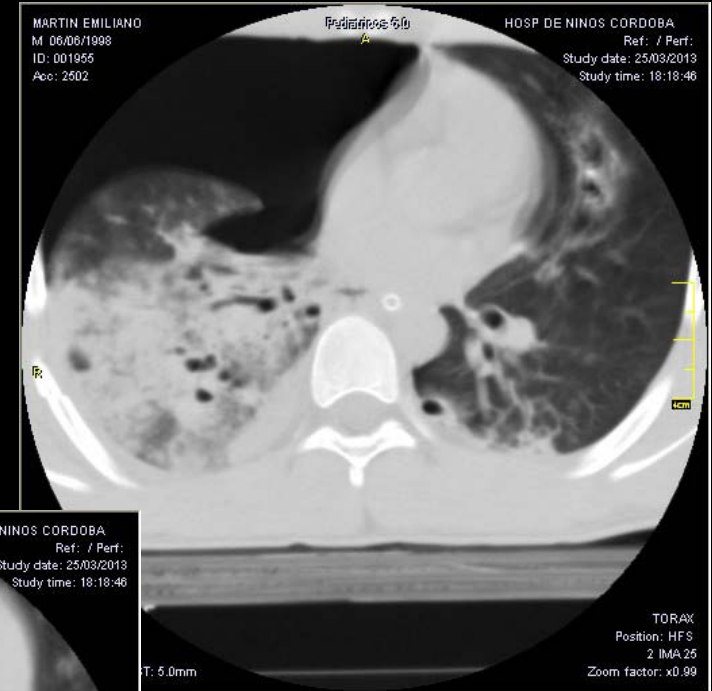
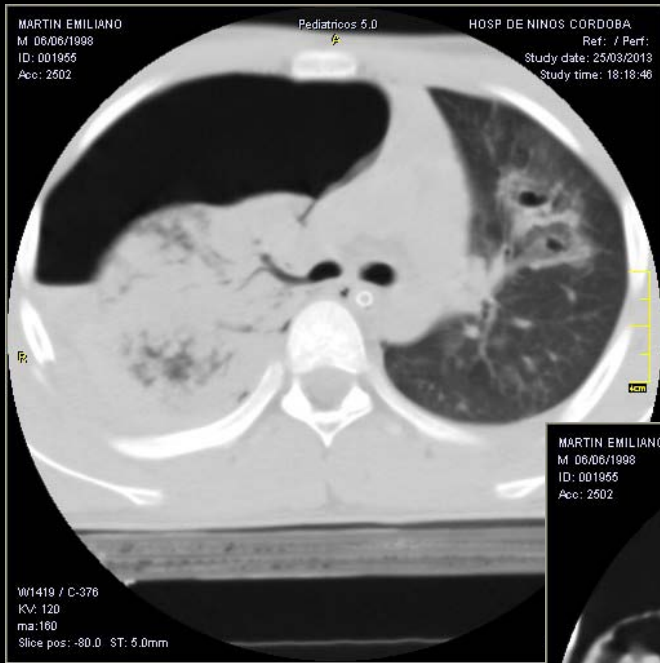
# MAQP



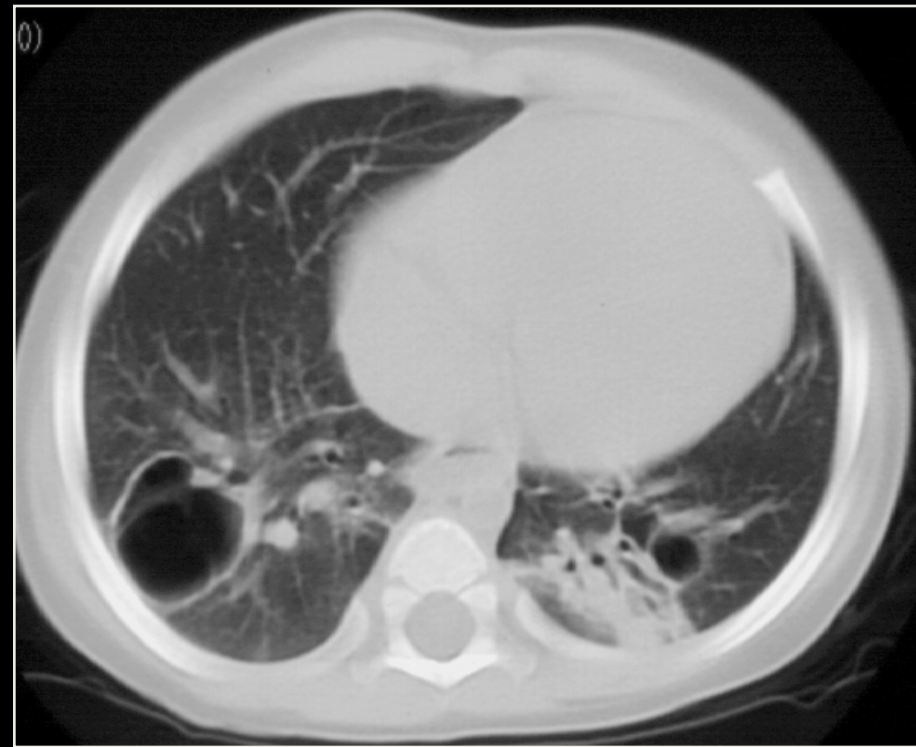
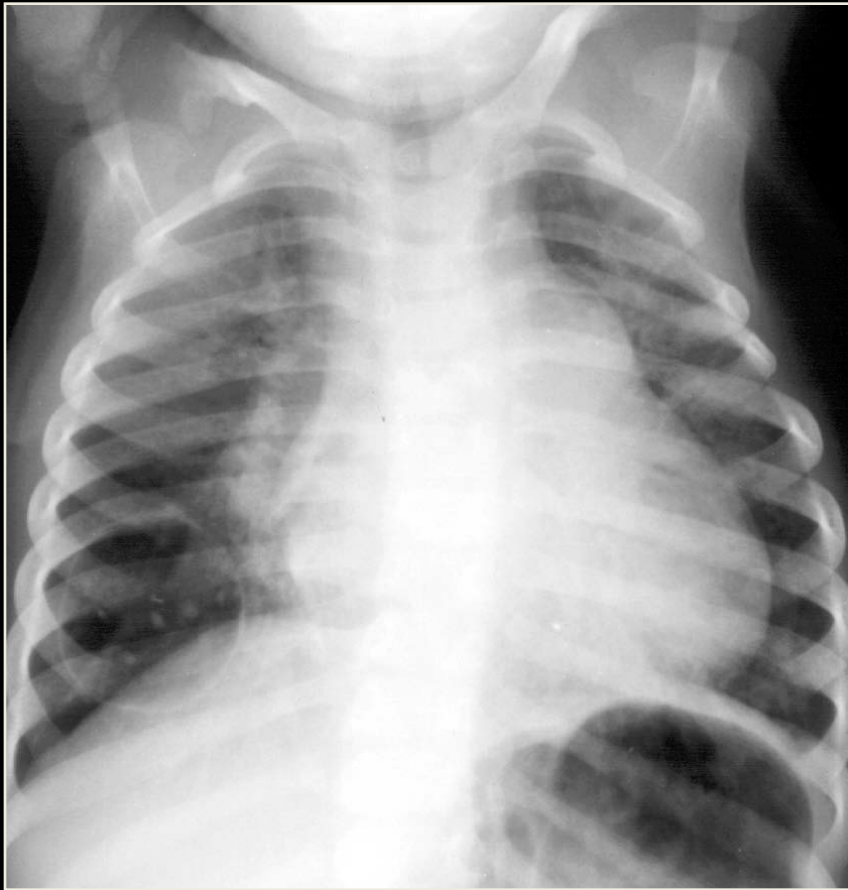# Bronquiectasias No FQ

Muchas Gracias...  
por su atención!!!

# Dx diferenciales neumatoceles trauma

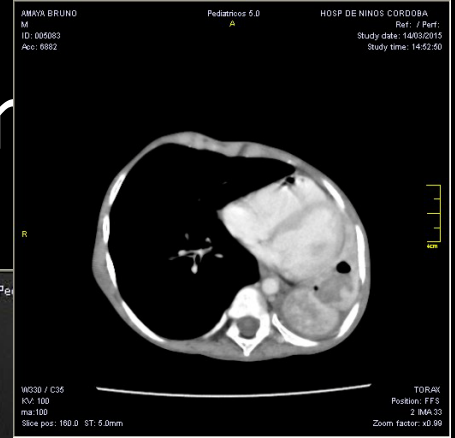
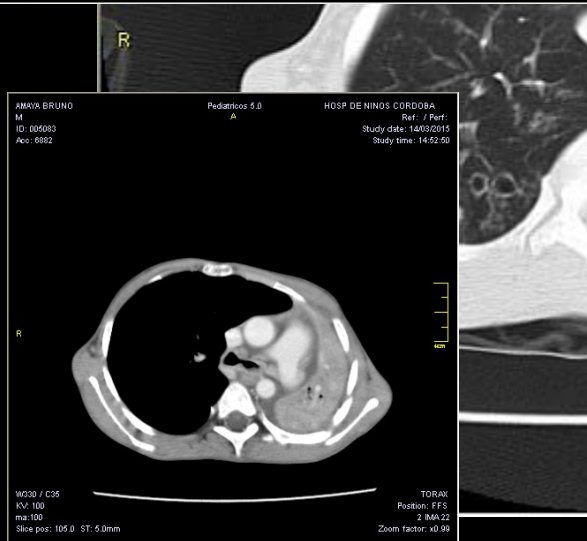
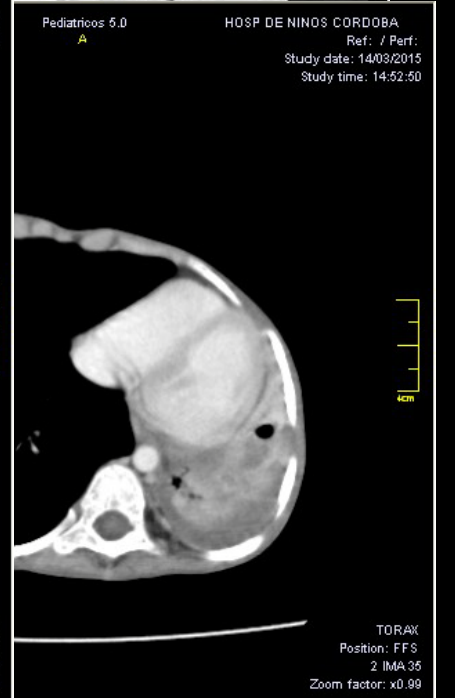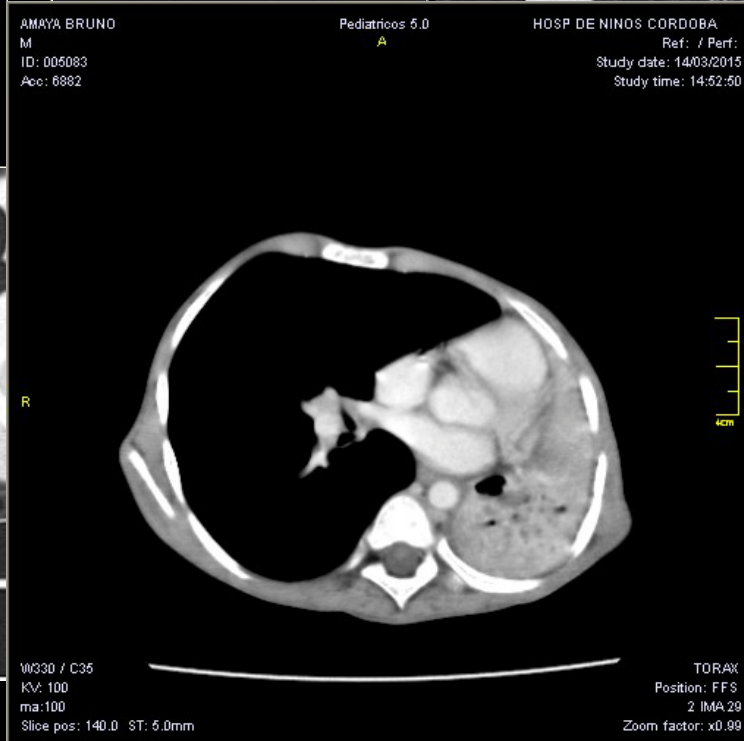
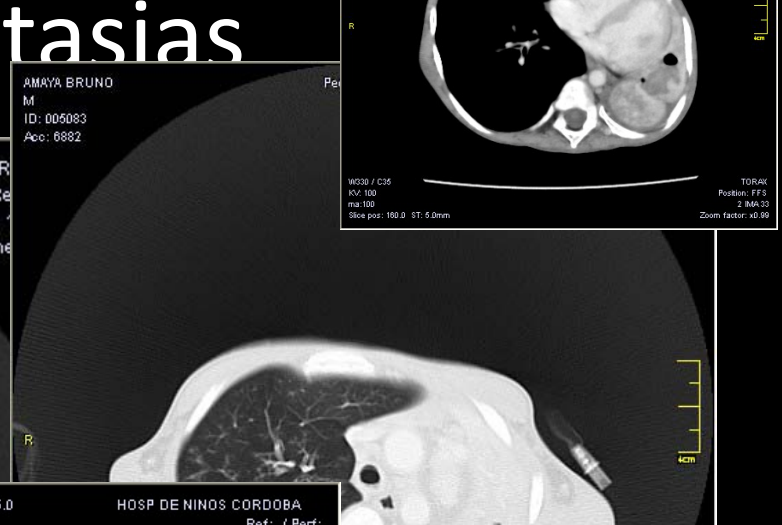
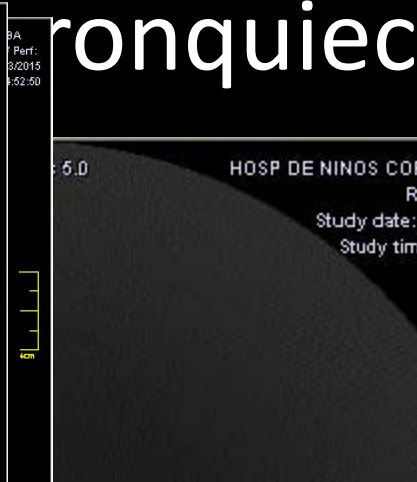
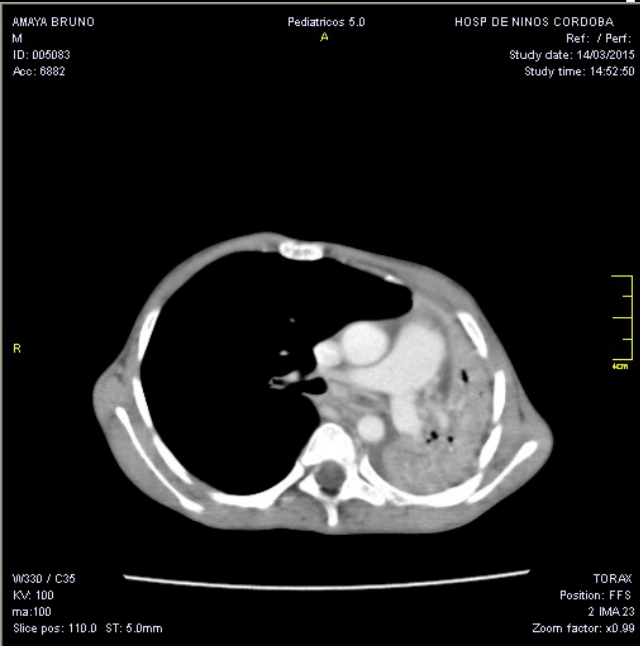


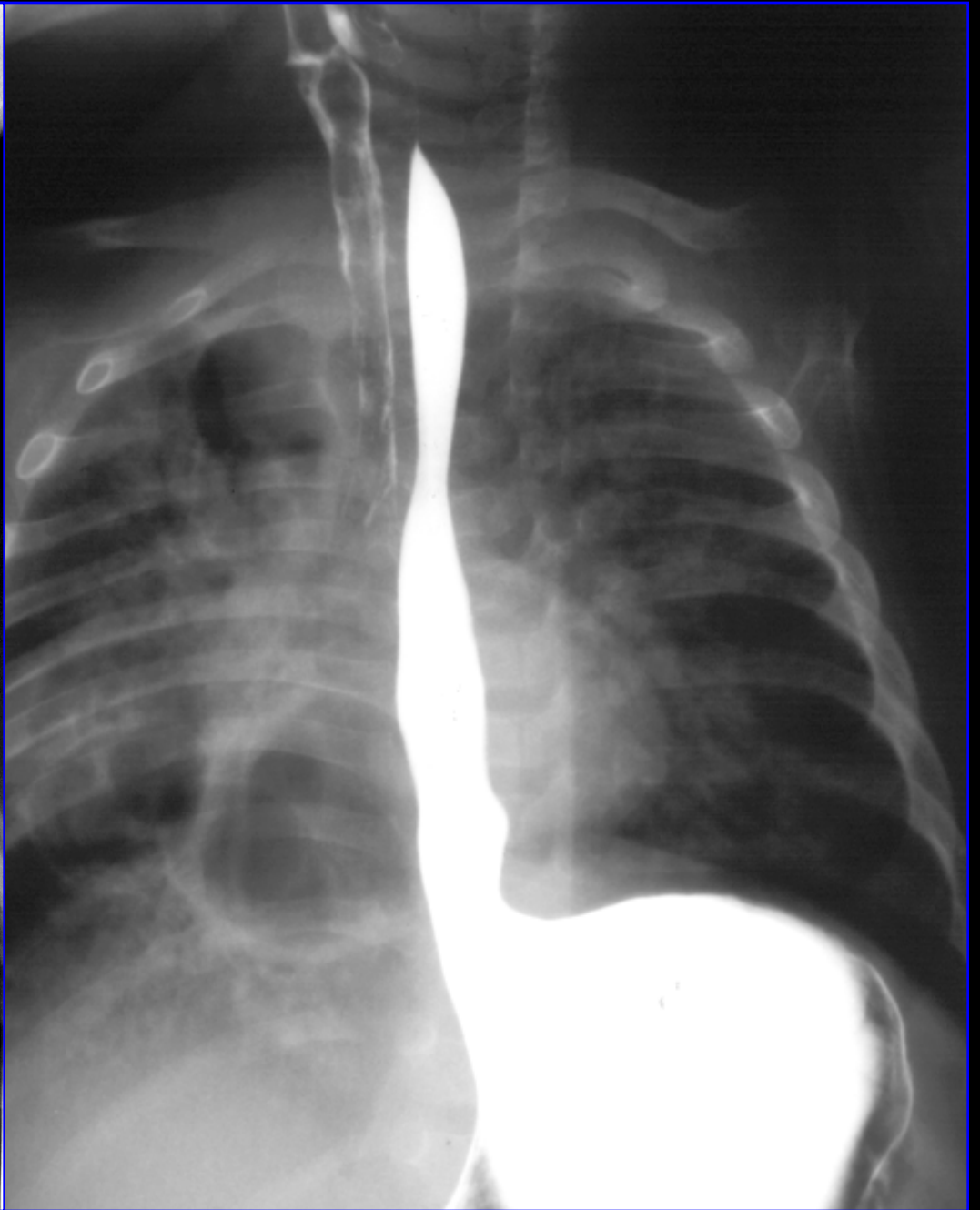
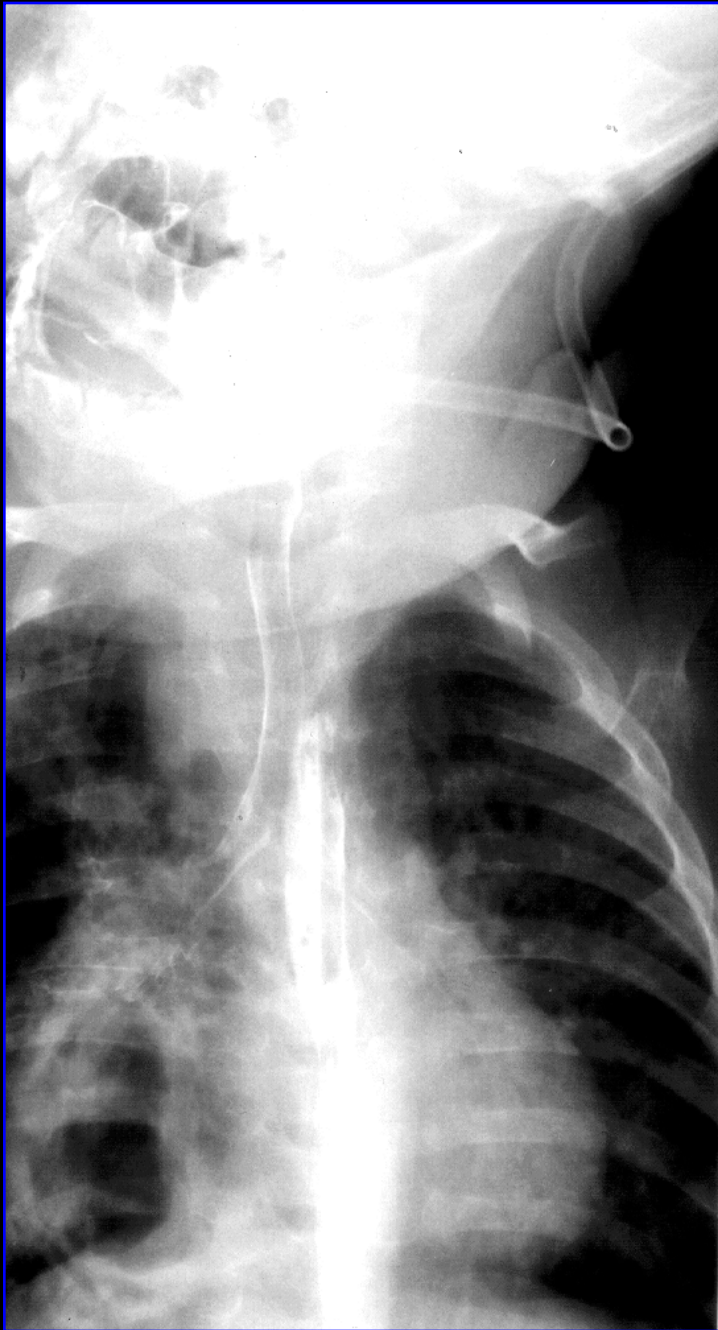
# Neumatocele:



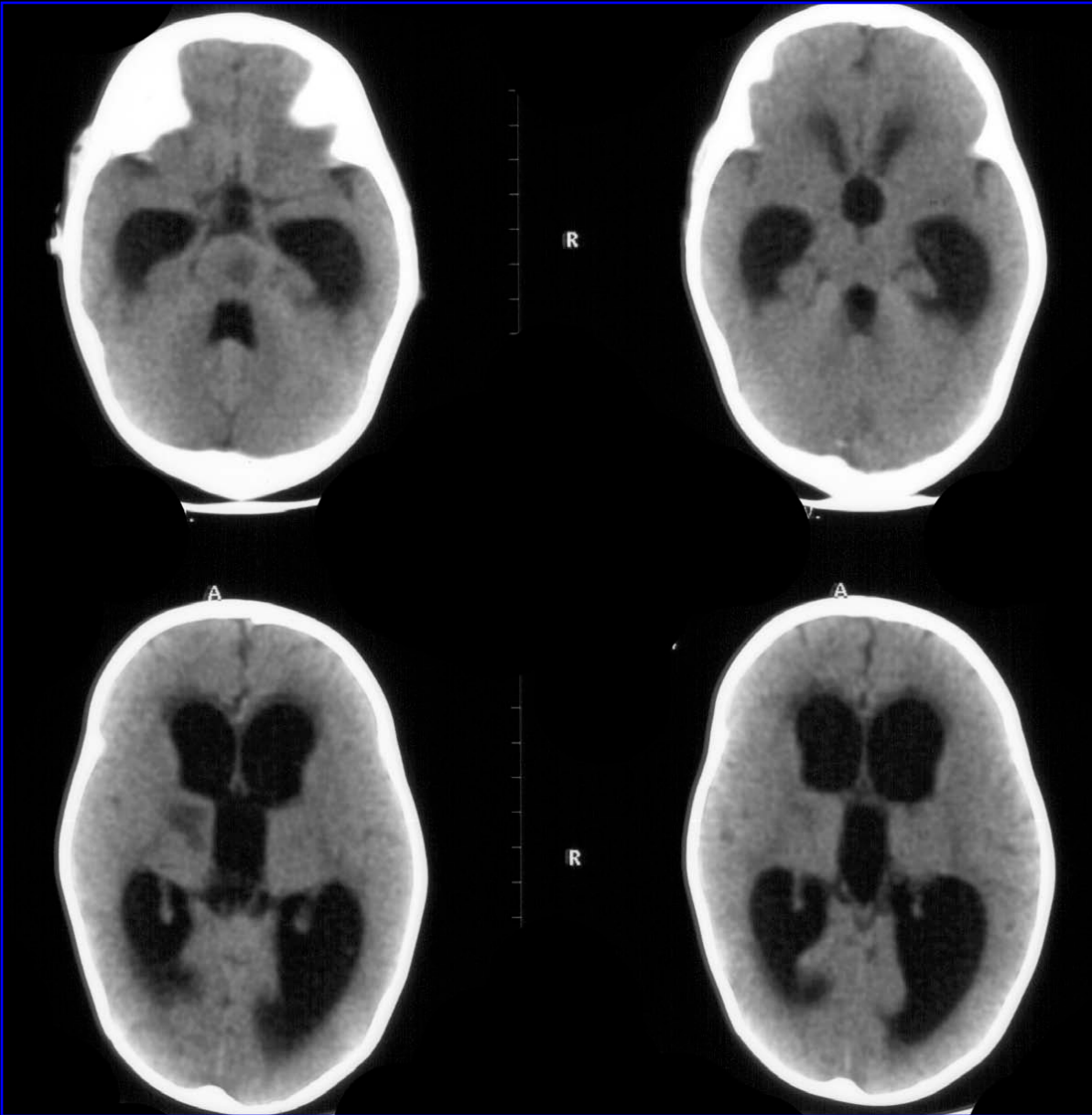


# Absc pulmon lobectom ronquiectasias

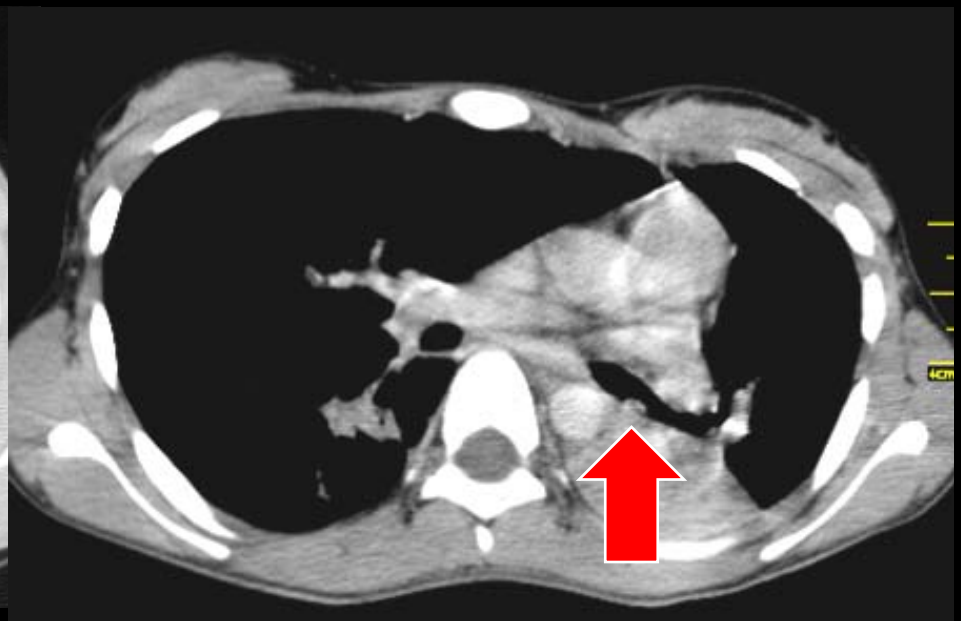
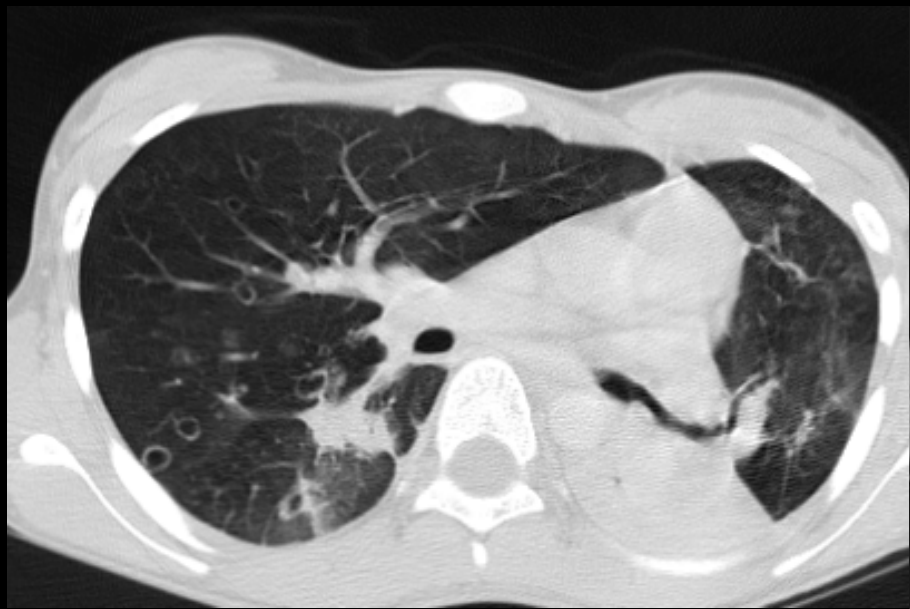
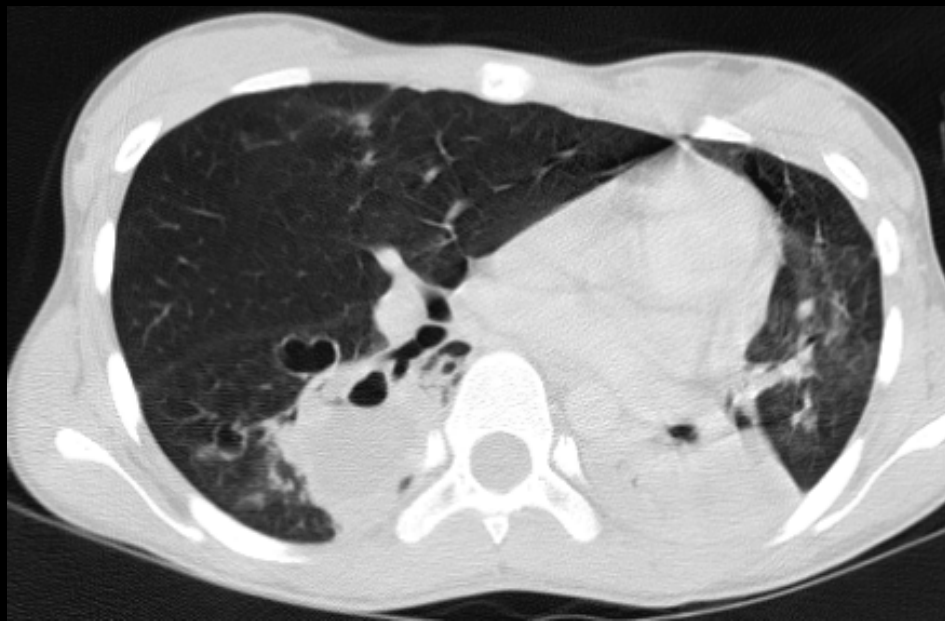
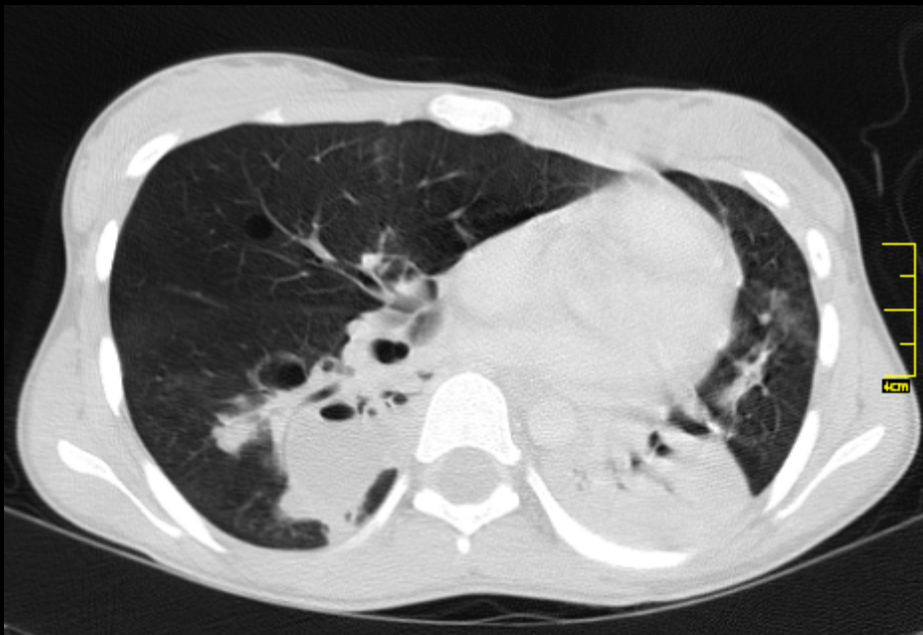

# Depresión súbita de conciencia, PL + para neumococo y TBC









# Atrapamiento aereo

Three-Section Expiratory CT: Insufficient for Trapped Air Assessment in Patients with Cystic Fibrosis?

- El atrapamiento aereo se evidencia en niños de 3 meses
- Es un end point en multiples trial
- Refleja compromiso de pequeña via
- Dx por tradicionalmente metodos funcionales
- La TC como metodo directo guarda relacion con pruebas funcionales
- Es mas sensible y muestra severidad y distribucion

# Multidetector CT Parameters

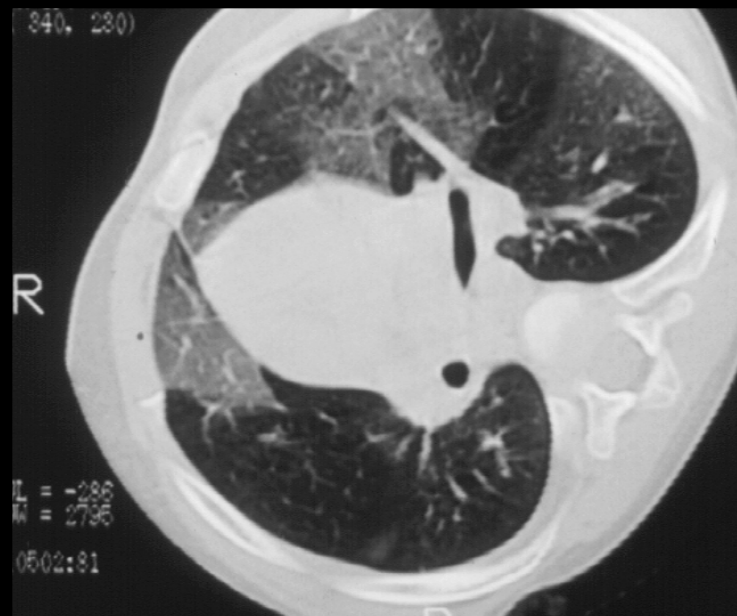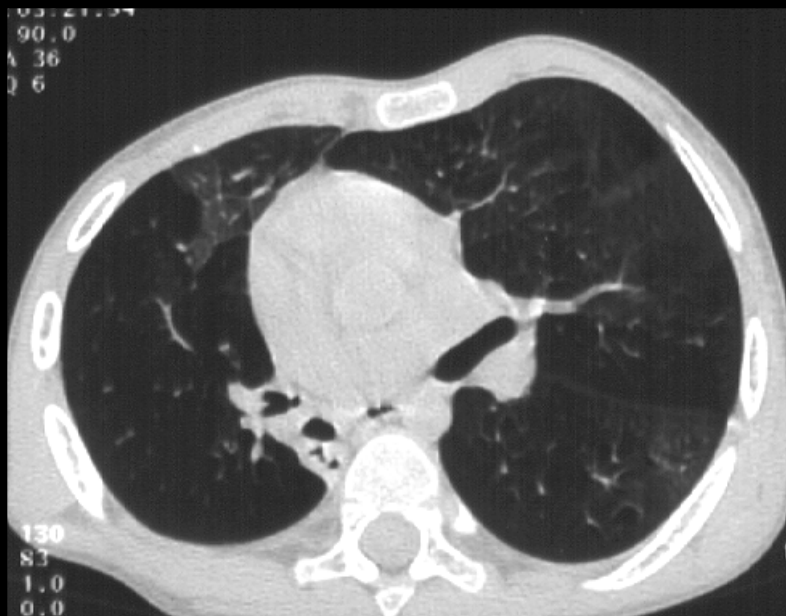
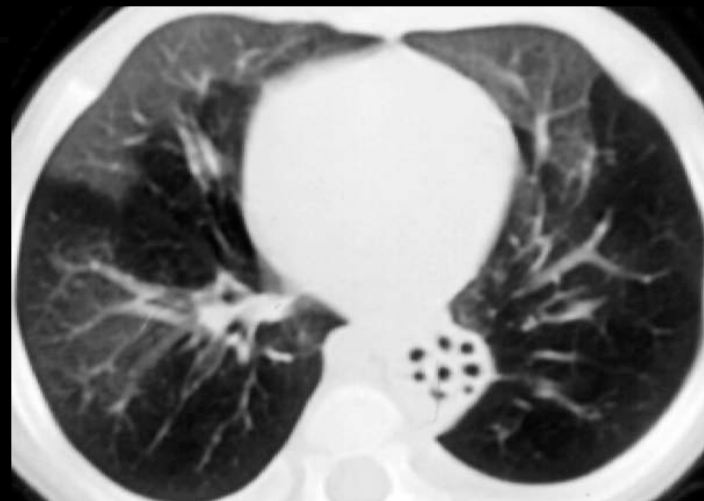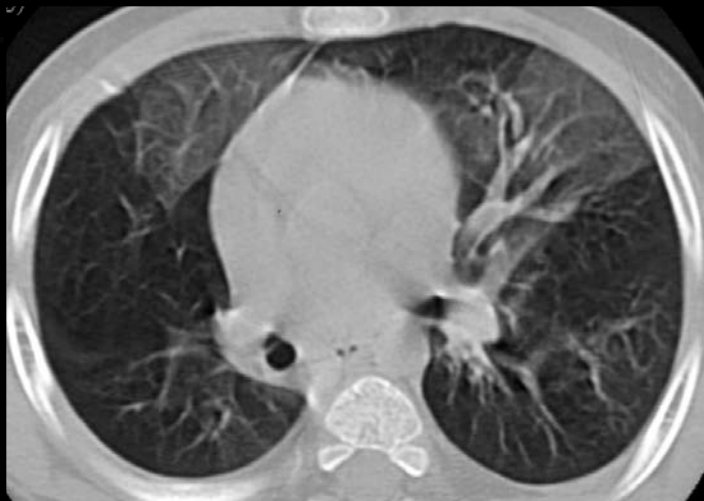## Two key points!

- **Low mAs and kVp (age / weight based)**
- **mAs reduced by 50% during expiratory phase CT imaging**

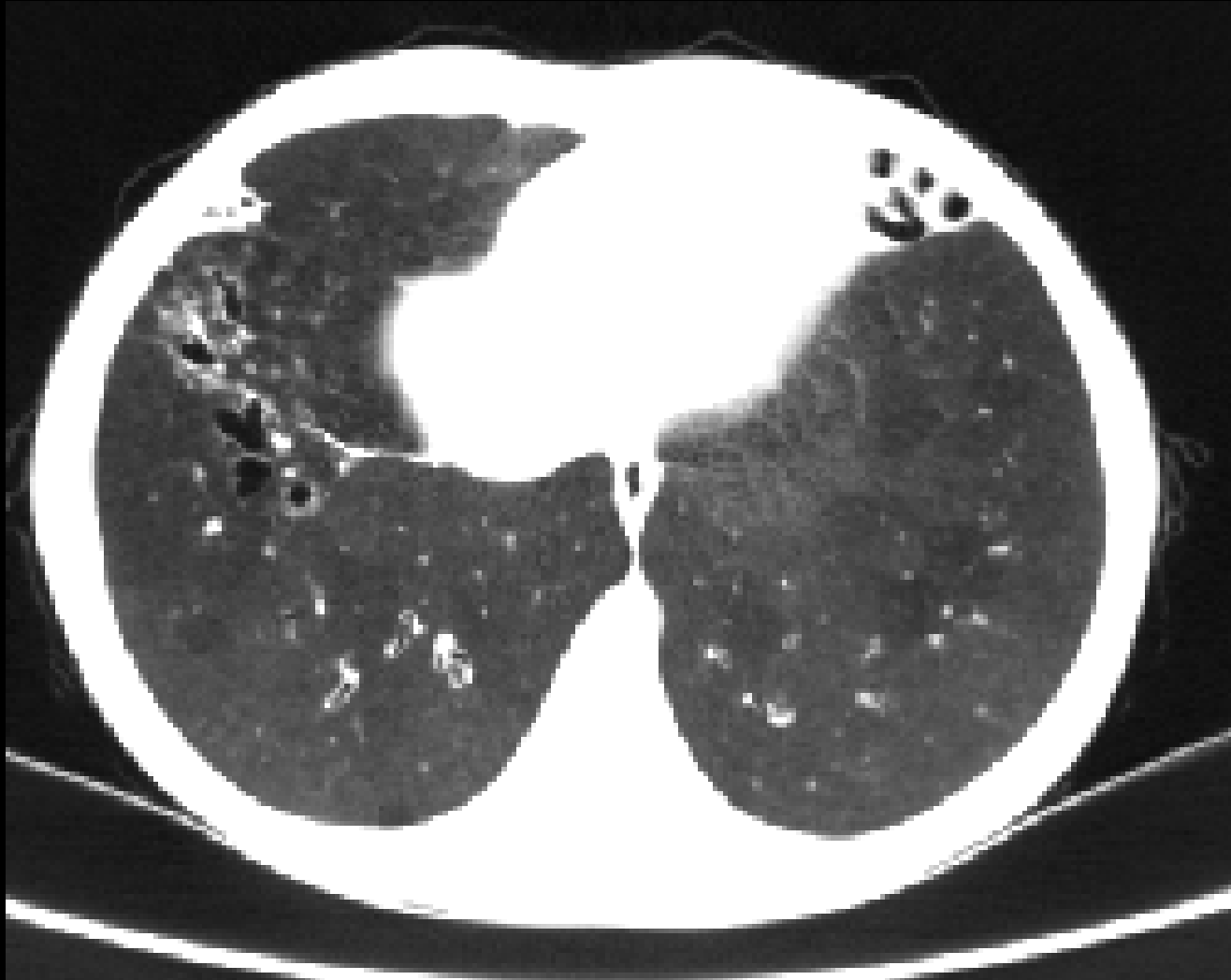Weight (kg)	Tube Current at Inspiration/Expiration (mAs)	Kilovoltage (kVp)
<10	40/20	80
10–14	50/25	80
15–24	60/30	80
25–34	70/35	80
35–44	80/40	80
45–54	90/40	90
55–70	100–120/40	100–120

Lee EY, Boiselle PM. Tracheobronchomalacia in infants and children: MDCT evaluation. *Radiology*, 2009

# Atrapamiento Aereo

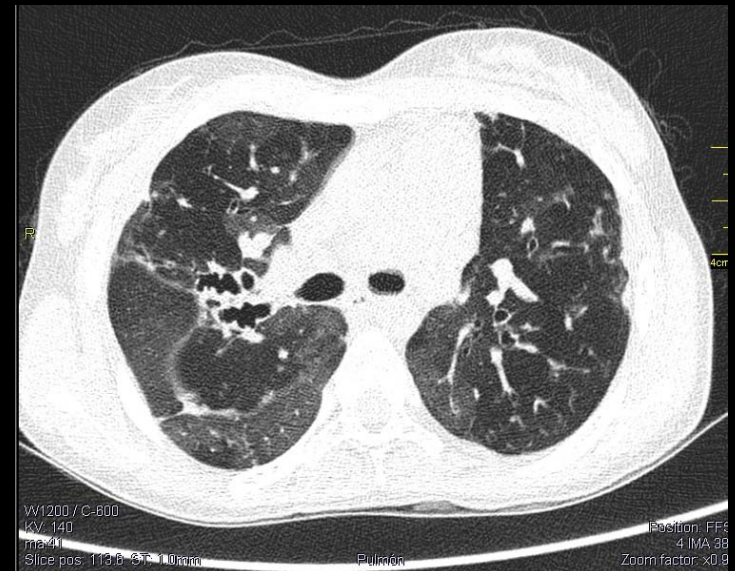
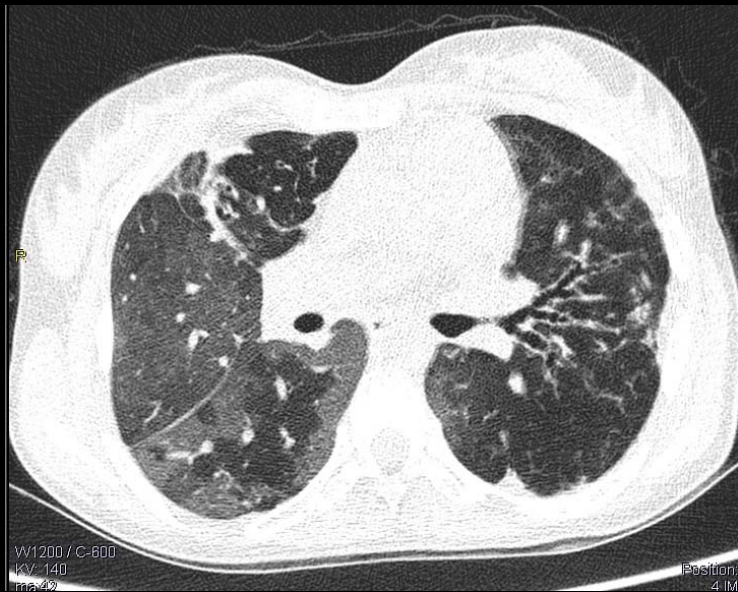
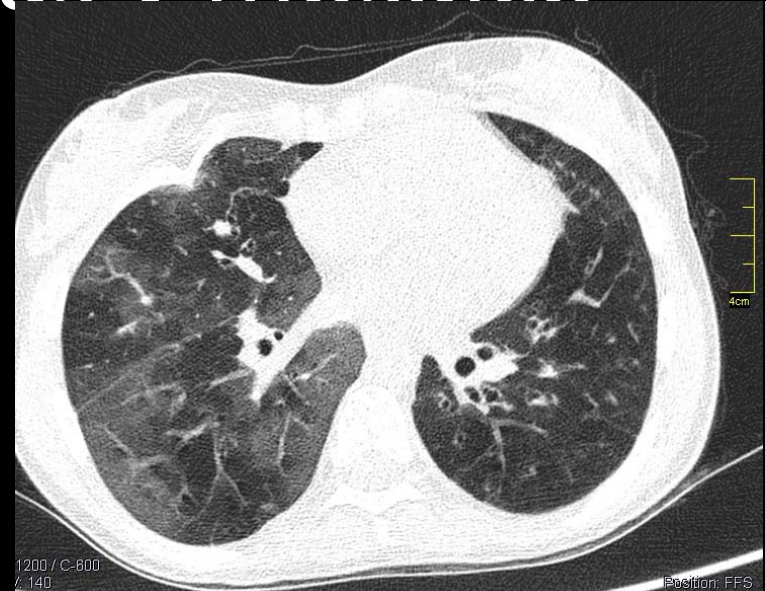
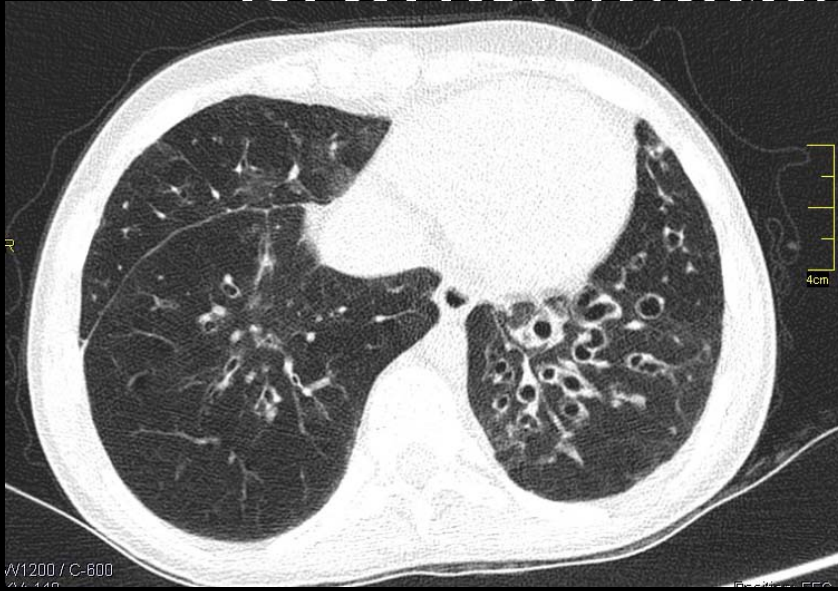


# Minip





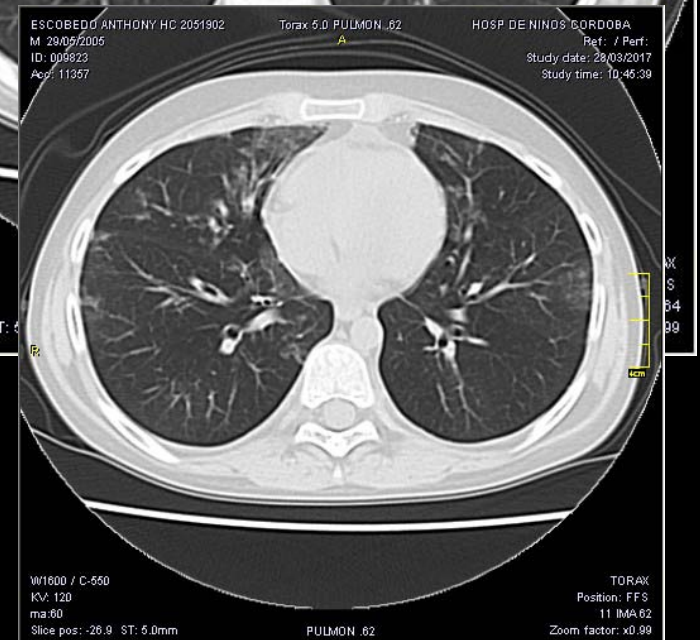
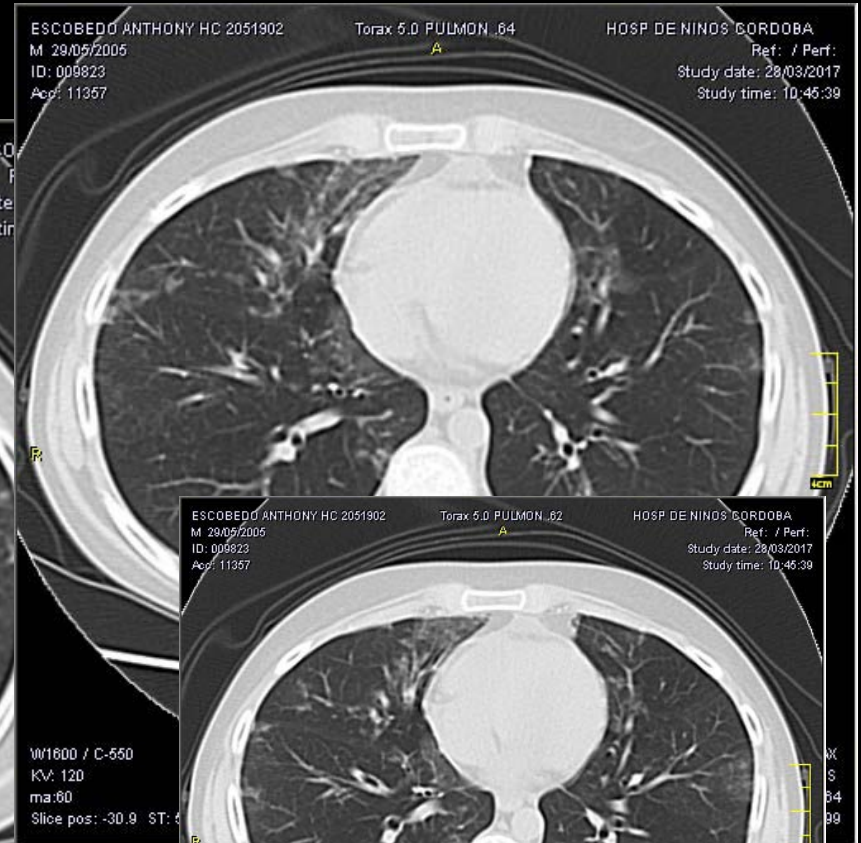
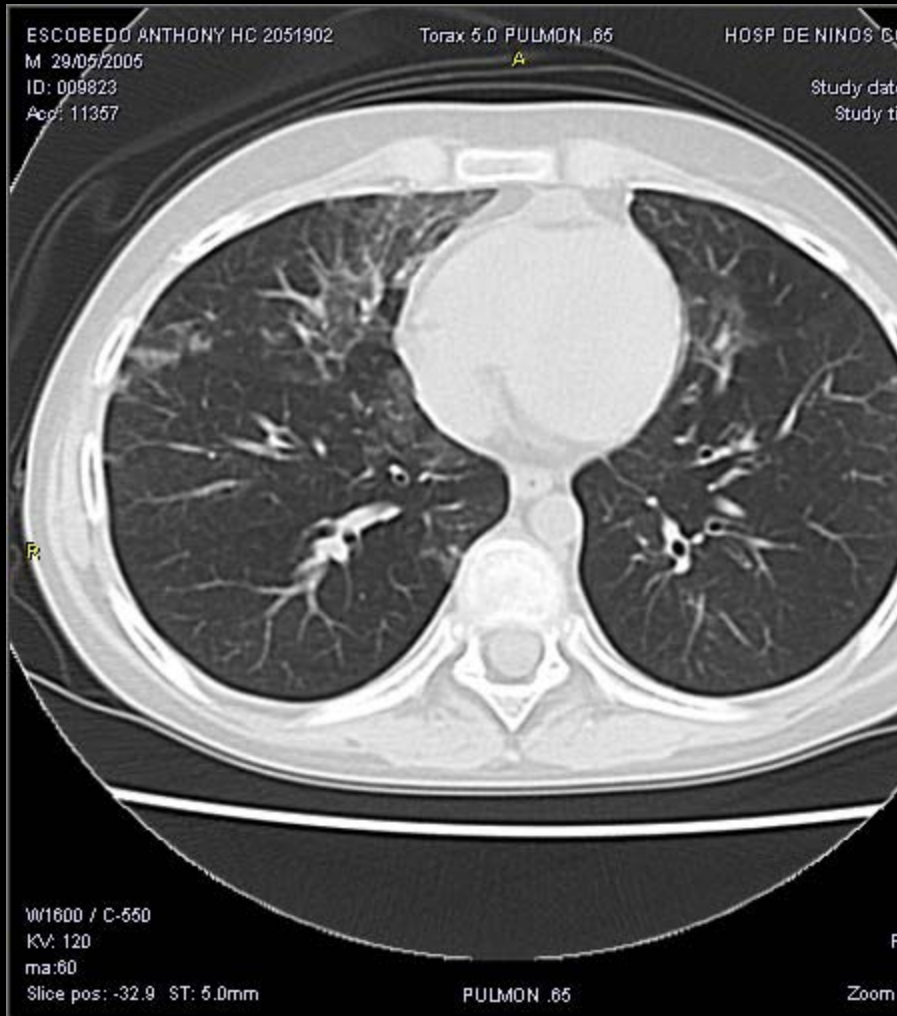
# Bronquiectasias y mosaico



# Sutiles

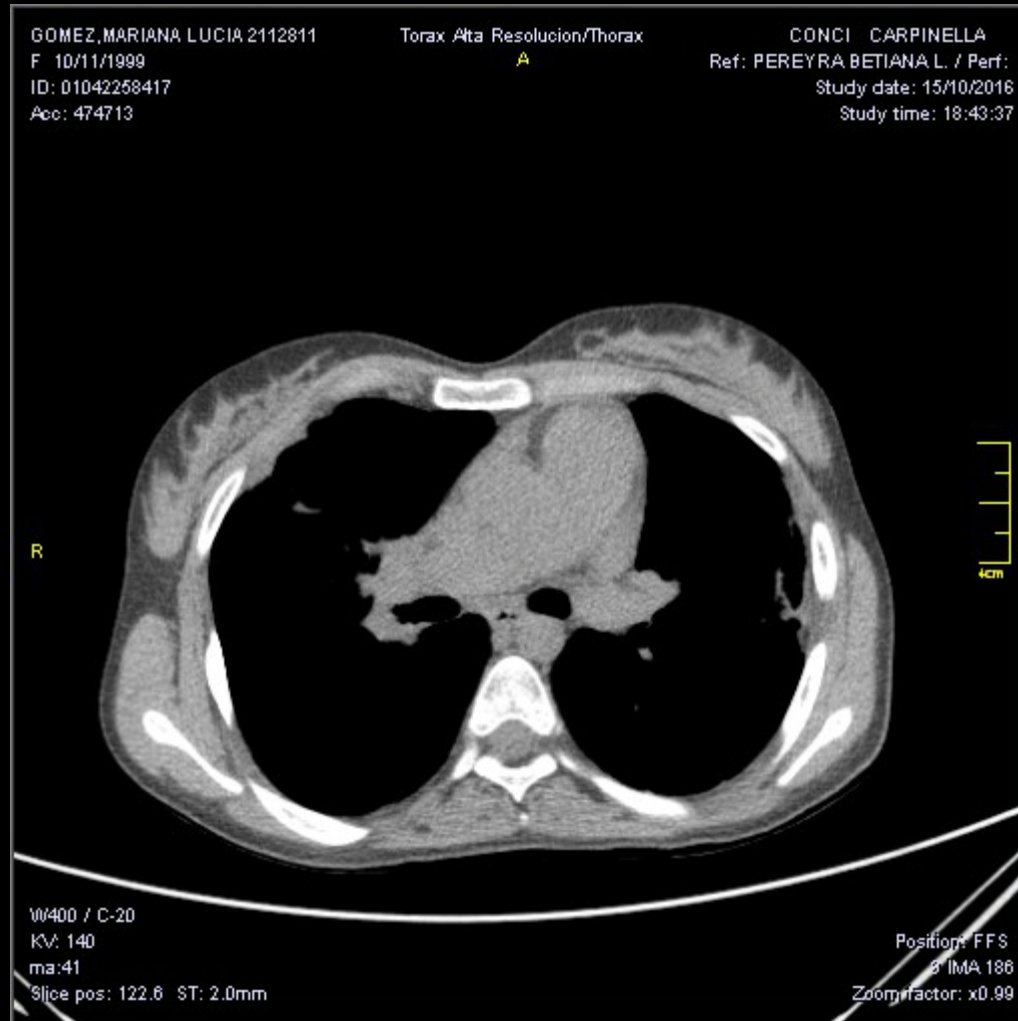


# Sutiles otro bronquio muy periferico y arbol en brote





# HTAPulmonar





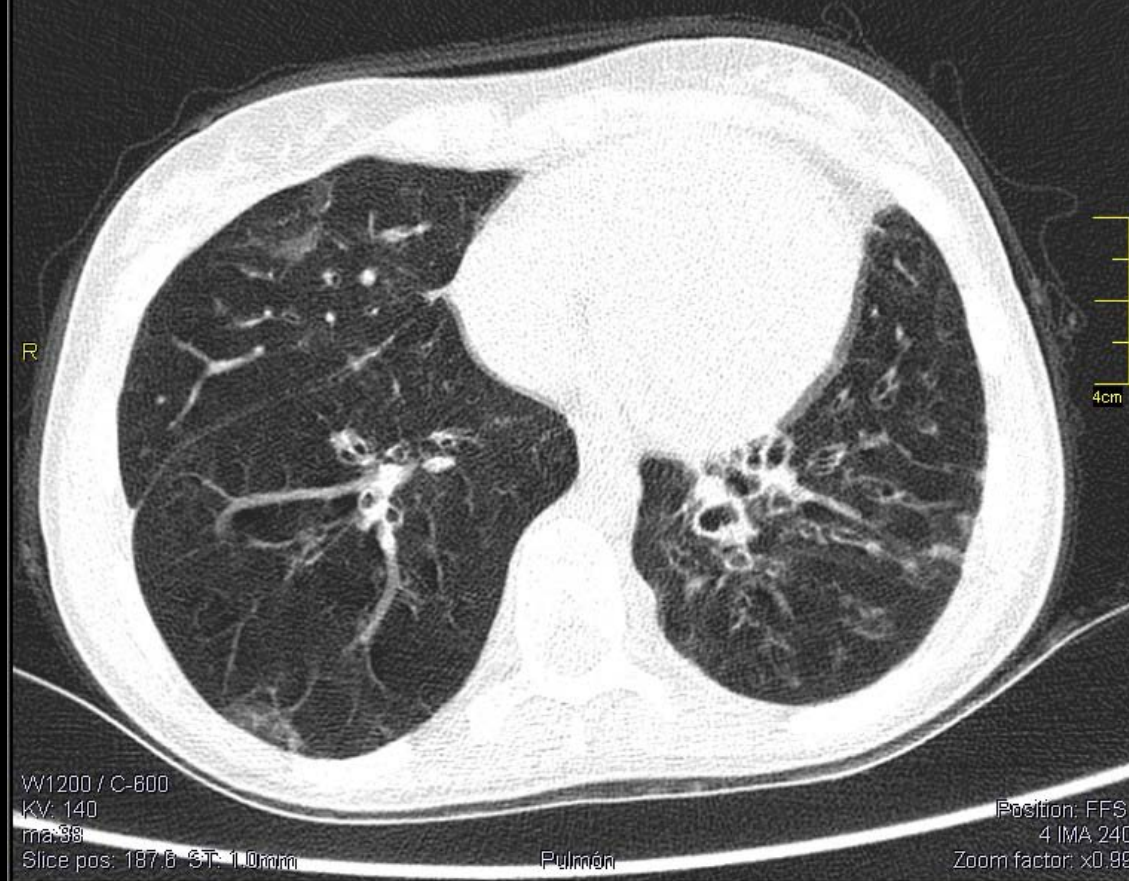
# Lobulillo pulmonar

GOMEZ, MARIANA LUCIA 2112811

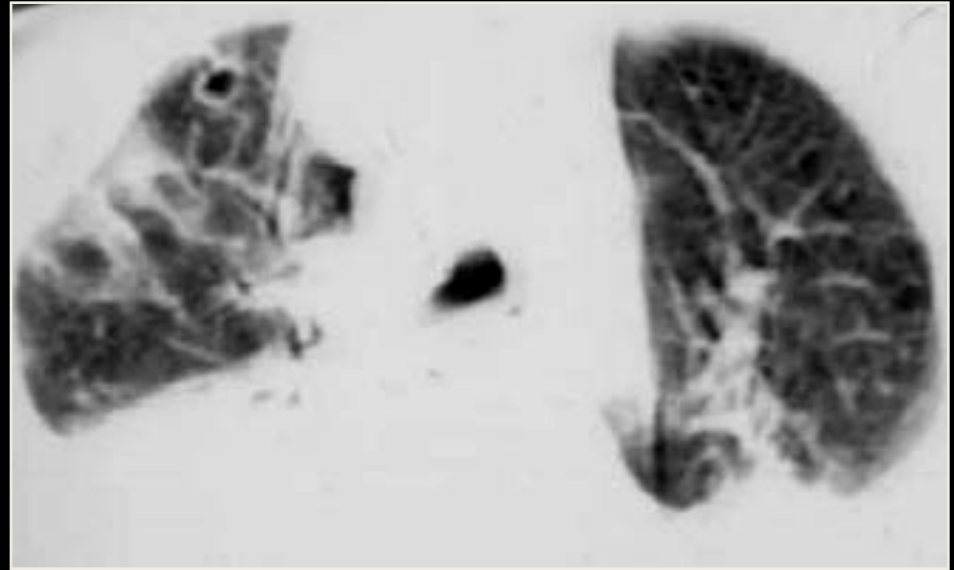
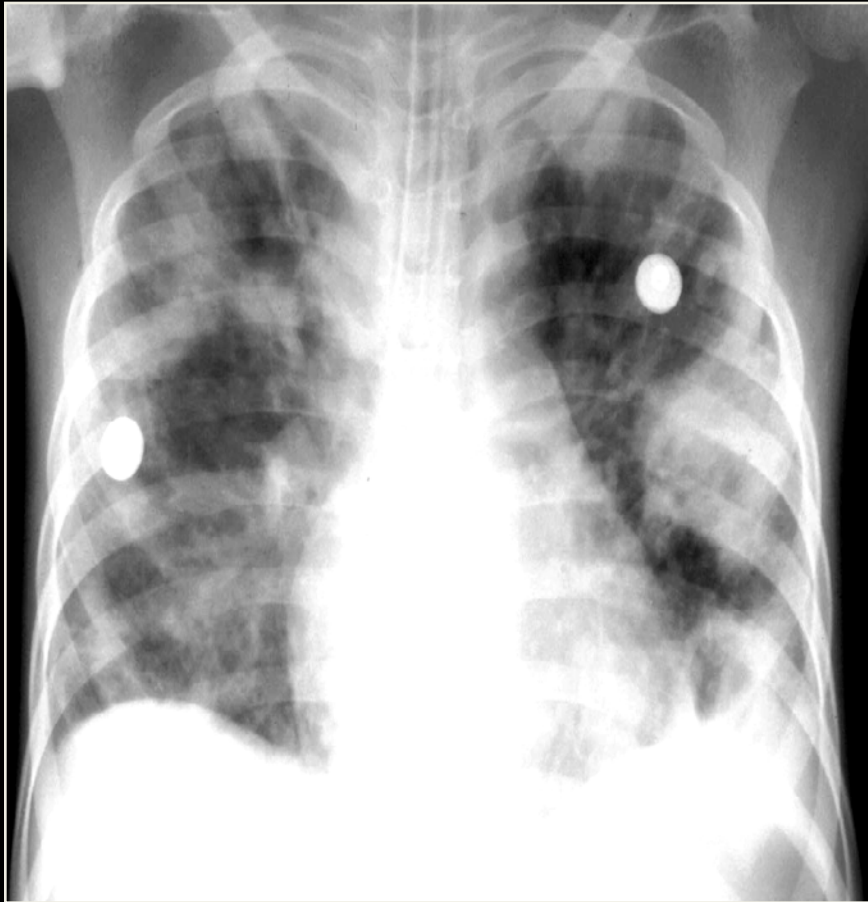
F: 10/11/1999  
ID: 01042258417  
Acc: 474713

Pulmón  
A

CONCI, CARPINELLA  
Ref: PEREYRA, BETIANA L. / Perf:  
**Study date: 15/10/2016**  
Study time: 18:43:37



# Estafilococo:



# Minip

